

Actinic keratosis and squamous cell carcinoma of the skin

2.0 – December 2022

AWMF-Registernummer: 032-0220L

Guideline (Long version)



This is new!
This has changed!

Important Updates

[Chapter 5](#)

The therapy of actinic keratosis was updated and newly approved preparations were added. The balance sheet was further revised according to practically relevant aspects.

[Chapter 6](#)

Recommendations for the therapy of cheilitis actinica have been newly included. Ablative and drug-based procedures are presented and evidence-based recommendations are given. Therapeutic options are summarized in a balance sheet.

[Chapter 7](#)

For the first time, Bowen's disease is implemented in the guideline. An adaptation was made from the Cochrane Review from 2012 which was used as a basis and the literature search was updated. Evidence-based recommendations for the therapy of Bowen's disease are given.

[Chapter 8](#)

The recommendations for surgical therapy of squamous cell carcinoma were specified and schematized by an algorithm for surgical excision, choice of safety margins, recommendations for histological control of excision margins, recommendations for post-excision, each taking into account specific risk factors.

Recommendations for adjuvant and postoperative radiotherapy were presented separately.

The recommendations on system therapy were updated, addressing changes since the approval of cemiplimab in August 2019 and alternatives after progression and in case of contraindications.

A section on palliative care was added.

[Chapter 9](#)

The recommendations on follow-up of squamous cell carcinoma were revised in table form, and the recommendations on lymph node sonography were reduced to 6-12-month intervals. Furthermore, it was added that even in cases of low risk of recurrence, follow-up care cannot be dispensed with, but should also be carried out for early detection of secondary squamous cell carcinoma of the skin.

Table of Contents

Important Updates	2
1 Information about this Guideline	8
1.1 Editors	8
1.2 Leading Scientific Societies	8
1.3 Funding of the Guideline	8
1.4 Contact	8
1.5 How to cite.....	8
1.6 Special Comment	9
1.7 Objectives of the German Guideline Program in Oncology	9
1.8 Additional Documents relating to this Guideline	10
1.9 Composition of the Guideline Group.....	11
1.9.1 Guideline Coordination	11
1.9.2 Involved Professional Societies and Organisations	11
1.9.3 Workgroups	14
1.9.4 Patient Involvement	15
1.9.5 Methodological Support	15
1.10 Abbreviations Used	16
2 Introduction	19
2.1 Scope and Purpose	19
2.1.1 Objective and Key Questions	19
2.1.2 Target Audience	20
2.1.3 Validity and Update Process	21
2.2 Methodology	21
2.2.1 Levels of Evidence (LoE)	21
2.2.2 Grades of Recommendation (GoR)	23
2.2.3 Statements	24
2.2.4 Expert Consensus (EC)	24
2.2.5 Independence and Disclosure of Possible Conflicts of Interest	24

3	Epidemiology and etiology	25
3.1	Epidemiology of actinic keratosis.....	25
3.2	Epidemiology of invasive squamous cell carcinoma.....	25
3.2.1	Incidence.....	25
3.2.2	Mortality.....	30
3.2.3	Etiology and pathogenesis	30
3.2.4	Risk factor immunosuppression	31
3.3	Prognostic factors for the transition from actinic keratosis to invasive squamous cell carcinoma	32
3.4	Prognostic factors for metastasis in invasive squamous cell carcinoma.....	34
4	Diagnostics	36
4.1	Classification, definition and nomenclature of actinic keratosis	36
4.2	Classification, definition and nomenclature of cheilitis actinica	38
4.3	Classification, definition and nomenclature of squamous cell carcinoma in situ (Bowen's disease)	39
4.4	Classification, definition and nomenclature of invasive squamous cell carcinoma	39
4.4.1	Definition and nomenclature	39
4.4.2	Classification and staging	40
4.5	Field cancerization	46
4.6	Importance of non-invasive diagnostic procedures	48
4.7	When and how to obtain a histology specimen.....	49
4.8	Parameters of a histological report	51
4.9	Diagnosis of spread in invasive squamous cell carcinoma	53
4.9.1	Lymph node sonography.....	53
4.9.2	Chest X-ray	54
4.9.3	Abdominal sonography.....	54
4.9.4	Cross-sectional imaging	55
5	Therapy of actinic keratosis.....	57
5.1	Literature search and study selection.....	57
5.2	Treatment indication and natural course of the disease.....	58
5.3	Therapy basics	59

5.4	Combination therapies	62
5.5	Ablative and physical procedures.....	64
5.5.1	Cryosurgery.....	64
5.5.2	Surgical procedures	69
5.5.3	Chemoexfoliation	70
5.5.4	Dermabrasion.....	71
5.5.5	Potassium hydroxide	72
5.5.6	Laser therapy.....	74
5.6	Topical drug-based procedures.....	78
5.6.1	Diclofenac	78
5.6.2	5-fluorouracil	85
5.6.3	5-fluorouracil with salicylic acid.....	96
5.6.4	Ingenol mebutate.....	100
5.6.5	Imiquimod.....	101
5.6.6	Tirbanibulin.....	110
5.7	Photodynamic therapy.....	112
5.7.1	Photodynamic therapy with methyl aminolevulinate.....	112
5.7.2	Photodynamic therapy with 5-aminolevulinate	117
5.7.3	Photodynamic therapy with daylight.....	129
5.8	Therapy in immunosuppression and organ transplantation	132
5.8.1	Photodynamic therapy	133
5.8.2	Imiquimod.....	135
5.8.3	Diclofenac	136
5.9	Other interventions	137
5.9.1	Birch cork	139
5.9.2	Colchicine.....	140
5.9.3	Canola phenolic acid.....	140
5.9.4	Difluoromethyl ornithine.....	140
5.9.5	Glucans	141
5.9.6	Nicotinamide	141
5.9.7	Ingenol disoxate	142
5.9.8	DNA repair enzymes	142
5.9.9	SR-T100 gel	143
5.9.10	Resiquimod	143
5.9.11	Sunscreen.....	144
5.9.12	Retinoids	145
5.10	Summary and balancing presentation of approved therapy options	149

6	Therapy of cheilitis actinica	157
6.1	Literature search and study selection	157
6.2	Indication and natural history of the disease	157
6.3	Therapy basics	158
6.4	Ablative procedures	159
6.4.1	Surgical procedures	159
6.4.2	Laser therapy	160
6.4.3	Cryosurgery	162
6.4.4	Chemoexfoliation	162
6.5	Topical drug-based procedures	162
6.5.1	Diclofenac	163
6.5.2	5-fluorouracil	164
6.5.3	Imiquimod	164
6.5.4	Photodynamic therapy	165
6.6	Combination therapies	166
6.7	Summary and balancing presentation of approved therapy options (balance sheet)	168
7	Therapy of squamous cell carcinoma in situ (Bowen's disease).....	171
7.1	Literature search and study selection	171
7.2	Clinical characterization and natural course of the disease	171
7.3	Treatment indication and therapy modalities	172
7.4	Surgical procedures	173
7.5	Destructive methods	174
7.5.1	Cryosurgery	174
7.5.2	Ablative laser procedures	178
7.6	Topical drug-based procedures	179
7.6.1	5-fluorouracil	179
7.6.2	Imiquimod	182
7.7	Photodynamic therapy	183
7.7.1	ALA-PDT	184
7.7.2	MAL-PDT	186
8	Therapy of invasive squamous cell carcinoma of the skin	190

8.1	Surgical therapy of the primary tumor	190
8.1.1	Risk factors for loco-regional progression and tumor-specific survival	191
8.1.2	Surgical therapy and histological incision margin control.....	195
8.2	Operative procedure after R0 resection	200
8.2.1	Safety resection after R0 resection	200
8.2.2	Wound closure after confirmation of R0 resection.....	201
8.3	Sentinel lymph node biopsy.....	201
8.4	Prophylactic and therapeutic lymphadenectomy.....	203
8.5	Lymphadenectomy in the head and neck region.....	205
8.6	Radiotherapy and postoperative radiotherapy	206
8.7	Therapy of local or locoregional recurrence	211
8.8	Therapy in the advanced (locally advanced or metastasized) stage	212
8.8.1	Indication for systemic therapy	212
8.8.2	Implementation of systemic therapy.....	213
8.9	Palliative care	219
9	Follow-up and prevention	220
9.1	Examinations within the framework of aftercare.....	220
9.1.1	Examination intervals for early detection of metastasis.....	220
9.1.2	Risk-adapted intervals according to stages	221
9.1.3	Explanation of the recommendation	222
9.1.4	Examination intervals for the early detection of secondary squamous cell carcinoma of the skin.....	223
9.1.5	Investigational methods in the follow-up of invasive squamous cell carcinoma	224
9.1.6	In which patients can follow-up examinations be waived?.....	228
9.2	Measures for the primary prevention of actinic keratosis and squamous cell carcinoma of the skin.....	229
9.3	Preventive measures for special risk groups.....	229
10	Occupational disease of squamous cell carcinoma of the skin or/and actinic keratosis	230
10.1	Diagnosis and reporting of suspected occupation-related skin cancer.....	230
10.1.1	Skin cancer caused by natural UV radiation (BK No. 5103 BKV).....	230
10.1.2	Diseases caused by arsenic or its compounds (BK No. 1108 BKV).....	232

10.1.3	Diseases caused by ionizing radiation (BK No. 2402 BKV)	232
10.1.4	Skin cancer or skin changes tending to cancer formation due to soot, crude kerosene, tar, anthracene, pitch or similar substances (BK No. 5102 BKV)	233
10.1.5	Summary	234
10.2	Occupational skin cancer prevention.....	234
10.3	Follow-up care for BK No. 5103 BKV.....	234
10.4	Occupational health care for outdoor activities with intensive exposure to natural UV radiation	235
11	Care structures for actinic keratosis and squamous cell carcinoma .	236
11.1	Skin Tumor Centers.....	236
11.2	Quality indicators	236
12	Attachments	238
12.1	Changes in Version 2.01	238
13	List of Tables.....	251
14	List of Figures.....	253
15	Literature References	254

1 Information about this Guideline

1.1 Editors

The German Guideline Program in Oncology (GGPO) organized by the Association of the Scientific Medical Societies in Germany (AMWF), the German Cancer Society (DKG), and the German Cancer Aid Foundation (DKH).

1.2 Leading Scientific Societies



Deutsche Dermatologische Gesellschaft
e.V. (DDG)

Arbeitsgemeinschaft Dermatologische
Onkologie (ADO) der Deutschen
Dermatologischen Gesellschaft (DDG)
und der Deutschen Krebsgesellschaft
(DKG)

1.3 Funding of the Guideline

This guideline was sponsored by the German Cancer Aid Foundation (DKH) within the framework of the German Guideline Program in Oncology.

1.4 Contact

Office Leitlinienprogramm Onkologie
c/o Deutsche Krebsgesellschaft e. V.
Kuno-Fischer-Str. 8
14057 Berlin

leitlinienprogramm@krebsgesellschaft.de
www.leitlinienprogramm-onkologie.de

1.5 How to cite

German Guideline Program in Oncology (German Cancer Society, German Cancer Aid, AMWF): Actinic keratosis and squamous cell carcinoma of the skin, Long version 2.0, 2022, AWMF Registration Number: 032-022OL <https://www.leitlinienprogramm-onkologie.de/leitlinien/aktinische-keratosen-und-plattenepithelkarzinom-der-haut/>; Accessed [tt.mm.jjj]

1.6 Special Comment

The field of medicine is subject to a continuous process of further development, so that all details provided here, and in particular those on diagnostic and therapeutic procedures, can always only represent the state of knowledge at the time when the medical care guideline was printed. The greatest possible care has been taken with regard to the treatment recommendations given and to the choice and dosage of drugs. However, users are requested to check by referring to the patient package inserts and specialist information provided by the manufacturers, and in cases of doubt to consult a specialist. In the general interest of the guideline editors, readers are requested to draw attention to any questionable points or inconsistencies found.

Users themselves remain responsible for all diagnostic and therapeutic applications, medications, and dosages.

Registered trademarks (protected proprietary names) are not specially identified in this guideline. The absence of an indication of this type can therefore not be taken to suggest that such names are unregistered product names.

All parts of this guideline are protected by copyright. Any usage outside of the provisions of copyright law without written permission from the German Guideline Program in Oncology editors is therefore unlawful and liable to prosecution. No part of this work may be reproduced in any form without written permission from the German Guideline Program in Oncology editors. This applies in particular to reproduction, translation, microfilming and storage, usage and exploitation in electronic systems, intranets and the Internet.

1.7 Objectives of the German Guideline Program in Oncology

The aim of the Association of the Scientific Medical Societies in Germany (AWMF), the German Cancer Society (DKG), and the German Cancer Aid Foundation (DKH) in implementing the German Guideline Program in Oncology (GGPO) is to jointly promote and support the development, updating, and use of scientifically based and practicable guidelines in oncology. The program is based on medical and scientific findings established by the specialist societies and the DKG, consensus among medical experts, users and patients, as well as the AWMF's regulations for guideline development. The program receives specialist support and financing from the German Cancer Aid. In order to reflect the current state of medical knowledge and to take account of medical progress, guidelines have to be regularly checked and updated. The use of the AWMF regulations is intended to provide a basis for developing of high-quality oncological guidelines in this framework. As guidelines represent an important instrument for quality assurance and quality management in oncology, they are intended to be used in a targeted and sustained way in everyday medical care. Active implementation measures and also evaluation programs are therefore important components of the support provided by the German Guideline Program in Oncology. The aim of the program is to create professional preconditions, with secure medium-term financing, for the development and provision of high-

quality guidelines in Germany. High-quality guidelines of this type not only serve for structured knowledge transfer but can also be used in the design of health-care structures. Relevant aspects of this include evidence-based guidelines as a basis for establishing and updating disease management programs, and the use of quality indicators derived from guidelines in the context of certification procedures for organ tumor centers.

1.8 Additional Documents relating to this Guideline

In addition to this long version of the S3 guideline on actinic keratosis and squamous cell carcinoma of the skin, the following supplementary documents to this guideline are available:

- Short version of the guideline
- Patient guideline
- Guideline report on the guideline development process

This guideline and all of the supplementary documents are available from the following web sites:

- German Guideline Program in Oncology (<https://www.leitlinienprogramm-onkologie.de/leitlinien/aktinische-keratosen-und-plattenepithelkarzinom-der-haut/>)
- AWMF (<https://www.awmf.org/leitlinien/detail/II/032-022OL.html>)
- Homepages of the participating professional societies (www.derma.de; [ADO homepage](#))
- Guidelines International Network (www.g-i-n.net)

The guideline is also included in the English version of the German Guideline Program in Oncology app.

For more information, visit: <https://www.leitlinienprogramm-onkologie.de/app/>

1.9 Composition of the Guideline Group

1.9.1 Guideline Coordination

Prof. Dr. Carola Berking, Hautklinik, Uniklinikum Erlangen, Friedrich-Alexander-Universität Erlangen-Nürnberg (FAU), Erlangen, Germany

Prof. Dr. Ulrike Leiter, Zentrum für Dermatookologie, Universitäts-Hautklinik, Eberhard-Karls-Universität Tübingen, Tübingen, Germany

PD Dr. Markus Heppt, Hautklinik, Uniklinikum Erlangen, Friedrich-Alexander-Universität Erlangen-Nürnberg (FAU), Erlangen, Germany

Prof. Dr. Claus Garbe, Zentrum für Dermatookologie, Universitäts-Hautklinik, Eberhard-Karls-Universität Tübingen, Tübingen, Germany

Editorial Assistance

Sarah Glandien (ADO/DeCOG Dermatologic Cooperative Oncology Group, Berlin)

1.9.2 Involved Professional Societies and Organisations

Table 1 lists all of the involved professional societies and further organizations, as well as their mandated representatives.

Table 1: Participating professional associations and organizations (alphabetical)

Participating professional associations and organizations (alphabetical)	Representative(s)
Arbeitsgemeinschaft Dermatologische Histologie (ADH)	Prof. Dr. Michael Flaig
Arbeitsgemeinschaft Dermatologische Onkologie der DKG und DDG (ADO)	Prof. Dr. Stephan Grabbe Prof. Dr. Ralf Gutzmer Prof. Dr. Axel Hauschild
Arbeitsgemeinschaft Dermatologische Prävention (ADP) e.V.	Henriette Bunde Elisa Großmann Yvonne de Buhr
Arbeitsgemeinschaft Gesundheitsökonomie und Evidenz-basierte Medizin der DDG (AGED)	Prof. Dr. Matthias Augustin
Arbeitsgemeinschaft Palliativmedizin in der DKG (APM)	Prof. Dr. Carmen Loquai
Arbeitsgemeinschaft Radiologische Onkologie (ARO)	Prof. Dr. Oliver Kölbl Prof. Dr. Dirk Vordermark
Arbeitsgemeinschaft Tumorklassifikation in der Onkologie der DKG (ATO)	Prof. Dr. Michael Weichenthal

Participating professional associations and organizations (alphabetical)	Representative(s)
Arbeitsgemeinschaft für Berufs- und Umweltdermatologie (ABD)	Prof. Dr. Andrea Bauer Prof. Dr. Swen Malte John
Arbeitsgemeinschaft physikalische Diagnostik in der Dermatologie in der DDG	PD Dr. Lutz Schmitz Prof. Dr. Julia Welzel
Berufsverband Deutscher Dermatologen (BVDD)	Prof. Dr. Klaus Fritz
Beteiligte Fachexperten (ohne Stimmrecht)	Dr. Mareike Alter Prof. Dr. Jürgen Becker Prof. Dr. Eckhard W. Breitbart Prof. Dr. Thomas Dirschka Prof. Dr. Thomas Eigentler Dr. Michael Fluck Dr. Klaus Kraywinkel Dr. Christoph Löser Prof. Dr. Carmen Salavastru Prof. Dr. Heinz Schmidberger Dr. Claas Ulrich
Bundesverband Deutscher Pathologen e.V. (BDP)	Prof. Dr. Stephan Ihrler
Deutsche Dermatologische Gesellschaft e.V. (DDG)	Prof. Dr. Eggert Stockfleth Prof. Dr. Rolf-Markus Szeimies Prof. Dr. Julia Welzel
Deutsche Gesellschaft der Plastischen, Rekonstruktiven und Ästhetischen Chirurgen (DGPRÄC)	Dr. Albrecht Krause-Bergmann
Deutsche Gesellschaft für Arbeitsmedizin und Umweltmedizin (DGAUM)	Prof. Dr. Hans Drexler Prof. Dr. Susanne Völter-Mahlknecht
Deutsche Gesellschaft für Chirurgie (DGCH)	Dr. Albrecht Krause-Bergmann
Deutsche Gesellschaft für Dermatochirurgie e.V. (DGDC)	Prof. Dr. Moritz Felcht
Deutsche Gesellschaft für Hals-Nasen-Ohren-Heilkunde, Kopf- und Hals-Chirurgie e.V. (DGHNOKHC)	Prof. Dr. Susanne Wiegand
Deutsche Gesellschaft für Mund-, Kiefer- und Gesichtschirurgie (DGMKG)	PD Dr. Dr. Kai Wermker

Participating professional associations and organizations (alphabetical)	Representative(s)
Deutsche Gesellschaft für Palliativmedizin e.V. (DGP)	Prof. Dr. Dorothee Nashan
Deutsche Gesellschaft für Pathologie e.V. (DGP)	Prof. Dr. Stephan Ihrler
Deutsche Gesellschaft für Radioonkologie e.V. (DEGRO)	Prof. Dr. Oliver Kölbl Prof. Dr. Dirk Vordermark
Deutsche Gesellschaft für Ultraschall in der Medizin e.V. (DEGUM)	Prof. Dr. Stephan El Gammal
Deutsche Röntgengesellschaft e.V. (DRG)	Prof. Dr. Christina Pfannenbergl
Deutsche gesetzliche Unfallversicherung (DGUV)	Dr. Michal Gina Steffen Krohn
Hautkrebsnetzwerk (Patientenvertretung)	Antje Backes Hans-Walther Bötcl Annegret Meyer Claudia Nink

The following professional societies and associations were contacted for the guideline process:

- Arbeitsgemeinschaft für Psychoonkologie der Deutschen Krebsgesellschaft (PSO)
- Arbeitsgemeinschaft Urologische Onkologie (AUO)
- Arbeitsgemeinschaft Hals-Nasen-Ohren-Heilkunde, Mund-Kiefer-Gesichtschirurgische Onkologie (AHMO)
- Arbeitsgemeinschaft Internistische Onkologie (AIO)
- Deutsche Gesellschaft für Allgemeinmedizin und Familienmedizin (DEGAM)
- Chirurgische Arbeitsgemeinschaft Onkologie (CAO)
- Deutsche Gesellschaft für Hämatologie und Medizinische Onkologie e.V. (DGHO)
- Arbeitsgemeinschaft Rehabilitation in der Dermatologie (AReD)

However, they either did not respond, did not name a representative, or declined to participate.

1.9.3 Workgroups

Table 2: Composition of Guideline Workgroups

Workgroup	Composition of Workgroup
Epidemiology and Etiology	Prof. Dr. Ulrike Leiter Prof. Dr. Jürgen Becker, Prof. Dr. Eckhard W. Breitbart, Prof. Dr. Thomas Eigentler, Prof. Dr. Claus Garbe, Dr. Rüdiger Greinert, Dr. Klaus Kraywinkel
Diagnostics	Prof. Dr. Michael Flaig Prof. Dr. Thomas Dirschka, PD Dr. Markus Heppt, Prof. Dr. med. Uwe Hillen, Prof. Dr. Stephan Ihrlert, Prof. Dr. Christina Pfannenbergl, PD Dr. Lutz Schmitz, Prof. Dr. Julia Welzel
Therapy of actinic keratosis	PD Dr. Markus Heppt Prof. Dr. Carola Berking, Prof. Dr. Thomas Diepgen (deceased), Prof. Dr. Klaus Fritz, Dr. Christoph Löser, Prof. Dr. Carmen Salavastru, PD Dr. Lutz Schmitz, Dr. Theresa Steeb, Prof. Dr. Eggert Stockfleth, Prof. Dr. Rolf-Markus Szeimies, Dr. Claas Ulrich
Therapy of cheilitis actinica	Prof. Dr. Rolf-Markus Szeimies Prof. Dr. Carola Berking, Prof. Dr. Thomas Dirschka, Prof. Dr. Axel Hauschild, Prof. Dr. Ulrike Leiter, PD Dr. Lutz Schmitz, PD Dr. Dr. Kai Wermker
Therapy of squamous cell carcinoma in situ (Morbus Bowen)	PD Dr. Lutz Schmitz Prof. Dr. Michael Flaig, PD Dr. Markus Heppt
Therapy of invasive squamous cell carcinoma: Surgery	Prof. Dr. Moritz Felcht Dr. Mareike Alter, Prof. Dr. Falk G. Bechara, Prof. Dr. Helmut Breuninger, Dr. Lukas Kofler, Dr. Albrecht Krause-Bergmann, Prof. Dr. Oliver Kölbl, Prof. Dr. Ulrike Leiter, PD Dr. Dr. Kai Wermker, Prof. Dr. Susanne Wiegand
Therapy of invasive squamous cell carcinoma: Conservative therapy	Prof. Dr. Ralf Gutzmer Prof. Dr. Jürgen Becker, Prof. Dr. Axel Hauschild, Prof. Dr. Oliver Kölbl, Prof. Dr. Ulrike Leiter, Prof. Dr. Dorothee Nashan, Prof. Dr. Dirk Vordermark

Workgroup	Composition of Workgroup
Therapy of invasive squamous cell carcinoma: System therapy and palliative medicine	Prof. Dr. Ralf Gutzmer Prof. Dr. Axel Hauschild, Prof. Dr. Ulrike Leiter, Prof. Dr. Dorothee Nashan
Prevention and aftercare	Prof. Dr. Ulrike Leiter Prof. Dr. Stephan El Gammal, Prof. Dr. Klaus Fritz, Prof. Dr. Axel Hauschild, Prof. Dr. Swen Malte John, Dr. Peter Mohr, Prof. Dr. Christina Pfannenber
Squamous cell carcinoma of the skin and/or actinic keratosis as occupational diseases	Prof. Dr. Andrea Bauer Prof. Dr. Eckhard W. Breitbart, Prof. Dr. Thomas Diepgen (deceased), Dr. Rüdiger Greinert, Prof. Dr. Swen Malte John, Steffen Krohn, Prof. Dr. Susanne Völter-Mahlknecht
Workgroup managers are marked in bold.	

1.9.4 Patient Involvement

Representatives of patient organizations (see Skin Cancer Network) were involved throughout the process of creating and updating this guideline.

1.9.5 Methodological Support

1. by the German Guideline Program in Oncology:

a. Markus Follmann, MD, MPH, MSc, Office of the German Guideline Program in Oncology - c/o German Cancer Society

b. Dipl. Soz.-Wiss. Thomas Langer, Office of the German Guideline Program in Oncology - c/o German Cancer Society

2. by the Association of the Scientific Medical Societies (AWMF)

a. Dr. Monika Nothacker, MPH, Association of the Scientific Medical Societies

1.10 Abbreviations Used

Table 3: Abbreviations Used

Abbreviation	Explanation
5-ALA	5-aminolevulinic acid
5-FU	5-Fluorouracil
AFXL	Ablative fractional laser
AIN	Anal intraepithelial neoplasia
AJCC	American Joint Committee on Cancer
AK	Actinic Keratosis
ArbMedVV	Ordinance on Preventive Occupational Health Care
ArbSchG	Act on the Implementation of Measures of Occupational Safety and Health to Encourage Improvements in the Safety and Health Protection of Workers at Work
BKV	Ordinance on occupational diseases
CI (eng)	Confidence Interval
HNSCC	head and neck squamous cell carcinoma
HPV	Human papilloma virus
HR	Hazard ratio
IGII	Investigator Global Improvement Index
ILDS	International League of Dermatological Societies
IMB	Ingenol mebutate
IPL	Intense pulsed light
KIN	Keratinocytic intraepidermal neoplasia
LED	Light-emitting diode
LN	Lymph nodes
MAL	Methyl aminolevulinate
MRI (eng)	magnetic resonance imaging

Abbreviation	Explanation
mSv	milliSievert
NCCN	National Comprehensive Cancer Network
NMSC	Non-Melanocytic Skin Cancer
OD	Occupational disease
pAIN	Perianal intraepithelial neoplasia
PDT	Photodynamic therapy
PET	Positron emission tomography
PGII	Patient Global Improvement Index
PIN	Penile intraepithelial neoplasia
PUVA	Psoralen plus UV-A
RCM	Reflectance confocal microscopy
RCT	Randomized Controlled Trial
ROS	Reactive Oxygen Species
SA	Salicylic acid
SCC	Squamous cell carcinoma or spinocellular carcinoma
SED	Standard erythema dose
SUV	Standardized uptake value
Syn.	Synonym
TCA	Trichloroacetic acid
TLNS	Target lesion number score
TLR	Toll-like receptor
UICC	Union Internationale Contre le Cancer (eng.: Union for International Cancer Control)
UV	Ultraviolet
VAKCC	Veteran Affairs Keratinocyte Carcinoma Chemoprevention Trial

Abbreviation	Explanation
VAS	Visual analogue scale
VIN	Vulvar intraepithelial neoplasia
vs.	versus
WHO	World Health Organization (Welt-Gesundheitsorganisation)
EC	Expert Consensus

2 Introduction

2.1 Scope and Purpose

2.1.1 Objective and Key Questions

Squamous cell carcinoma of the skin (SCC) is the most common malignant skin tumor after basal cell carcinoma and is rising at an incidence rate of 80-100 per 100,000 population; in 1970-2012, age-standardized incidence rates (European age standard) increased 10-fold. Several times more common are actinic keratoses (AK), the precursors of SCC. An update and upgrade of the two existing German guidelines on AK and SCC are considered urgent for the following reasons:

- Increase in incidence and overall very high prevalence with many millions of people affected with AK nationwide in Germany
- Availability of new scientific evidence (e.g., newly published results of clinical trials with several new therapy approvals)
- Need for a systematic review of clinical studies regarding efficacy, side effects, and sustainability of a variety of therapeutic methods used in practice with classification according to the rules of evidence-based medicine
- Inclusion of topics that have not been considered so far:
 - Non-invasive diagnostics (e.g., optical coherence tomography (OCT), confocal laser scanning microscopy (CLSM)).
 - UV-induced skin cancer as occupational disease (recognition of BK No. 5103 since 01.01.2015)
- Standardization of the classification

The aim of this S3 guideline on AK and SCC of the skin is to provide dermatologically and oncologically active physicians in practice and clinic with an accepted, evidence-based decision-making aid for the selection as well as implementation of appropriate measures for the diagnosis, therapy, and follow-up of these forms of fair skin cancer. The systematic presentation of study results regarding benefits and risks is intended to support physicians as well as patients in their decision making. The guideline is intended to set quality standards and thus improve the care of skin cancer patients in the long term.

In doing so, the guideline comments on the following questions:

Epidemiology and etiology

- Which prognostic factors are important in AK for the transition to SCC?
- Which prognostic factors are important for metastasis in SCC?

Diagnostics

- Which classification, definition, and nomenclature should be used to grade SCC? (clinical and histological)

- Which classification, definition, and nomenclature should be applied for the staging of AK? (clinical and histological)
- What is the definition of field cancerization (definition of terminology)?
- Which non-invasive diagnostic procedures are appropriate to diagnose AK and SCC?
- When, for which criteria, and how should histology be obtained?
- Which parameters should be components of the histological report of findings in AK and SCC?
- Which diagnostic of spread is indicated in patients with SCC at which stage?

Therapy of actinic keratosis

- Which forms of therapy are appropriate for the treatment of AK according to severity and clinical context?
- For which patients are which preventive therapies appropriate?

Therapy of squamous cell carcinoma

- What is the recommended therapy for the primary tumor?
- Is removal of the sentinel lymph node indicated? (In which cases?)
- For which patients is which lymph node dissection recommended?
- For which patients is adjuvant radiotherapy or postoperative radiotherapy (R1;R2) recommended?
- Which therapy is recommended for local or loco-regional recurrence?
- Which therapy is recommended for patients with distant metastatic stage (first- and second-line)?

Prevention and aftercare

- Which examinations are indicated for follow-up according to stage and at which intervals?
- Which measures are appropriate for primary prevention of SCC and AK?
- Which preventive measures are indicated specifically for at-risk groups?

Squamous cell carcinoma or/and actinic keratoses as occupational diseases

- Diagnostics in patients with occupationally increased UV exposure
- Notification of suspected occupational skin cancer

2.1.2 Target Audience

The S3 guideline is primarily aimed at dermatologists, surgeons, radiologists and radiation therapists in clinics and practices, otorhinolaryngology specialists, oral and maxillofacial surgeons, and other medical specialties involved in the diagnosis and treatment of patients with AK or SCC.

The Guideline is also intended to provide information and guidance for primary care physicians (general practitioners), internists, gynecologists, urologists, internal oncologists, and other health care institutions (e.g., insurance companies and policy makers).

Furthermore, the guideline addresses patients with AK and/or SCC of the skin as well as patients who are at risk of developing these tumors, such as elderly patients with fair skin types, patients with UV-exposed skin, patients with occupationally high UV exposure, immunosuppressed patients (e.g. organ transplant patients, HIV-infected patients, patients with severe chronic inflammatory diseases).

A separate guideline on skin cancer prevention also exists.

2.1.3 Validity and Update Process

The S3 guideline is valid until the next update, the validity period is indicated for 5 years after the last update. Regular updates are planned.

Comments and advice for the update process are explicitly welcome and can be sent to the following address:

aktinische-keratose@leitlinienprogramm-onkologie.de

2.2 Methodology

The methodological procedure for the preparation of the guideline is described in the guideline report. This is freely available on the Internet, e.g., on the web pages of the German Guideline Program in Oncology ([\(Leitlinienprogramm Onkologie \(Deutsche Krebsgesellschaft, Deutsche Krebshilfe, AWMF\) et al. 2021\)](#)) and the pages of the AWMF (<https://www.awmf.org/leitlinien/detail/II/032-022OL.html>).

2.2.1 Levels of Evidence (LoE)

To classify the risk of bias of the identified studies, the 2011 version of the Oxford Centre for Evidence-based Medicine system listed in the table below was used in this guideline. This system provides for the classification of studies for different clinical questions (benefit of therapy, prognostic significance, diagnostic value).

Table 4: Scheme of evidence grading according to Oxford (2011 version)

Question	Step 1 (Level 1*)	Step 2 (Level 2*)	Step 3 (Level 3*)	Step 4 (Level 4*)	Step 5 (Level 5)
How common is the problem?	Local and current random sample surveys (or censuses)	Systematic review of surveys that allow matching to local circumstances**	Local non-random sample**	Case-series**	n/a
Is this diagnostic or monitoring test accurate? (Diagnosis)	Systematic review of cross-sectional studies with consistently applied reference	Individual cross-sectional studies with consistently applied reference standard and blinding	Non-consecutive studies, or studies without consistently applied reference standards**	Case control studies, or "poor or non-independent reference standard**	Mechanism-based reasoning

Question	Step 1 (Level 1*)	Step 2 (Level 2*)	Step 3 (Level 3*)	Step 4 (Level 4*)	Step 5 (Level 5)
	standard and blinding				
What will happen if we do not add a therapy? (Prognosis)	Systematic review of inception cohort studies	Inception cohort studies	Cohort study or control arm of randomized trial*	Case-series or case control studies, or poor-quality prognostic cohort study**	n/a
Does this intervention help? (Treatment Benefits)	Systematic review of randomized trials or n-of-1 trials	Randomized trial or observational study with dramatic effect	Non-randomized controlled cohort/follow-up study**	Case-series, case-control studies, or historically controlled studies**	Mechanism-based reasoning
What are the COMMON harms? (Treatment Harms)	Systematic review of randomized trials, systematic review of nested case-control studies, n of-1 trial with the patient you are raising the question about, or observational study with dramatic effect	Individual randomized trial or (exceptionally) observational study with dramatic effect	Non-randomized controlled cohort/follow-up study (post-marketing surveillance) provided there are sufficient numbers to rule out a common harm. (For long-term harms the duration of follow-up must be sufficient)**	Case-series, case-control, or historically controlled studies**	Mechanism-based reasoning
What are the RARE harms? (Treatment Harms)	Systematic review of randomized trials or n-of-1 trial	Randomized trial or (exceptionally) observational study with dramatic effect			

Question	Step 1 (Level 1*)	Step 2 (Level 2*)	Step 3 (Level 3*)	Step 4 (Level 4*)	Step 5 (Level 5)
Is this (early detection) test worthwhile? (Screening)	Systematic review of randomized trials	Randomized trial	Non-randomized controlled cohort/follow-up study**	Case-series, case-control, or historically controlled studies**	Mechanism-based reasoning

* Level may be graded down on the basis of study quality, imprecision, indirectness (study PICO does not match questions PICO), because of inconsistency between studies, or because the absolute effect size is very small; Level may be graded up if there is a large or very large effect size.

** As always, a systematic review is generally better than an individual study.

2.2.2 Grades of Recommendation (GoR)

In accordance with the AWMF regulations, the methodology of the German Guideline Program in Oncology provides for the assignment of recommendation grades by the guideline authors within the framework of a formal consensus process. Accordingly, moderated, nominal group processes or structured consensus conferences were conducted by the AWMF. During these processes, recommendations were formally voted on by the voting mandate holders (**see Coordination and Editing section**). The results of the respective votes (consensus strength) are assigned to the recommendations according to the categories in the table below.

In the guideline, for all evidence-based statements and recommendations, the level of evidence (**see table "Scheme of evidence grading according to Oxford"**) of the underlying studies and, in the case of recommendations, additionally the strength of the recommendation (degree of recommendation) are shown. With regard to the strength of the recommendation, three grades of recommendation are distinguished in this guideline (**see table "Scheme of recommendation grading"**), which are also reflected in the wording of the recommendations in each case.

Table 5: Scheme of recommendation grading

Grade of recommendation	Description	Expression
A	Strong recommendation	shall
B	Recommendation	should
0	Open recommendation	may/can

Table 6: Consensus strength

Consensus strength	Percentage consensus
Strong consensus	> 95% of those eligible to vote
Consensus	> 75-95% of those eligible to vote
Majority agreement	> 50-75% of those eligible to vote
Dissent	< 50% of those eligible to vote

The decision criteria for determining the grades of recommendation are explained in the guideline report for this guideline.

2.2.3 Statements

Statements are presentations or explanations of specific facts or issues without an immediate call to action. They are adopted in accordance with the procedure for recommendations as part of a formal consensus process and can be based either on study results or on expert opinions.

2.2.4 Expert Consensus (EC)

Statements/recommendations for which editing was decided on the basis of expert consensus of the guideline group are shown as „expert consensus“. No symbols or letters were used for the graduation of expert consensus; the strength of the consensus point results from the wording used (shall/should/can).

2.2.5 Independence and Disclosure of Possible Conflicts of Interest

The German Cancer Aid provided the financial means via the German Guideline Program in Oncology (GGPO). These funds were used for personnel costs, office supplies, literature procurement, and the consensus conferences (room rental, technical equipment, catering, moderator fees, travel expenses of participants). The guideline was developed in editorial independence from the funding organization.

All members submitted a written declaration of any conflicts of interest during the guideline process. The conflicts of interest disclosed in the AWMF form are listed in the guideline report for this guideline (<https://www.leitlinienprogramm-onkologie.de/leitlinien/aktinische-keratosen-und-platteneplithelkarzinom-der-haut/>). They were reviewed and evaluated by the coordinators and subsequently the procedure was decided by consensus in the guideline group.

The specific procedure and the consequences are also listed in the guideline report.

3 Epidemiology and etiology

U. Leiter, J. Becker, E. Breitbart, T. Eigentler, C. Garbe, R. Greinert, K. Kraywinkel

3.1 Epidemiology of actinic keratosis

Hardly any reliable data on the epidemiology of AK exist. There are few data on the prevalence of AK; in Germany, the prevalence was calculated in 2014 in 90,800 workers based on data from the statutory health insurance funds. The prevalence for all age groups was 2.7% and increased with age (11.5% in the 60-70 age group). Men (3.9%) were more frequently affected than women (1.5%) [1]. In the Netherlands, the prevalence of AK in those over 45 years of age is 49% for men and 28% for women [2]. Green et al. showed that there is an increase in prevalence with age, so that it is already 20% in men over 60 years and as high as 52% in men over 70 years [3], [4]. In the last decade a clear increase of AK could be determined. The reason for this, apart from etiological factors such as chronic UV exposure, is demographic change with higher proportions of an older population. It is estimated that 1.7 million people in Germany are currently undergoing dermatological treatment for AK. However, the number of patients who actually suffer from AK is much higher and will continue to increase in the coming years in line with the population structure [1]. Patients with occupational natural UV exposure (outdoor workers) are also significantly more likely to have AK than people who mainly work in offices [5]. This observation has led to the recognition of the presence of AK in certain occupational groups as an occupational disease (BK 5103).

3.2 Epidemiology of invasive squamous cell carcinoma

3.2.1 Incidence

SCC is the second most common skin tumor after basal cell carcinoma and represents 20% of all non-melanocytic skin tumors (NMSC) [6]. According to estimates by the Robert Koch Institute, approximately 29,300 men and 20,100 women developed SCC for the first time in Germany in 2014. The incidence of SCC is estimated to have increased 4-fold in Germany over the past 30 years [7], [8], [6]. The term "skin cancer epidemic" was coined to illustrate this phenomenon. It is likely that NMSC are currently not sufficiently recorded in full extent in most cancer registries in Germany also due to their predominantly outpatient therapy. Therefore, complete epidemiological data are not available and the above-mentioned estimates are still subject to greater uncertainty [9]. Internationally, the data situation is also severely limited; in many countries, NMSCs are not recorded at all in cancer registries.

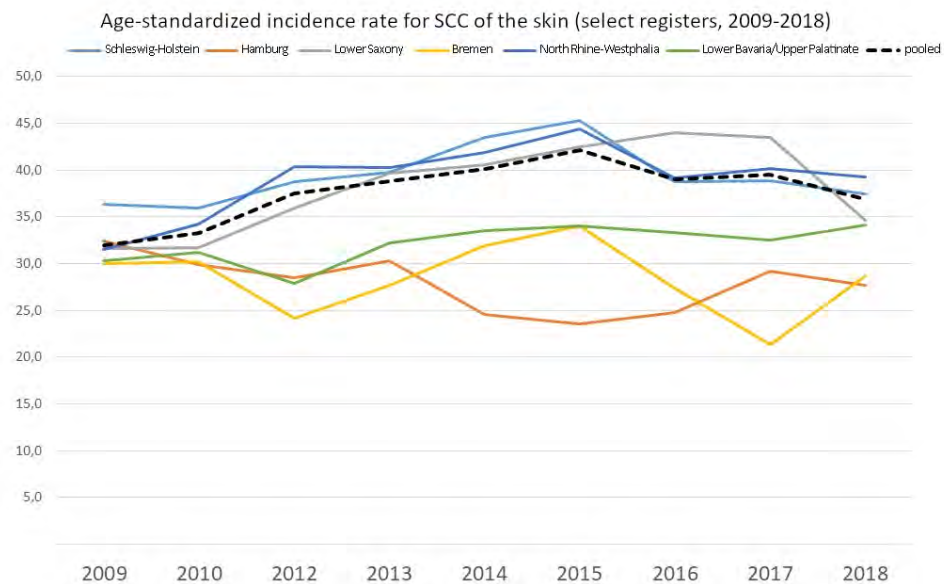


Figure 1: Age-standardized incidence rate for SCC of the skin (select registries by state, period 2009-2018)

An analysis of German Cancer Registry data for the periods from 1998 to 2010 for 14 German states shows a continuous increase in the age-standardized incidence of NMSC by a factor of 2.4—during this period, corresponding to an annual increase of 10.5% per year until 2003, after which the annual increase is 6.7% [9]. In the state of Schleswig-Holstein, a significant increase in the incidence of NMSC was observed in 2003-2004 from 81.5/100,000 to 111.5/100,000 (1998–2000). This represents an increase of 47% for women and 34% for men, which has been attributed to the skin cancer screening pilot project [10], [11]. Due to this, detection rates improved and led to an increase in incidence rates. From 2008 onwards, mandatory skin cancer screening was introduced nationwide in Germany and a similar increase was observed in the course in other German states (47% in women and 40% in men) [10]. This may also be due to a certain extent to increased diagnosis of tumors that might never have been diagnosed. Because many NMSCs never cause symptoms, they are detected incidentally or only when the patient undergoes screening. This is especially true for older patients (> 60 years), 36% of whom participated in the screening program more often than others [12].

Table 7: Age-standardized incidence rate for SCC of the skin for regions with coverage judged to be sufficiently high and stable (per 100,000 persons and year, old European standard)

Incidence - DMDR (direct method death rate; Europe old, age total)			
	2009-2013	2014-2018	Change
Schleswig-Holstein	38.3	40.8	6%
Hamburg	30.1	26.0	-13.9%
Lower Saxony	35.0	41.0	17%
Bremen	29.5	28.7	-3%
North Rhine-Westphalia	37.0	41.0	11%
Lower Bavaria/Upper Palatinate	30.1	33.5	12%
Pooled	35.7	39.5	11%

* for the incidence rate only the first squamous cell carcinoma of the skin (per person) is considered

Another reason for the massive increase in NMSC may be due to the improvement of registration in cancer registries, whose results are probably increasingly converging. However, by definition, epidemiologic cancer registries do not reflect the entire disease burden of NMSC because only the first skin tumor in a given histology is counted as an incident case and all subsequent tumors of the same type are classified as recurrence [6]. However, the occurrence of multiple NMSC, basal cell carcinoma, or SCC is common [13]. An Australian study was able to show that 50% of patients develop further tumors, most of them within the first year after primary diagnosis [14].

Current data on the epidemiology of SCC were provided for this guideline by the Robert Koch Institute for Germany. Since data on the incidence of SCC over a longer period of time are not available from all federal states, data considered to be reliable were combined from a pool of different federal states such as Hamburg, Schleswig-Holstein, Bremen, Lower Saxony, Mecklenburg-Western Pomerania, Rhineland-Palatinate, and the administrative districts of Münster (North Rhine-Westphalia), Lower Bavaria, and Upper Palatinate (Bavaria). Based on this, incidence rates of SCC of the skin were presented over a 10-year period (2009-2018). The recorded age-standardized incidence rates currently range between 20/100,000 inhabitants and 37/100,000 inhabitants per year (old European standard), depending on the region.

Comparing the rates in 2009-2013 with the rates in 2014-2018 shows an increase in incidence rates of up to 42% in some states, and no increase was observed in some registries.

Table 8: Crude incidence rates as projected case numbers in Germany in 2014-2018

Age group	Age-specific incidence rate for pooled registries, 2014-2018		Population		Projected case numbers for 2018	
	Men	Women	Men	Women	Men	Women
0-14	0.0	0.1	5,874,035	5,560,496	3	4
15-19	0.1	0.1	2,015,167	1,882,842	1	1
20-24	0.3	0.2	2,405,359	2,184,102	6	5
25-29	0.5	0.4	2,594,394	2,399,311	13	9
30-34	0.6	0.7	2,853,602	2,684,803	17	20
35-39	2.0	1.7	2,685,997	2,604,046	53	44
40-44	4.0	3.7	2,501,071	2,470,886	101	92
45-49	8.5	8.2	2,587,609	2,567,000	221	210
50-54	15.0	13.5	3,324,451	3,274,279	499	443
55-59	29.2	22.0	3,392,257	3,385,055	992	744
60-64	55.0	34.5	2,823,007	2,909,947	1,552	1,005
65-69	115.0	63.2	2,323,158	2,555,911	2,672	1,616
70-74	243.6	117.1	1,786,397	2,034,686	4,352	2,383
75-79	424.9	183.6	1,642,030	2,030,194	6,977	3,727
80-84	606.6	254.4	1,401,304	1,961,088	8,501	4,989
85 plus	799.9	365.5	822,231	1,624,163	6,577	5,936
total			41,032,069	42,128,809	32,537	21,228

The risk of developing SCC increases with age even more significantly than for many other types of cancer. In 2016, 21% of people over 65 were diagnosed with SCC. As the number of older people in Germany continues to increase, a further increase can be expected due to demographic changes alone [6]. The number of people over 65 years of age will increase from 17.4 million (2016) to approximately 20 million in 2025, and thus the incidence rates for cutaneous SCC will also increase [Figure 2](#).

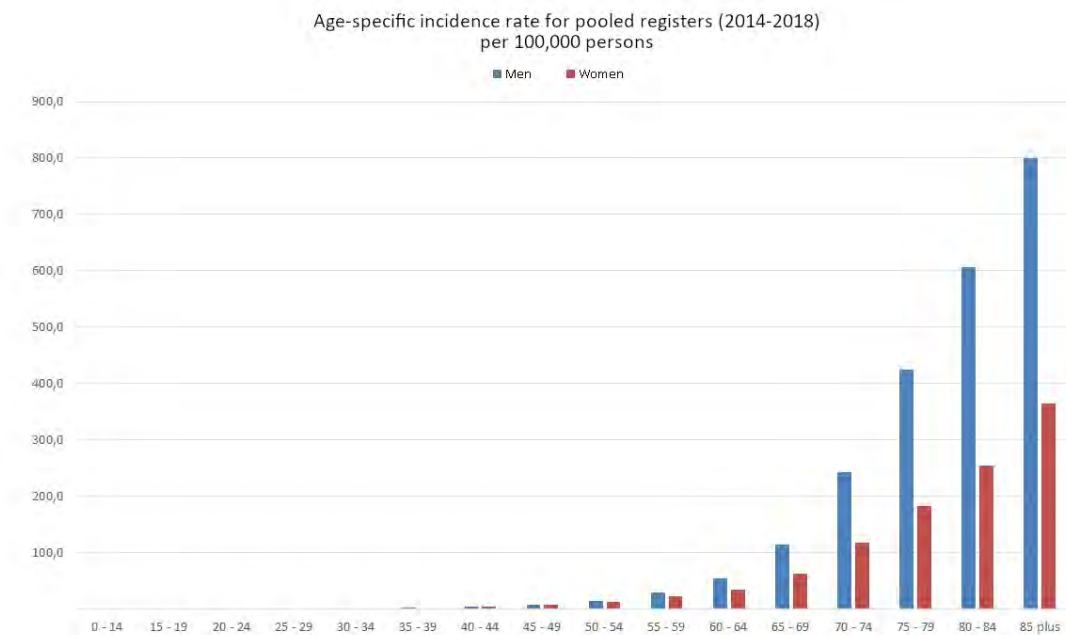


Figure 2: Age-specific incidence rate for pool registries (2014-2018) per 100,000 persons

European data show geographically determined differences. The highest incidence rates are reported in Wales (United Kingdom), the Netherlands, and Switzerland (age-standardized rate according to the European standard, 31.7/100,000, 22-35/100,000, and 28.9/100,000 population in 2012, respectively) [15], [16]. [Figure 3](#) shows the progression of age-standardized incidence rates in the Netherlands since 1989 and compares them with rates in Germany. In the United States, approximately 600,000 patients were treated with SCC in 2006, and an estimated 3,900-9,000 died from it.

The highest incidence rates of NMSC are reported in Queensland, Australia, and are 772 for men and 442/100,000 population per year for women [17]. In the Southern states of the US, mortality rates are reported to be similar to those for malignant melanoma, with up to 8,791 patients dying in 2012 [18]. SCC is more common in males than females and is 80% localized to the head and face, or to areas chronically exposed to UV light. The average age is 70 years [19]. SCC can metastasize primarily to the regional lymph nodes and form distant metastases. The rate is approximately 5%, in some subgroups up to 20%. If distant metastases are present, the prognosis is poor, with a median survival of less than 2 years. Therefore, early diagnosis and therapy of this tumor are critical [19].

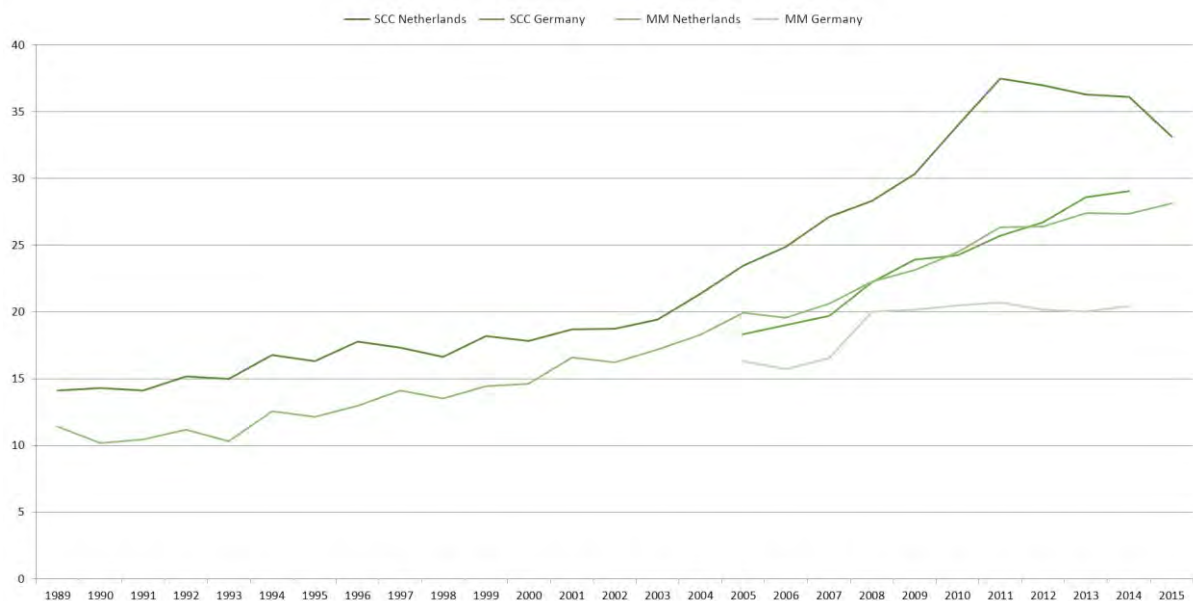


Figure 3: Age-standardized disease rates for SCC of the skin in the Netherlands and Germany (men and women); compared with incidence rates for melanoma

3.2.2 Mortality

The mortality of NMSC is low and has remained largely stable in Germany over the last 25 years [9]. In 2015, 464 men and 350 women died from NMSC according to official cause of death statistics; the proportion of SCC is unknown due to the lack of mappability in ICD-10. Data from the Federal Statistical Office describe a mortality rate of 0.65 for men and 0.3 for women in 2011-2015; in 1991-1995, this was 0.62 for men and 0.27 for women. Various publications show a low rate of disease-specific compared to general causes of death [20], [21], [13].

3.2.3 Etiology and pathogenesis

The development of AK is predominantly caused by chronic UV exposure, especially to UV-B. A relationship between cumulative UV dose and the occurrence of AK has been demonstrated in numerous studies [5]. UV radiation induces a mutation of the tumor suppressor gene p53, which is considered to be causative for the development of AK. P53 plays a crucial role in cell cycle regulation and induces apoptosis of mutant cells. UV-B radiation leads to a characteristic „UV-typical“ transition from cytidine to thymidine in the tumor suppressor gene p53, resulting in a loss of function of the gene product p53. As a consequence, uncontrolled proliferation of degenerated cells occurs with subsequent appearance of AK [22].

UV radiation probably also leads to an activating mutation in codon 12 of the Ras oncogene H-Ras and thus influences the regulation of cell proliferation. This mutation leads to a permanent activation of the signaling pathway and thus to an increased cell proliferation. A corresponding mutation could be detected increasingly in AK and SCC of the skin. An association between AK or SCC and infections with human papilloma viruses (HPV) has been discussed repeatedly [23]. On the other hand, HPV DNA is also detected in normal skin and in hair follicles, which would accordingly also indicate a coincident association.

In mucocutaneous genital SCC, the etiologic relevance of HPV infection is better established, although again not the sole cause. One type of vulvar SCC occurs primarily in older women and develops from lichen sclerosus. The other type is more common in younger women and develops from vulvar intraepithelial neoplasia (VIN) caused by HPV infection. Penile SCC can also be divided etiologically into two groups. One type develops primarily in the presence of phimosis or chronic inflammation (balanitis), often due to poor hygiene. The second type develops from HPV infection, particularly serotypes 6, 11, 16, and 18. Similarly, scrotal SCC may be HPV-related or non-HPV-related.

For SCC of the vulva and penis, please refer to the respective current guidelines:

Vaginal carcinoma: <https://register.awmf.org/de/leitlinien/detail/032-042>

Penile carcinoma: <https://www.leitlinienprogramm-onkologie.de/leitlinien/peniskarzinom/>

The etiology of SCC is multifactorial and includes, in addition to a genetic or immunological predisposition, primarily exogenous trigger factors, first and foremost UV radiation. Due to its oncogenic potential, this was included in Group 1 of the established carcinogens by the WHO in 2009 [24], and plays a key role in the context of the newly established occupational disease BK 5103 of cutaneous SCC in Germany as cumulative „natural UV radiation“. Chemical carcinogens such as polycyclic aromatic hydrocarbons or arsenic are secured as full-fledged carcinogens in the induction of cutaneous SCC.

3.2.4 Risk factor immunosuppression

Epithelial skin tumors are by far the most common malignant neoplasms after organ transplantation and a typical long-term complication of chronic immunosuppression [25], [26], [27]. In the well-studied collective of organ transplanted patients, SCC are the most frequently diagnosed tumors with over 65-fold increased incidences [26]. In contrast, the incidence of basal cell carcinomas, which dominate the immunocompetent Caucasian population, is only increased by a factor of 10 after organ transplantation, and thus proportionally much less [26]. In addition, organ transplanted patients also show a significantly higher risk of developing AK. The incidence for the development of NMSC increases with the number of years under immunosuppression and is 40–60% after 20 years. In addition, there is a much more aggressive growth pattern of AK in organ transplant recipients with early progression to SCC [28].

The occurrence of a first invasive SCC, often on chronically UV-damaged skin on the ground of field cancerization typically represents an indicator lesion in organ transplant recipients of an at least 10-fold increased risk for the development of further SCC in often increasingly shorter time intervals [29], [30]. In addition, SCC under immunosuppression typically show a more aggressive growth behavior, which is histologically characterized by a tendency to infiltrative tumor growth and perineural invasion and clinically by an increased metastasis rate of 5-8%, a higher local recurrence rate (up to 13.4%) and multifocal, often eruptive occurrence [25], [26], [29], [31], [32], [27].

3.3 Prognostic factors for the transition from actinic keratosis to invasive squamous cell carcinoma

3.1	Consensus-based statement	modified 2022
EC	<p>The data situation for reliable prognostic factors of the transition from AK to SCC is insufficient. At the moment, no reliable values for the probability of progression can be given. The following clinical factors are prognostically unfavorable:</p> <ul style="list-style-type: none"> • Immunosuppression • Therapy resistance • Field cancerization 	
	Strong consensus	

3.2	Consensus-based statement	modified 2022
EC	Existing clinical and histological systems (e.g., classification according to Olsen, graduation into KIN 1-3, counting of lesions) are not sufficiently validated prognostically and thus dispensable in clinical practice.	
	Consensus	

Background

AK is an epidermal malignant proliferation of keratinocytes ("in-situ carcinoma") of human skin, which is considered a precursor for SCC. AK occurs mainly in fair-skinned individuals in sun-exposed localizations. The main risk factor for the occurrence of AK is cumulative UV exposure from the sun and/or tanning beds [33]. Histologically, AK represents a dysplasia formed by keratinocytes that have atypical nuclei that are enlarged, irregular and hyperchromatic. To stratify the degree of epidermal dysplasia, 3-stage scales were proposed to describe the transition from AK to SCC.

Thus, the progressive stages of keratinocytic intraepidermal neoplasia (KIN) were divided into 3 stages. In KIN I, atypical keratinocytes are found in the lower third of the epidermis. This stage may then evolve to lesions occupying the lower two-thirds of the epidermis (KIN II) and subsequently penetrating the full thickness of the epidermis (KIN III) [34].

In a later classification with better clinicopathologic characterization, the progression stages of AK were termed early in-situ SCC of type AK I, AK II, and AK III. The purpose of this classification was to indicate that all forms of AK (AK I, AK II, and AK III) represent in-situ SCC at different stages of progression from the very beginning.

Again later, Stockfleth et al. suggested that all AK should be evaluated as intraepidermal SCC without being able to predict which cases have the potential for progression to invasive SCC [35]. However, this proposal was not universally accepted

and recently AK were classified as premalignant and/or precancerous with KIN III/AK III as in situ SCC [34].

The classification and data for prognostic factors determining the transition from AK to SCC remain inadequate. Fernandez-Figueras et al. demonstrated that their data support both the hypothesis of a sequential progression ("classical pathway") from AK to invasive SCC and a nonsequential sequence [34]. Histological evaluation of the epidermis of overlapping or adjacent epidermis of invasive SCC (196 biopsy specimens) showed that these cases were associated with the appearance of AK II and AK III in 17.9% and 18.4%, respectively, but were also associated with AK I in 63.8%. The authors therefore favor direct transformation of AK I to invasive SCC (so-called "differentiated pathway").

Older data on progression from AK to SCC give estimates of 0.025% up to 16% for an individual lesion per year. Therefore, for a patient with 6-8 lesions, transformation rates of 0.15%-80% per year have been estimated. In one of the largest prospective studies by Criscione et al. in the follow-up of AK over 5 years, the risk of progression from AK to invasive SCC was shown to be 0.60% at year 1 and 2.57% at year 4 after initial diagnosis of AK [36].

The types of studies included vary. Study designs range from histological case descriptions, retrospective surveys, correlational studies, "nested case-control studies", "retrospective case-controlled studies", multicenter cohort studies, to a systematic review [37], [38], [39], [40], [41], [42]. Other publications, mostly case-control studies, retrospective studies, or cohort studies with low evidence level ratings (3-4) failed to demonstrate differences in sex, age, and lesion location when analyzing prognostic factors and the time interval between AK and SCC transformation [38], [41], [42]. There was no correlation between epidermal thickness, degree of dysplasia and p53 expression. In immunosuppressed patients, an association between the size of AK-burdened areas and SCC risk was observed. In another study, 29% of 452 renal transplant patients were diagnosed with AK at baseline. In 13% of kidney transplant patients with AK without field cancerization, 7% developed SCC compared with 15% of patients with AK with field cancerization.

However, the systematic review also does not reach a „clear conclusion“ (because of inconsistent data), but summarizes that the absolute risk of developing SCC in an AK lesion on the head is 0.42. The time for progression of an AK lesion in the head to SCC is reported to be between 16-34 months [43].

Overall, there is a paucity of studies and inferred evidence for prognostic factors and transition probabilities from AK to SCC. A 2013 systematic literature review [44], which analyzed 24 studies, concluded: „In general, available data are limited. Important methodological limitations apply. Currently, reliable estimates of the incidence of AK development to invasive carcinoma are not possible and further studies are needed.“ Recent studies by Dirschka et al. and Dreno et al. also indicate that the previous staging of AK, its progression to SCC, and necessary preventive therapies need to be reconsidered [45], [46]. In their work, against the background of the occurrence of AK in a field cancerization, new assessment criteria for the stages of AK were developed (AK field assessment scale: AK-FAS; AK area and severity index: AKASI), which contribute to a new evaluation.

When assessing the data and study situation on the prognosis of AK transition to SCC, it is particularly noticeable that studies on the genetic, epigenetic and cellular

level are too rarely performed and/or used to determine validated and clinically applicable parameters that ensure meaningful, evidence-based prevention and treatment of AK for the benefit of the affected individuals and with a balanced cost-benefit consideration for the health care system. This should be improved in the light of available modern molecular biological methods.

3.4 Prognostic factors for metastasis in invasive squamous cell carcinoma

3.3	Evidence-based statement	checked 2022
LoE 4	Histopathologic factors (vertically determined tumor infiltration depth, desmoplasia, degree of differentiation, perineural growth) and clinical factors (localization, horizontal tumor diameter, comorbidities such as immunosuppression) are considered prognostic factors for metastasis or disease-specific survival.	
	[47] , [48] , [49] , [50] , [51] , [52] , [53] , [54] , [55] , [56] , [57] , [58] 4: De novo research	
	Strong consensus	

Background

The following factors are considered prognostic for metastasis or disease-specific survival in cutaneous SCC:

- Vertical tumor thickness (>6 mm)
- Horizontal tumor diameter (≥ 2 cm)
- Histological differentiation (> grade 3)
- Desmoplasia
- Perineural growth
- Localization (lower lip, ear)
- Immunosuppression (iatrogenic or disease-related).

These apply to the following chapters on diagnosis, surgical and systemic therapy of SCC, and follow-up. The data on prognostic factors are based on manageably large collectives, which were usually analyzed retrospectively. Only a few publications show prospective data.

Cutaneous SCC is a tumor with a relatively low risk of metastasis, although the frequency of patients with metastatic SCC and thus the clinical relevance is relativized by the extremely high incidence. The risk of metastasis was 4% in a prospective cohort of 615 patients with a median follow-up of 43 months [\[19\]](#). Local recurrence also occurred in 3% of patients. Metastases occurred in 4% of tumors that were between 2.1 mm and 6.0 mm thick and in 16% of tumors with tumor thickness greater than 6.0 mm. SCC with a vertical tumor thickness of 2.0 mm or less did not metastasize in this population. On multivariate analysis, the most important prognostic factors for metastasis were increased tumor thickness (HR 4.79; 95% CI 2.22-10.36; $p < 0.0001$), immunosuppression (HR 4.32; 95% CI 1.62-11.52; $p = 0.0035$),

and localization to the ear (HR 3.61; 95% CI 1.51-8.67; $p=0.0040$). The risk of local recurrence depended on increased tumor thickness (HR 6.03; 95% CI 2.71-13.43; $p<0.0001$) and the presence of desmoplasia (HR 16.11; 95% CI 6.57-39.49; $p<0.0001$) [19].

In a large retrospective study, Schmults et al. identified a local recurrence rate of 4.6% [53], in 985 patients with 1,832 tumors and a median follow-up of 50 months. The rate of patients with local lymph node metastases was 3.7%. The case-related disease-specific mortality rate was 2.1%. In multivariate risk analyses, independent predictors of lymph node metastasis and disease-specific death were: horizontal tumor diameter of at least 2 cm (HR 7.0; 95% CI 2.2-21.6 and HR 15.9; 95% CI 4.8-52.3) and low differentiation (HR 6.1; 95% CI 2.5-14.9 and HR 6.7; 95% CI 2-7). Perineural invasion was significantly associated with disease-specific death (HR 3.6; 95% CI 1.1-12.0). Overall survival was associated with poor differentiation (HR 1.3; 95% CI 1.1-1.6) and invasion beyond adipose tissue (HR 1.7; 95% CI 1.1-2.8).

The observations from these large prospective and retrospective studies were also evident in other, smaller retrospective studies. Brinkman and colleagues examined prognostic factors in 131 patients with 155 SCC [47], in a retrospective analysis. Here, tumor differentiation grade was an independent prognostic factor for metastasis and overall survival. Metastasis-free survival was significantly higher in well-differentiated tumors (70%) than in moderately (51%) and poorly differentiated tumors (26%; $p=0.012$). Comparable percentages were found for overall survival ($p=0.005$).

Campoli et al. demonstrated in a retrospective analysis that perineural invasion was related to other prognostically relevant factors [48]. Here, perineural invasion was significantly associated with localization in the head and neck region ($p=0.039$), larger tumor diameter ($p<0.001$), thicker tumors ($p<0.001$), low tumor differentiation ($p<0.001$), presence of clinically detectable lymph nodes ($p=0.012$), and recurrent ($p<0.001$) and painful tumors ($p<0.001$). In addition, perineural invasion occurred significantly in association with thicker tumors ($p<0.001$).

In a publication by Haisma on SCC in the head and neck region, the following parameters were shown to be prognostic factors for metastasis to local lymph nodes [49]: tumor thickness >2 mm, horizontal tumor diameter >5 cm, low differentiation and localization to the ear.

In the retrospective analysis by Cherpelis and colleagues, horizontal tumor extent, vertical penetration of analogous anatomic structures (Clark level), degree of differentiation, presence of small tumor nests, infiltrative tumor strands, single cell infiltration, perineural invasion, acantholysis, and local recurrence were significantly associated with metastasis [54]. In contrast, tumor location, ulceration, inflammatory infiltrate, and Breslow absolute penetration depth did not correlate with metastatic development.

Ch'ng et al. showed in a multivariable model that the degree of differentiation correlated with disease-free survival (HR, 0.2; 95% CI 0.1-0.8; $p=0.03$), but not tumor-free cut margins, horizontal tumor diameter, or vertical tumor thickness [56]. A number of other publications confirmed the above risk factors in increasingly smaller collectives [59], [50], [51], [52], [57].

4 Diagnostics

M. Flaig, M. Heppt, U. Hillen, T. Dirschka, S. Ihrler, C. Pfannenberger, L. Schmitz, J. Welzel

4.1 Classification, definition and nomenclature of actinic keratosis

4.1	Consensus-based recommendation	checked 2022
EC	The term "actinic keratosis" shall be used.	
	Strong consensus	

4.2	Evidence-based statement	new 2022
LoE 2	Multiple qualitative and quantitative factor integrating scores (e.g. AK-FAS, AKASI) improve standardized reporting of findings for actinic keratosis.	
	[45], [60], [46] 2: De novo research	
	Strong consensus	

AK is a clinically and histomorphologically detectable skin lesion characterized by a proliferation (hyperplasia) of atypical epidermal keratinocytes that do not exhibit a basaloid phenotype. Multiple factors such as lesion number, size of affected area, or localization integrating scores (e.g., AK-FAS, AKASI) improve standardized clinical findings for AK both as baseline findings prior to therapy initiation and during the course to evaluate therapy response [60], [46], [45]. The cytomorphologic and genetic alterations of atypical keratinocytes resemble tumor cells of invasive SCC of chronically light-exposed skin. Currently, there is insufficient evidence that histomorphologic parameters translate into a clinical and/or therapeutically relevant consequence. In this respect, a detailed and extensive documentation of criteria beyond the mention of the diagnosis and subtype does not seem necessary or helpful.

The term "actinic keratosis" has long been widely established in both clinical and histopathological usage. Basically, it is a common but, at its core, imprecise term, since changes designated by this diagnosis need not have an obligatory actinic (solar, sunlight-induced) genesis (e.g., arsenic or PUVA keratoses), nor need they be obligatorily accompanied by a clinically or histologically manifest keratosis (clinically keratotic scale, histomorphologically ortho- and/or hyperparakeratosis). Furthermore, the term does not describe histogenesis, as is usually the case in pathology. Synonyms include "solar keratosis", "senile keratosis", "in situ SCC of AK type",

"keratinocytic intraepithelial neoplasia" and "squamous intraepithelial neoplasia". A common histomorphological feature of all of these is an obligatory atypia of keratinocytes of the surface covering epidermis. Cytomorphologically, the atypia of keratinocytes to be detected is manifested by nuclear hyperchromasia, nuclear pleomorphism, enlarged nuclei and high nuclear/cytoplasmic correlation. In addition, there are architectural criteria with alteration of the usual layering of the epidermis, increasing loss of polarity, which are manifested by an apparently random arrangement of intraepidermal keratinocytes and high cell density in the stratum basale ("crowding").

The extent of histomorphologically detectable changes is highly variable. Thus, initial AK show only single atypical keratinocytes. However, hyperplasia may lead to displacement of keratinocytes appearing normal in the epidermis in varying proportions up to complete replacement. Frequently, although not obligatorily, hyperkeratosis is found over these atypical keratinocytic proliferates, which in the prototypical case shows an alternation of ortho- and parakeratotic portions ("pink and blue"). The epidermal band can appear narrowed, unchanged or acanthotic widened compared the surrounding epidermis. The appearance of rete ridges can be equally variable. These may be completely absent, small and plump in shape as in lentigo solaris or senilis, or hypertrophic and developed with bridging. These descriptive histomorphologic characteristics were used as the basis for a classification of basal proliferation patterns (PRO-I-III). PRO-I comprises hyperplasia of basal atypical keratinocytes ("crowding"), PRO-II initial plump rete ridges hyperplasia ("budding"), PRO-III ("papillary sprouting") filiform reteridges hyperplasia exceeding the width of the overlying epidermis [61], [62]. The decisive differentiating criterion for distinguishing AK from invasive SCC of the skin is evidence of endophytic proliferation of atypical keratinocytes crossing the basal membrane in non-traumatized skin.

In analogy to the diversity of clinical AK, the following variants are described histomorphologically:

- atrophic AK
- hypertrophic AK
- proliferative AK
- acantholytic AK
- pigmented AK
- lichenoid AK (with marked interface dermatitis, degenerating lymphocytic inflammatory reaction at the basal membrane zone, "interface")
- bowenoid AK.

The latter refers to a variant in which there is polymorphism and atypia of the keratinocytes involved, as is typical in classic Bowen's disease. Frequently, several different manifestations of AK are found in close proximity in tissue samples. Sometimes the atypical keratinocytes can also be visualized in apical portions of adnexal epithelium. Often, but not always, a usually only sparse inflammatory infiltrate in the papillary dermis is associated with the appearance of the atypical keratinocytes. Almost always, actinic elastosis is found in the upper layers of the dermis.

The histomorphologic picture of AK ranges from the spectrum of merely actinically damaged skin with initial atypia of single keratinocytes to a complete replacement of

the localized epidermis by atypical keratinocytes, which then corresponds to an epidermal carcinoma in situ, or in the case of high-grade atypia and polymorphism of keratinocytes, to Bowen's disease. To further classify this morphological spectrum, a three-tiered classification scheme (KIN I-III) has been proposed in analogy to the mostly HPV-induced intraepithelial neoplasms of the cervix uteri, corresponding to cervical, vulvar, penile, anal and perianal intraepithelial neoplasia according to the layers of the epidermis involved. This concept has always been controversially discussed and disputed, since invasive processes can arise from all stages; a three-stage classification system naturally has a very high interobserver imprecision and, moreover, no tangible clinical consequences have yet entered clinical routine. The same applies in principle to the three-level PRO classification [61], [62], [63], [64].

Histomorphologically similar intraepidermal atypical proliferates occur in PUVA keratosis. In this case, the cytomorphological changes may be much less pronounced compared to classic AK. In the context of arsenic keratosis, the pronounced actinic elastosis is often absent in histomorphological analysis.

4.2 Classification, definition and nomenclature of cheilitis actinica

4.3	Consensus-based statement	new 2022
EC	Cheilitis actinica is etiologically and morphologically the counterpart of actinic keratosis of the keratinizing squamous epithelium of the vermillion.	
	Strong consensus	

Clinically, cheilitis actinica manifests mostly on the lower lip and is characterized by persistent dry scaling, leukoplakia, atrophy, blurred appearance of the lip red border, occasionally persistent swelling and erythema, persistent rhagades and ulcerations.

Mandatory histomorphological characteristics include actinic elastosis and a usually marked accompanying inflammatory infiltrate. Epithelial changes include cytological as well as architectural changes to individually varying degrees, which correspond to the usual epithelial dysplasia criteria: cellular and nuclear polymorphism, atypia, nuclear hyperchromasia, increased and enlarged nucleoli, basally accentuated stratification irregularities, loss of basal polarity, dyskeratoses, formation of plump or drop-shaped rete ridges. Analogous to other locations, evidence of endophytic proliferation of atypical keratinocytes crossing the basal membrane in non-traumatized skin corresponds to invasive growth and necessitates the diagnosis of invasive lip carcinoma.

Two- or three-stage classifications of cheilitis actinica have not gained acceptance due to lack of reproducibility and clinical consistency.

4.3 Classification, definition and nomenclature of squamous cell carcinoma in situ (Bowen's disease)

4.4	Consensus-based statement	checked 2022
EC	Bowen's disease is defined as an intraepidermal proliferation of highly atypical and polymorphic keratinocytes involving the entire epidermis. In this respect, Bowen's disease represents a special variant, which can progress into an invasive, then usually bowenoid differentiated (pleomorphic, low differentiated) squamous cell carcinoma ("Bowen's" carcinoma).	
	Strong consensus	

4.4 Classification, definition and nomenclature of invasive squamous cell carcinoma

4.4.1 Definition and nomenclature

4.5	Consensus-based statement	checked 2022
EC	Squamous cell carcinoma of the skin is a malignant neoplasm of the keratinocytes of the epidermis. The tumors can develop different degrees of differentiation (see also WHO/UICC classification).	
	Strong consensus	

4.6	Consensus-based statement	checked 2022
EC	Squamous cell carcinoma of the skin arises in most cases, but not necessarily, as a result of intraepidermal proliferation of atypical keratinocytes.	
	Strong consensus	

4.7	Consensus-based statement	checked 2022
EC	Invasive squamous cell carcinoma of the skin is said to occur when there is histomorphologically demonstrable disruption of the basal membrane beneath an intraepithelial keratinocytic proliferation in non-traumatized skin.	
	Consensus	

The most important etiological factor is chronic UV exposure, especially in UV-sensitive individuals. Risk factors for the development of SCC include AK, older age, cumulative sun exposure and light pigmentation. The most important risk factor is the presence of AK [65]. The likelihood of a single AK progressing to invasive SCC cannot be accurately quantified (Chapter 5.2). In addition to malignant transformation by UV radiation, other etiological factors may play a role. These include chronic wounds and inflammation such as leg ulcers, burns, scars, lichenoid disease, and bullous dermatoses. Arsenic exposure and X-rays may also promote malignant transformation. In immunosuppressed individuals, the incidence is greatly increased and the disease courses are less favorable. This is true for patients with iatrogenic immunosuppression after organ transplantation and for immunosuppression in malignant diseases and HIV infection. In immunosuppressed patients, malignant transformation is triggered by an increased rate of infection with carcinogenic HPV. Genetic syndromes with increased risk for SCC are albinism, xeroderma pigmentosum, Muir-Torre syndrome, epidermolysis bullosa hereditaria etc.

4.4.2 Classification and staging

4.8	Consensus-based statement	checked 2022
EC	<p>The following variants of squamous cell carcinoma of the skin can be distinguished histomorphologically (some of these are reflected in the WHO/ UICC classification):</p> <ul style="list-style-type: none"> • Adenosquamous squamous cell carcinoma of the skin. • Acantholytic (adenoid, pseudoglandular) squamous cell carcinoma of the skin • Bowen's carcinoma/bowenoid differentiated squamous cell carcinoma of the skin • Desmoplastic squamous cell carcinoma of the skin • Keratoacanthoma-like squamous cell carcinoma of the skin/keratoacanthoma • Lymphoepithelioma-like squamous cell carcinoma of the skin • Pseudovascular (pseudoangiosarcomatous, pseudoangiomatous) squamous cell carcinoma of the skin • Spindle cell (sarcomatoid) squamous cell carcinoma of the skin • Verrucous squamous cell carcinoma of the skin (epithelioma cuniculatum) 	
	Strong consensus	

4.9	Consensus-based statement	checked 2022
EC	Classification of squamous cell carcinoma of the skin should be based on histological and clinical parameters according to the currently used TNM systems of the UICC or AJCC.	
	Strong consensus	

A special variant of SCC is keratoacanthoma, which usually has a benign course. Clinical differentiation from SCC is uncertain. Although keratoacanthoma is usually identified as such due to its rapid growth progression and hemispherical growth form reliable clinical and/or histological differentiation is problematic and sometimes arbitrary. Characteristic features are the formation of a central horny plug, high degree of differentiation, marked symmetry and a broad-based infiltrative front. It may regress spontaneously. Primary therapy and histological workup as in the presence of SCC should be carried out. This is especially true for patient groups at increased risk of metastasis.

Verrucous SCC of the skin represents a particularly well-differentiated form for which invasive growth but rarely distant metastasis has been described. Epithelioma cuniculatum, oral florid papillomatosis and the so-called giant condylomata (Buschke-Löwenstein) are also assigned to this histological diagnosis (according to WHO / UICC classification). Not yet included in the international classification is desmoplastic SCC with high stromal content and narrow cell strands, which shows marked infiltrative growth that is sometimes perineural or perivascular. This type should be distinguished from the collective of common SCC with its high recurrence (approximately 25%) and metastatic (approximately 10%) potency. In patients treated with a selective BRAF inhibitor (e.g., vemurafenib, dabrafenib, encorafenib), keratoacanthomas have also been regularly described preferentially in chronically UV-exposed areas.

In addition, the WHO / UICC / AJCC classification can be used (see [Table 9](#) and [Table 10](#)). This is particularly useful for clinically very large SCC. However, at present classification for SCC of the skin does not appear to be well-developed, as it can convey differentiating information for only a very small proportion of tumors. Traditionally, a clinical classification is made into "low-risk" tumors of ≤ 20 mm and "high-risk" tumors of > 20 mm tumor diameter (clinical parameter). Both classifications divide according to clinical and radiological parameters, respectively. In both classifications, the T1 category is defined by horizontal tumor extent (≤ 20 mm) and the T2 category (> 20 mm). In the AJCC classification, the T1 category is further supplemented by means of 6 additional "high-risk" factors, which are classified according to clinical and histological criteria. There are also differences in the T3 and T4 categories between UICC and AJCC. None of the classifications provide prognostic information such as the expected rate of metastasis.

More evidence for classification exists for histologically measurable vertical tumor thickness. A better estimate of the risk of metastasis is possible with this variable. The metastasis rate is 3-6% SCC depending on the collective [\[19\]](#). A worsening of prognosis is observed in immunosuppressed patients after organ transplantation or after high-dose chemotherapy. Local recurrences are approximately 20 times more frequent in desmoplastic SCC than in common SCC. Local recurrences are considered a poor prognostic sign. It remains an open question whether the local recurrence itself contributes to this deterioration or represents a sign of the aggressive growth behavior of the tumor [\[19\]](#).

There are also differences in the N category between the UICC and AJCC classifications. Specifically, the AJCC divides the N2 category into three subgroups. In this approach, contralateral or bilateral metastasis results in upstaging. However, note that in the head and neck region, contralateral or bilateral lymphatic drainage is primary in 7% of cases. Micrometastasis, as found on sentinel lymph node biopsy, is considered only in the UICC classification (mi). No distinction is made between

intranodal versus capsular lymph node metastasis. Staging does not correspond to evidence-based studies.

Table 9: TNM classification of SCC of the skin for the labial skin (excluding lip vermilion), trunk, upper extremities and shoulders, lower extremities, and hip and scrotum (8th edition, 2017)

TNM classification	
T category	
TX	Primary tumor cannot be assessed
T0	No evidence of primary tumor
Tis	Carcinoma in situ
T1	Tumor 2 cm or less in greatest extension
T2	Tumor more than 2 cm but not more than 4 cm at its maximum dimension
T3	Tumor more than 4 cm at its maximal dimension or superficial bone invasion or perineural invasion or deep invasion*
T4a	Tumor with macroscopic bone invasion/ bone marrow invasion
T4b	Tumor with invasion of the axial skeleton including foramina and/or involvement of the vertebral foramen up to the epidural space
<p>*“deep invasion“ is defined as invasion beyond the subcutaneous fat or >6 mm (measured from the stratum granulosum of the adjacent epidermis to the base of the tumor).</p> <p>Perineural invasion as a criterion for T3 is defined as clinical or radiologic involvement of nameable nerves without involvement of the foramina or skull base.</p> <p>In the case of multiple simultaneous tumors, the tumor with the highest T category is classified and the number of delineable tumors is indicated in parentheses, e.g. T2(5).</p>	
N category	
NX	Regional lymph nodes cannot be assessed
N0	No regional lymph node metastases
N1	Metastasis(s) in a regional lymph node, 3 cm or less at its maximum dimension
N2	Metastasis(s) in one lymph node, more than 3 cm but not more than 6 cm at its maximum dimension or in multiple lymph nodes, none more than 6 cm at its maximum dimension

TNM classification			
N3	Metastasis(s) in one lymph node more than 6 cm at its maximum dimension		
M category			
M0	No distant metastases		
M1	Distant metastases		
Stage classification			
Stage 0	Tis	N0	M0
Stage I	T1	N0	M0
Stage II	T2	N0	M0
Stage III	T3	N0	M0
	T1, T2, T3	N1	M0
Stage IV	T1, T2, T3	N2, N3	M0
	T4	Any N	M0
	Any T	Any N	M1

Table 10: TNM classification of SCC of the head and neck according to AJCC / UICC (8th edition, 2017)

TNM classification	
T category	
TX	Primary tumor cannot be assessed
T0	No evidence of primary tumor
Tis	Carcinoma in situ
T1	Tumor 2 cm or less in greatest extension
T2	Tumor more than 2 cm but not more than 4 cm at its maximum dimension
T3	Tumor more than 4 cm at its maximum dimension or superficial bone invasion or perineural invasion or deep invasion**
T4a	Tumor with macroscopic bone invasion/ bone marrow invasion
T4b	Tumor with invasion of the axial skeleton including foramina and/or involvement of the vertebral foramen up to the epidural space
<p>**“deep invasion“ is defined as invasion beyond the subcutaneous fat or >6 mm (measured from the stratum granulosum of the adjacent epidermis to the base of the tumor)</p> <p>Perineural invasion as a criterion for T3 is defined as clinical or radiologic involvement of named nerves without involvement of the foramina or skull base.</p>	
N category (clinical)	
N0	No regional lymph node metastases
N1	Metastasis(s) in a regional lymph node, 3 cm or less at its maximum dimension
N2	Metastasis(s) as described below:
N2a	Metastasis(s) in solitary ipsilateral lymph node, more than 3 cm but not more than 6 cm at its maximum dimension, without extranodal spread
N2b	Metastases in multiple ipsilateral lymph nodes, none more than 6 cm at its maximum dimension, without extranodal spread
N2c	Metastases in bilateral or contralateral lymph nodes, none more than 6 cm at its maximum dimension, without extranodal spread

TNM classification	
N3a	Metastasis(s) in one lymph node, more than 6 cm at its maximum dimension, without extranodal spread
N3b	Metastasis(s) in a single or multiple lymph nodes, clinically in extranodal spread***
***The presence of skin or soft tissue involvement (invasion) or clinical signs of nerve involvement is considered clinical extranodal spread.	
N category (pathological)	
pN0	No regional lymph node metastases
pN1	Metastasis(s) in solitary ipsilateral lymph node, 3 cm or less at its maximum dimension, without extranodal spread
pN2	Metastasis(es) as described below:
pN2a	Metastasis(s) in solitary ipsilateral lymph node, 3 cm or less at its maximum dimension, with extranodal spread or more than 3 cm but not more than 6 cm at its maximum dimension, without extranodal spread
pN2b	Metastases in multiple ipsilateral lymph nodes, none more than 6 cm at its maximum dimension, without extranodal spread
pN2c	Metastases in bilateral or contralateral lymph nodes, none more than 6 cm at its maximum dimension, without extranodal spread
pN3a	Metastasis(s) in one lymph node, more than 6 cm in greatest extent, without extranodal spread
pN3b	Metastasis(s) in one lymph node more than 3 cm at its maximum dimension with extranodal spread or in multiple ipsilateral, contralateral or bilateral lymph nodes with extranodal spread
M category	
M0	No distant metastases
M1	Distant metastases
The pT categories correspond to the T categories. pM1 means that distant metastases were confirmed microscopically.	

TNM classification			
Stage classification			
Stage 0	Tis	N0	M0
Stage I	T1	N0	M0
Stage II	T2	N0	M0
Stage III	T3	N0	M0
	T1, T2, T3	N1	M0
Stage IV	T1, T2, T3	N2, N3	M0
	T4	Any N	M0
	Any T	Any N	M1

4.5 Field cancerization

4.10	Consensus-based statement	checked 2022
EC	There is no generally accepted definition of field cancerization. Field cancerization includes an area of skin with multiple actinic keratoses surrounded by visible UV-related skin damage.	
	Strong consensus	

The concept of field cancerization was first established in 1953 by Slaughter et al. based on the histological evaluation of oral SCC and its environment [66]. It was shown that additional tumors often subsequently appeared in the initially clinically asymptomatic tumor environment. This was attributed to the pre-existing field-like spread of the tumors, which, however, initially remains subclinical. Meanwhile, the term field cancerization is attributed to genetic causes and used in the context of a variety of different tumor entities: head and neck, lung, vulvar, esophageal, cervical, breast, colon, bladder and skin tumors [67].

It is generally accepted that the environment of AK may also represent a "cancer field" and the term field cancerization is also used extensively in this regard [68]. A classification of the environment of AK as a "cancer field" has special significance for therapy: if subclinical changes are also present in the environment in addition to clinically visible AK, these would consequently have to be treated as well against the background of a possible clinical recurrence or tumor progression in the

environment. In this context, therapy also distinguishes between lesional therapy ("lesion-directed") and field-directed therapy ("field-directed"). Thus, if a tumor field can be characterized in the vicinity of AK, this will have an impact on the selection of the therapeutic procedure (see [Chapter 5.3](#)) [69].

However, there is as yet no explicit definition that takes into account different aspects of field cancerization (genetic, immunological, molecular biological, histological and clinical characteristics).

On the genetic level, p53 mutations, for example, have been detected in the neighborhood of AK which are also characteristic for AK itself [70]. A variety of other immunological and molecular biological findings typical of AK are also detectable in the surrounding tissue, including increased COX2 expression, disturbances in the BRAF signaling pathway, and the highly variable expression of many individual genes [71], [72], [73]. Histologically, AK are characterized by atypical keratinocytes that are significantly more densely packed than in healthy skin. This phenomenon, referred to as "crowding" ([Chapter 4.1](#)), is also observed histologically in clinically healthy surrounding skin [74]. Confocal laser scanning microscopy or high resolution optical coherence tomography are now able to visualize this structural atypia in the epidermis of the surrounding field in a non-invasive approach [68].

Genetic, immunological, molecular biological and histological findings as well as confocal laser scanning microscopy and high-resolution optical coherence tomography can thus help to characterize the tumor field. However, to date an explicit clinical definition has been lacking. Nevertheless, it is precisely the clinical definition of field cancerization in AK that would be of particular importance in clinical practice for the selection of the therapeutic procedure. Erlendsson et al. based the definition of field cancers in AK on clinical characteristics: field cancerization is rated as mild, moderate or severe based on the extent to which the surrounding skin shows mottled erythema ("mottled erythema"), pigmentation, telangiectasia, pallor, laxity and dry texture without evidence of AK itself. However, this definition has not yet been substantiated by clinical studies [75]. In a review of the definition of field cancerization in AK, it was emphasized that a unified clinical definition is still lacking. In this regard, a retrospective review highlighted telangiectasia, atrophy and pigmentary abnormalities as reliable or very reliable indicators of field cancerization in AK. An emery paper-like surface of the skin was considered to have moderate reliability for defining the field. In summary, as an expert opinion, field cancers in AK were defined as follows in this work:

"Field cancerization is defined clinically as an anatomic area with AK or adjacent to it and with visible sun-related skin damage characterized by at least two of the following signs: telangiectasia, atrophy, pigmentary abnormalities and sandpaper-like surface. It remains unclear whether visible AK is a prerequisite for field cancerization" [76].

In this regard, for patients with these features and AK, field-directed therapy or field-directed therapy in combination with lesion-directed therapy is recommended. In case of clinical signs of field cancerization and absence of AK in the field, it is recommended to take educational or preventive measures and to arrange field monitoring by the patients themselves [76].

In conclusion, there is no clinically validated definition of field cancerization in AK. Genetic, immunological, molecular biological, and histological findings are

impractical for therapy selection in the specific clinical situation and thus are more appropriate for scientific characterization of the field. Confocal laser microscopy or high-resolution optical coherence tomography can noninvasively visualize atypical keratinocyte clusters but has not been sufficiently widely used in treatment settings.

Thus, attempting a clinical definition, even in the absence of validation, seems reasonable and important for therapy selection in AK in clinical practice. In this regard, the clinical definition proposed in the work of Figueras Nart et al., based on clinical signs of UV damage, represents a feasible approach [76].

4.6 Importance of non-invasive diagnostic procedures

4.11	Consensus-based statement	checked 2022
EC	Diagnosis is made by clinical examination and inspection.	
	Strong consensus	

4.12	Consensus-based recommendation	checked 2022
EC	Dermatoscopy, confocal laser microscopy and optical coherence tomography can be used to diagnose actinic keratosis and squamous cell carcinoma of the skin when findings are clinically unclear.	
	Strong consensus	

Inspection and palpation are suitable to make a tentative diagnosis of AK. AK is characterized by a variable erythema with a variably pronounced keratosis. The clinical grading of AK does not correlate with the histological expression [77]. However, invasiveness cannot be assessed reliably by inspection and palpation [78].

Dermatoscopy is a suitable method to differentiate other diseases and tumors in case of unclear findings. Numerous studies have demonstrated that AK, pigmented AK, Bowen's disease and SCC show typical patterns, especially of the vessels, with dermatoscopy [79]. AK and SCC can thus be well differentiated from basal cell carcinoma. Dermatoscopy is also suitable for differential diagnosis between lentigo maligna, lentigo senilis and pigmented AK [80]. In addition, the degree of invasiveness correlates with vascular atypia, so dermatoscopy can also be used to assess invasiveness [81], [82]. In one study, the sensitivity of dermoscopy in the diagnosis of AK was 98.7% compared with histology as the gold standard, and the specificity was 95% [79]. In pigmented lesions, both values are lower [83].

Other non-invasive imaging modalities include confocal laser microscopy and optical coherence tomography. There are numerous studies and an S1 guideline on the value of confocal laser microscopy for non-invasive diagnosis of AK [84]. It allows the diagnosis of subclinical AK and helps characterize a cancerized field. In confocal laser microscopy, light-damaged but clinically unaffected skin in a field cancerization

often shows an atypical honeycomb pattern as a sign of subclinical AK, which returns to normal with topical therapy [85], [86], [87], [88], [89].

Likewise, optical coherence tomography is useful for diagnosing AK and SCC and for differentiating basal cell carcinoma. It shows a widened, irregular stratum corneum and an acanthotic epidermis in AK. In SCC, by definition, the basal membrane zone, which is still detectable in AK, is broken [90], [91]. AK can be distinguished from basal cell carcinoma morphologically and by objective parameters such as epidermis thickness and signal intensity of the dermis [92]. Optical coherence tomography also allows diagnosis of multiple lesions in field cancerization. The measurement times for optical coherence tomography are so short that diagnosis of multiple lesions is possible within a short time. With confocal laser microscopy, this is also possible with the aid of a flexible handpiece. Numerous studies have used confocal laser microscopy and optical coherence tomography to visualize and quantify therapeutic effects in the topical treatment of AK [93], [85], [86], [94], [95], [87], [96]. The sensitivity of optical coherence tomography in detecting AK was 88%-93% depending on the investigator. Clinically manifest AK was detected in another study with a sensitivity of 100% (95% CI 88-100%). This value was 73% (95% CI 52-87%) for subclinical lesions [94]. A systematic review of the diagnostic performance of confocal laser microscopy reported a sensitivity of 91%-100% for AK and 100% for SCC [97]. Similar results were observed in another study, with epidermal pleomorphism in the stratum spinosum and granulosum showing the highest sensitivity and specificity for the diagnosis of AK [98].

4.7 When and how to obtain a histology specimen

4.13	Consensus-based statement	checked 2022
EC	Actinic keratosis does not require histological diagnosis if typical clinical findings are present.	
	Strong consensus	

4.14	Consensus-based recommendation	checked 2022
EC	In case of resistance to therapy and clinically unclear findings, a tissue sample shall be obtained.	
	Strong consensus	

4.15	Consensus-based recommendation	modified 2022
EC	If squamous cell carcinoma of the skin, cheilitis actinica or Bowen's disease is clinically suspected, histology shall also be performed to differentiate other benign or malignant neoplasia. Preoperatively, the maximum diameter of the neoplasia should be documented for squamous cell carcinoma of the skin and Bowen's disease.	
	Consensus	

4.16	Consensus-based statement	checked 2022
EC	Depending on the clinical situation, punch biopsies, shave excisions, or excisional biopsies are appropriate.	
	Consensus	

4.17	Consensus-based recommendation	checked 2022
EC	If the clinical picture is clear for squamous cell carcinoma of the skin, complete resection can be carried out without prior biopsy.	
	Consensus	

AK do not require histological diagnosis if typical clinical findings are present. Lesions that are clinically equivocal, have evidence of progression to SCC or whose biological behavior cannot be assessed should be biopsied. Histological diagnosis should also be carried out for AK that do not respond to adequate therapy.

Obtaining histology sample is required if SCC is clinically suspected. Depending on tumor size and therapeutic approach, a punch, incision or shave biopsy may be done or, alternatively, the tumor may be excised [99]. The clinical presentation of SCC of the skin can be diverse and most commonly resembles that of a hyperkeratotic plaque, a flat ulcer with a marginal mound or a keratotic nodule or nodule with or without ulceration. SCC may develop de novo or from AK precursor changes such as reddened or hyperkeratotic macules and plaques, AK or leukoplakia. Since the clinical appearance is variable and clinical-morphological overlaps with diverse entities are present, a differentiation between an early invasive SCC with breakthrough of the basal membrane of the skin and a hyperkeratotic AK is also not possible based on clinical picture alone; a histological examination should be initiated before therapy is started, especially to differentiate another benign or malignant neoplasia of the skin as well. If the overall clinical context is clear, primary therapy as in the presence of SCC is justifiable.

Although keratoacanthoma can usually be differentiated clinically from SCC of the skin because of its rapid growth progression and hemispherical growth form, neither

clinical nor histological differentiation is certain. In this case, histologic examination and primary therapy should be carried out as in the presence of SCC. This is especially true for patient groups with an increased risk of metastasis.

AK and SCC that are potentially caused by occupational natural UV exposure and thus potentially fulfill the facts of an occupational disease 5103 according to the Occupational Diseases Ordinance represent a special consideration [Chapter 10](#). In these cases diagnosis must meet the requirements for reporting a BK 5103: in the case of a SCC, the diagnosis is proven only by appropriate histological examination. In the case of multiple AK or field cancerization, histological confirmation is not required according to scientific justification, but is recommended at least for one of the AK present [\[100\]](#).

The value of cytological techniques has been investigated in several studies. Bilen et al. obtained cytological specimens in tumors suspected of malignancy on the head. False negative results were found in 1/19 cases and no false positive findings were detected. Limitations are presented by flat or ulcerated seborrheic keratoses, which can be confused with SCC and basal cell carcinoma. The authors further noted that the cytology of premalignant lesions bears strong resemblance to SCC and that obtaining meaningful cytology is often unsuccessful in crusted, hyperkeratotic, and hard lesions [\[101\]](#). In another study of 50 basal cell carcinomas and 28 AK, the sensitivity of cytology for AK was 91% (Papanicolaou stain) and 83% (May-Grünwald-Giemsa stain), respectively. AK could be discriminated from basal cell carcinomas, but cytology does not reliably differentiate AK or carcinomata in situ from invasive SCC [\[102\]](#).

Vega-Memije et al. studied 30 SCC and found a high concordance of cytology with histological diagnosis and concluded that reliable diagnosis is possible by cytology, although cytology is not suitable to identify tumor subtypes or to determine aggressive tumor characteristics [\[103\]](#). Currently, the value of cytodiagnosis of AK and SCC has not been sufficiently investigated and further studies are needed.

4.8 Parameters of a histological report

4.18	Consensus-based recommendation	checked 2022
EC	<p>The following histomorphological variants should be designated when present:</p> <ul style="list-style-type: none"> • atrophic • hypertrophic • acantholytic • pigmented • lichenoid • bowenoid <p>actinic keratosis.</p>	
	Strong consensus	

4.19	Consensus-based recommendation	checked 2022
EC	<p>The histology report for squamous cell carcinoma of the skin shall include the following in addition to the diagnosis:</p> <ul style="list-style-type: none"> • Histological tumor type (for specific subtypes of squamous cell carcinoma of the skin) • Description of the histological depth extension in relation to the anatomical stratification (especially from level V, corresponding to infiltration of the subcutis) • Measurement of the depth extension from an invasion depth of 2 mm (corresponds approximately to the diameter of a 10x field of view) • If present, indication of the presence of perineural involvement, vascular invasion or poor differentiation • Completeness of resection of the invasive tumor portion 	
	Strong consensus	

In addition to the indication of histomorphological variants in the presence of AK or SCC, the components of the histology report of findings essentially result from the risk factors for recurrence and distant metastasis ([Chapter 3.4](#)).

4.9 Diagnosis of spread in invasive squamous cell carcinoma

4.20	Consensus-based recommendation	checked 2022
EC	If the presence of squamous cell carcinoma of the skin is suspected, the initial examination shall include inspection of the entire skin.	
	Strong Consensus	

There are virtually no robust prospective studies or observational studies on the diagnosis of spread. Most studies on the value of imaging techniques come from investigations from SCC of the head and neck region (head and neck squamous cell carcinoma, HNSCC).

4.9.1 Lymph node sonography

4.21	Consensus-based recommendation	checked 2022
EC	Locoregional lymph node sonography shall be carried out when locoregional metastases are suspected. Locoregional lymph node sonography should be carried out when risk factors are present.	
	Consensus	

Metastases of cutaneous SCC occur locoregionally as satellite, in-transit or locoregional lymph node metastases in approximately 80% of cases; locoregional filiae detected early have the option of R0 resection. Therefore, early detection of locoregional lymph node filiae is of particular importance. In a meta-analysis of 74 studies of melanoma, cost-effective lymph node ultrasonography was found to have the highest sensitivity and specificity (staging 60% and 97%, respectively, follow-up 96% and 99%) and the highest positive predictive value of 83% to 98% (risk-dependent) for detecting locoregional lymph node filiae [\[104\]](#).

Lymph node ultrasonography is also described as the most effective procedure in the diagnosis of HNSCC to detect locoregional lymph node metastases, showing a sensitivity of approximately 78% and specificity of 85% [\[105\]](#), [\[106\]](#). It is clearly superior to clinical examination by palpation [\[107\]](#). In case of sonographic suspicion of the presence of parotid and cervical metastases, the staging examination should be supplemented by fine needle cytology of the suspicious lymph nodes, a CT scan of the neck and thorax, and an MRI of the parotid gland [\[105\]](#). In a meta-analysis comparing different imaging modalities (ultrasound, CT, MRI, PET) in the diagnosis of lymph nodes in clinically nodal-negative HNSCC, the positive predictive value for lymph node ultrasonography was 25% to 56% and the negative predictive value was 95% to 84% and was equivalent to the other modalities in accuracy [\[108\]](#). Also, when compared with FDG PET/CT and software-based fusion PET/MRI, lymph node ultrasonography was found to be at least equivalent in detecting occult lymph node

metastases from HNSCC tumors, although published PET data often refer to studies with inhomogeneous collectives (N-/N+) with varying levels of evidence [105], [109]. Since cutaneous SCC of the neck and head also shows lymph node metastases at the same site, and studies of HNSCC frequently include cutaneous SCC, these observations can be applied to cutaneous SCC of the neck and head.

Although the accuracy of imaging techniques has steadily improved over the past decades, there remains limited sensitivity with respect to the detection of micrometastases with all methods. Moreover, lymph node ultrasonography is currently not available close to home in all regions.

4.9.2 Chest X-ray

4.22	Consensus-based recommendation	checked 2022
EC	Chest X-ray shall not be carried out as a standard of care when locoregional or distant metastasis of squamous cell carcinoma of the skin is suspected or demonstrated.	
	Consensus	

X-ray chest examinations are clearly inferior to chest CT in detecting small pulmonary filiae [110], [111]. X-ray thoracic examinations detect only 28-60% of pulmonary metastases diagnosed on CT thorax. One problem with chest X-ray examinations is the high number of false positive and false negative findings.

4.9.3 Abdominal sonography

4.23	Consensus-based recommendation	checked 2022
EC	Abdominal ultrasonography shall not be carried out as a standard of care when locoregional or distant metastasis of squamous cell carcinoma of the skin is suspected or demonstrated.	
	Strong consensus	

Abdominal ultrasonography can be used to detect parenchymal distant metastases and abdominal lymph node metastases; however, diagnostic accuracy is examiner- and patient-dependent and overall lower than that of MRI, CT, and PET/CT [112]. Limitations arise particularly in the diagnosis of deep-seated structures (e.g., retroperitoneal lymph nodes) and in obese patients. An advantage of abdominal ultrasonography is its easy practicability, wide availability, and lack of radiation exposure.

4.9.4 Cross-sectional imaging

4.24	Consensus-based Recommendation	checked 2022
EC	If metastasis is suspected, cross-sectional imaging shall be carried out.	
	Strong Consensus	

There have been no studies on the regular use of cross-sectional imaging in the diagnosis of spread in cutaneous SCC; therefore its use is reserved for the clarification of metastasis-sensitive findings; i.e. if clinical examination or lymph node sonography shows a suspicion of metastasis, cross-sectional imaging should be carried out. For cutaneous SCC, the NCCN guidelines recommend further cross-sectional imaging in patients at increased risk for metastasis such as presence of clinically positive lymph nodes, advanced local disease or perineural spread on histology, and in patients under immunosuppression. A retrospective study examining the impact of radiological staging on disease progression in cutaneous SCC in 108 patients showed that high-risk SCC (T2b, T3) who received multiple staging examinations (79% CT, 21% PET/CT, 19% MRI) during a median follow-up of 43 months had improved disease-free survival ($p=0.028$). No difference was seen in terms of distant metastasis-free or disease-specific survival [113].

Regarding the diagnosis of cervical lymph node metastases, CT, MRI and ultrasound show comparable accuracies. A meta-analysis comparing different imaging modalities (ultrasound, CT, MRI, PET) in the diagnosis of lymph node in nodal-negative HNSCC showed similar results in terms of pooled sensitivity and specificity. In advanced SCC, cross-sectional imaging should be carried out to exclude distant metastases [108]. In addition to high diagnostic accuracy, CT offers the advantages of standardized whole-body examination, general availability and patient- and examiner-independence compared with sonography. Functional imaging using FDG-PET/CT can detect distant metastases of a SCC in particular with high sensitivity and specificity due to their significantly increased glucose metabolism [114], [115], [116], [117]. Several studies in HNSCC have shown that PET/CT in addition to conventional work-up increases staging accuracy, improves specificity of LK diagnosis, and detects more distant metastases than CT alone [118], [115]. However, micrometastases in lymph node in clinically N0 patients remain a diagnostic problem even for PET/CT. In an analysis by Fujiwara et al. in 26 patients with high-risk cutaneous SCC, PET/CT showed high sensitivity (100%) and specificity (81%) in the detection of metastases, significantly higher than conventional CT with a sensitivity of 51% and specificity of 69% [119]. In 16% of patients, a false positive finding was seen, which was predominantly due to a strong inflammatory peritumoral infiltrate with mononuclear cells. However, this showed a significantly higher standardized uptake value (SUV) of the lymph node metastases compared with FDG uptake of the surrounding inflammatory infiltrate. These results were confirmed by another monocentric study of 23 patients, which showed a sensitivity of 100%, a positive-predictive value and an accuracy of 77.5% each for 18F-FDG-PET in initial staging. This examination was considered to have an important role not only in the detection of small soft tissue and lymph node metastases, but also in primary staging [120]. Another recent study by the same group of authors investigated the value of FDG-PET/CT for recurrence staging in 100 patients with cutaneous SCC. The study confirmed the superior sensitivity of the

method, especially in the detection of small cutaneous/subcutaneous foci and lymph nodes, and was able to demonstrate PET/CT induced management change in 28% of patients [\[121\]](#).

5 Therapy of actinic keratosis

M. Heppt, C. Berking, T. Diepgen, K. Fritz, C. Löser, C. Salavastru, L. Schmitz, T. Steeb, E. Stockfleth, R.-M. Szeimies, C. Ulrich

5.1 Literature search and study selection

Only prospective, randomized controlled trials (RCTs) or systematic reviews and meta-analyses of RCTs that reported at least one of the predefined critical effectiveness endpoints were included as the basis for the evidence-based recommendations and statements. These included:

- Complete response (defined as healing of all lesions per patient or randomized treatment field, operationalized where appropriate by scores such as the "target lesion number score" (TLNS) or the "cumulative lesion number score" (CLNS) of 0 each),
- Partial response (defined as healing of more than 75% of lesions per patient or randomized treatment field),
- Mean lesion reduction per patient or randomized treatment field (expressed in absolute numbers or percentages),
- Improvement in "Investigator Global Improvement Index" (IGII); and
- Improvement in "Participant Global Improvement Index" (PGII) following a Cochrane review with meta-analysis [122] and the ILDS/EDF guideline published in 2015 [123].

Studies that reported purely lesion-related effectiveness endpoints without evidence of prior randomization were not included. The minimum study population size was $n=10$ regardless of study design (interindividual, intraindividual, cross-over design). Sequential therapy combinations were considered using systematic review articles or meta-analyses in the form of aggregated evidence. The types of interventions and observation time points were not restricted.

The literature search is described in the Methods Report of the Guideline. Subsequently, the included interventions were ranked and qualitatively compared.

The following subgroups were examined, following the ILDS/EDF Guideline published in 2015:

- Patients with single AK (1-5 lesions per region or treatment area studied),
- Patients with multiple AK (≥ 6 lesions per examined region or treatment field),
- Patients with field cancerization (≥ 6 lesions per examined region or treatment field and evidence of actinically damaged skin with hyperkeratosis in a contiguous treatment area),
- Patients in any of the previous categories with immunosuppression. The recommendations for the last subgroup are dealt with in a separate chapter (see [Chapter 5.8](#)).

5.2 Treatment indication and natural course of the disease

5.1	Consensus-based recommendation	checked 2022
EC	The indication for treatment of actinic keratosis should be taking into consideration the clinical presentation, risk factors (e.g., immunosuppression, cumulative UV exposure, number of lesions), comorbidities, life expectancy and patient wishes.	
	Consensus	

The probability of progression or regression of AK without therapy has been the subject of intense debate for years. Accurate investigation of these metrics is hampered among other factors by the need for long follow-up of at least 6-12 months, limited transferability of results and strong heterogeneity of the populations studied or intervening therapies that affect the natural course of the disease. Therefore, few cohorts exist in which natural course without intervention has been studied. Accordingly, the values reported in the literature for progression of AK to invasive SCC vary widely and have been quantified from 0.03% to 20% per lesion per year [36], [124], [125]. In contrast, spontaneous remission rates of 15% to 63% are sometimes very high, so that the question inevitably arises whether every AK should also be treated or whether waiting without therapy is also justifiable in a low-risk situation [44]. Furthermore, for many interventions there is a lack of clear evidence that treatment of AK prevents the development of SCC in addition to lesion healing.

At the same time, there are observations that approximately 60% of invasive SCC originate from one AK [124]. If there is a field affected by multiple AK with evidence of field cancerization, there is evidence of a lower rate of spontaneous regression than without field cancerization [44]. Recent studies on the pathogenesis of AK also suggest that transformation is possible even from early, i.e., clinically and histologically discrete lesions, and does not necessarily occur in a stepwise fashion via moderate and eventually hyperkeratotic AK [34]. These findings make it difficult to assess which lesions are at high risk of developing into invasive SCC and which are not. Although the characteristics vary, as described above, there are at-risk populations and risk factors in which progression rates are likely to be significantly higher [44]. These include patients with immunosuppression, a history of light skin cancer, and cumulative UV exposure. The number of lesions present is also an important indicator of individual risk of developing invasive SCC. Basal proliferation behavior and resistance to therapy also appear to be unfavorable lesion-related factors [77], [61], [62], [126]. Against this background, an observational wait-and-see approach without therapy should be viewed critically. Due to the risk of progression to SCC and lack of clear parameters to identify lesions with high potential for progression, adequate therapy of AK should be carried out. Ultimately, life expectancy, comorbidities, and patient wishes also determine the general indication for therapy.

5.3 Therapy basics

A large number of therapeutic options exist for the treatment of AK, which makes selection in everyday clinical practice difficult. A direct comparison of individual interventions is often possible only to a limited extent, since many therapy modalities have not been directly compared in studies. An estimation of effects in the absence of direct comparative studies is possible via network meta-analyses; however, these often examine only one endpoint (e.g. complete patient-related response [127]) in isolation, so that important information may be lost, and they are thus insufficient for a concrete therapy decision in everyday clinical practice, as information on tolerability or cosmetic outcome is missing [128], [127], [129].

The choice of an appropriate treatment depends on patient-, lesion- and therapy-specific factors [69]. Patient factors include, for example, age, comorbidities, immunosuppression, comedication, patient wishes and preferences, and treatment adherence. Lesion-related aspects subsume the number of AK, their localization (capillitium, face, extremities, trunk), clinical nature (grading according to Olsen, hyperkeratotic lesions), and the size of the affected field. In clinical practice, the boundary between multiple AK and field cancerization is not always clearly and unambiguously possible, which is further complicated by a lack of a generally accepted definition of field cancerization (see [Chapter 4.5](#)).

Also in our literature search, it remains unclear in some of the included and investigated study populations whether only multiple AK or additionally field cancers were present, so that a clear assignment of interventions to these subgroups was not always possible and the transitions here are fluid. Furthermore, lesion-directed therapeutic approaches are not necessarily applicable only to single lesions, or field-directed ones not only in the presence of multiple lesions or field cancerization. The terms "field-directed" and "lesion-directed" refer rather to the type of intervention, whereas the number of AK represent lesion-related factors.

Table 11: Factors to consider when making treatment decisions for AK*

Patient-related factors	Lesion-related factors	Therapy-related factors
Age	Number of lesions	Lesion-directed or field-directed therapy approach
Desire for therapy	Size of the affected area	therapy modality (interventional, surgical, topical-medicinal)
Comorbidities	Localization (capillitium, face, trunk, extremities)	Duration of therapy
Individual risk and clinical risk factors (immunosuppression, organ transplantation, comedications)	Clinical condition and limitation	Efficacy
Adherence / Compliance	Field cancerization	Side effects and tolerability
Social environment and resources	Treatment resistance	Self-administration or administration by others
Ability to self-administer correctly	Histological risk factors (e.g., basal proliferation pattern, proliferating AK, bowenoid AK, follicular epithelium affected)	Level and reimbursability of therapy costs
		Access to therapy
*Table based on [69]		

The advantage of field-directed methods is that subclinical changes and not only clinically manifest AK can be treated. This is especially useful in light of the fact that the presence of AK is increasingly perceived as a chronic progressive disease and is strongly associated with the individual risk of developing further AK and invasive cutaneous SCC. When carrying out field-directed therapy, a maximum application area must be observed for each of most topical drug substances [\[130\]](#). This contrasts with the often simpler and effective implementation of primarily lesion-directed therapeutic procedures, which are useful for a few, isolated and well-demarcated lesions.

Table 12: Lesion-directed and field-directed therapy methods in AK

Primarily lesion directed methods	Primary field directed procedures
Kyrosurgery	Chemoexfoliation
Potassium hydroxide 5% solution	Dermabrasion
Surgical procedures	Photodynamic therapy
Photodynamic therapy (Patch-PDT)	Topical drug-based procedures* <ul style="list-style-type: none"> • Diclofenac sodium 3% gel • 5-fluorouracil 5% cream • 5-fluorouracil 4% cream • 5-fluorouracil 0.5% with salicylic acid 10% solution • Imiquimod 5% cream • Imiquimod 3.75% cream • Tirbanibulin 1% ointment
Topical-medicinal procedures (5-fluorouracil with salicylic acid 10% solution)	Laser procedures (ablative)
Laser procedures (ablative, non-ablative)	
*in alphabetical listing	

Therapy-specific factors continue to include the type of treatment (topical drug-based, interventional, surgical), therapy duration, efficacy, and side effects. Especially for self-administered and long-term therapies, good therapy adherence and the patient's ability to administer the therapy correctly is an important prerequisite for therapy success. In the case of limited therapy adherence, procedures with a short therapy duration are therefore more suitable.

Table 13: Therapy duration of interventions for AK

Short (<1 week)	Medium (1-6 weeks)	Long (≥6 weeks)
Cryosurgery	5-fluorouracil 5% cream	Diclofenac sodium 3% gel
Surgical procedures	5-fluorouracil 4% cream	5-fluorouracil 0.5% with salicylic acid 10% solution
Chemoexfoliation	Imiquimod 5% cream	Potassium hydroxide 5% solution
Dermabrasio	Imiquimod 3.75% cream	
Laser procedure	Potassium hydroxide 5% solution	
Photodynamic therapy		
Tirbanibulin 1% ointment		

5.4 Combination therapies

5.2	Evidence-based recommendation	modified 2022
GoR B	Primary or sequential combination therapy of various field- or lesion-targeted procedures should be offered for actinic keratosis.	
LoE 1	[131], [132], [133], [134] 1: De novo research	
	Strong consensus	

A variety of interventions for the treatment of AK exist and are often combined in clinical practice. The rationale is that by combining different interventions, the advantages of the respective individual procedures can be utilized and potential synergistic effects can be created through different mechanisms of action. From clinical experience, combination therapies consisting of a field-directed and an ablative procedure are well tolerated. In particular, lesion-directed pretreatment of thick, hyperkeratotic AK with an ablative procedure can be combined with subsequent field-directed therapy to combine both effective and rapid treatment of clinically manifest lesions with therapy of subclinical changes. Conversely, even after primary field-directed therapy, residual AK can be effectively retreated with a lesion-directed modality.

The value of combination therapies has been investigated in several systematic reviews and meta-analyses [131], [132], [133]. One meta-analysis examined the use of an ablative laser as a pretreatment to PDT [134]. Laser-assisted PDT showed significantly higher clearance rates than PDT monotherapy (relative risk 1.33; 95% CI 1.24-1.42; $I^2=25\%$; $p<0.01$). There was no difference in pain intensity between laser-assisted PDT and the other procedures (mean difference 0.31; 95% CI -0.12 to 0.74; $I^2=0\%$). However, the studies included had a high risk of bias.

Another meta-analysis showed that cryosurgery in combination with a topical approach had significantly higher complete patient-related healing rates than monotherapy (relative risk 1.74, 95% CI 1.25-2.43; $I^2=73\%$). Furthermore, no difference in partial patient-related healing rates was identified for this combination (relative risk 1.64, 95% CI 0.88-3.03; $I^2=77\%$). The studies showed a high risk of selective reporting bias [131].

These papers are followed by another meta-analysis on the effectiveness of PDT in combination with a topical intervention compared with monotherapy [132]. A total of 10 RCTs were included with a total sample size of $n=277$. Four studies examined a combination of PDT with imiquimod cream, three with 5-FU, and one each with ingenol mebutate (IMB), tazarotene gel, and calcipotriol ointment. Patients treated with combination had higher rates of complete (relative risk 1.63; 95% CI 1.15-2.33; $p=0.007$) and partial healing (relative risk 1.19; 95% CI 0.84-1.67; $p=0.33$). Similarly, lesion-specific healing rates were higher for PDT combined with topical intervention compared to monotherapy (relative risk 1.48; 95% CI 1.04-2.11; $p=0.03$). A subgroup analysis was performed for PDT combined with imiquimod and identified a higher rate of participants with complete lesion healing than with monotherapy (relative risk 1.57; 95% CI 1.09-2.25; $p=0.02$).

Peels can also be used in the treatment of AK and can be combined [133]. Another meta-analysis showed that trichloroacetic acid (TCA) in combination with Jessner's solution had a significantly lower complete patient-related healing rate (relative risk 0.36; 95% CI 0.14-0.90; $I^2=0\%$; $p=0.03$) and lesion-related healing rate (relative risk 0.92; 95% CI 0.85-0.99; $p=0.03$) compared to 5-FU 5% cream. Furthermore, a synthesis within this work showed that the combination of 5-FU plus glycolic acid cleared 92% of lesions. However, these were all single-arm studies with no control group [133].

These evidence-based papers demonstrate the superiority of combination therapies; nevertheless, a combination of interventions should always be made in consultation with the patient after prior education about the respective advantages and disadvantages.

5.5 Ablative and physical procedures

5.5.1 Cryosurgery

5.3	Evidence-based recommendation	modified 2022
GoR B	Cryosurgery should be offered for single or multiple actinic keratoses.	
LoE 2	[129] , [122] , [127] , [135] , [136] , [137] , [138] , [139] , [140] 2: De novo research	
	Strong consensus	

Cryosurgery is a destructive procedure for local tissue destruction through the targeted application of cold. Because temperatures below -25°C are reached in the tissue, it is referred to as "cryosurgery", while "cryotherapy" works with temperatures just below the freezing point to achieve healing effects. It is carried out either by the open spray method or by the contact method using a cryopunch or a special cryoprobe. Liquid nitrogen (-196°C) is considered the cold source of choice. The practical execution of cryosurgery is not well standardized. It usually involves one to two freeze-thaw cycles in which the target lesions are exposed to cold for 15-60 seconds until a whitish ripening or drawing is visible. Intra- and extracellular ice crystal formation irreversibly destroys cell organelles and cell membrane. The mechanism of action is therefore effective but non-specific and extends to other cell types such as melanocytes. A single, continuous application of liquid nitrogen for 20-40 seconds contradicts physical principles that imply an increase in thermal diffusivity and thus higher efficacy when icing occurs twice in short succession with an intervening thaw. Therefore, a single application may explain poorer results for cryosurgery in some studies [\[136\]](#). Cryosurgery repeated several times, if necessary, with moderate spray times around 5 seconds with a single repetition after the first thawing within a cycle should be considered an important therapeutic option at least for isolated or refractory lesions with the fact of controlled performance by the physician. The latter is advantageous at least in patients with questionable or definitely limited ability to participate.

The advantage of cryosurgery is above all a relatively simple and quick application, mostly without the need for local anesthesia. Therefore, its practicality for both physician and patient is very good. Common side effects are pain, blistering, depigmentation, scarring or hemorrhage. For extensive findings, a combination of area treatment to reduce the number of lesions and simultaneously treat subclinical changes followed by targeted treatment of persistent lesions with cryosurgery is suggested as a possible strategy [\[135\]](#), [\[131\]](#). Examples of possible combinations would also be PDT followed by cryosurgery or surgical ablation under local anesthesia.

The widespread and long-standing use of cryosurgery in the treatment of AK is mainly based on clinical experience. In a literature search, 6 individual studies were

identified that investigated cryosurgery in a therapeutic arm. It largely served as a traditional, established, widely used and readily available therapeutic option as a standard against which other procedures such as MAL-PDT and laser ablation [140], [137], [139], or topical therapies such as imiquimod and 5-FU with or without salicylic acid, were measured [135], [136], [138]. In contrast, no studies comparing cryosurgery versus placebo were found. However, two systematic reviews and two network meta-analyses support the efficacy of cryosurgery, with complete healing rates of approximately 68% reported [141], [122], [127]. A network meta-analysis underlines the good efficacy especially for AK at extrafacial and extracranial sites relative to placebo and other interventions [129]. In contrast, no RCT was found that investigated cryosurgery in the immunosuppressed subgroup.

Table 14: Overview of the included single studies on cryosurgery

Study	Interventions	Single AK	Multiple AK	Field cancerization	Immuno-suppression
Zane 2014 [139]	Cryosurgery vs. ablation with CO ₂ laser	X			
Simon 2015 [138]	Cryosurgery vs. 5-FU 0.5% with SA 10% solution	X	X		
Krawtchenko 2007 [136]	Cryosurgery vs. 5-FU 5% cream vs. Imiquimod 5% cream	X	X		
Foley 2011 [135]	Cryosurgery vs. Imiquimod 5% cream		X		
Kaufmann 2008 [140]	Cryosurgery vs. MAL red light PDT	X	X		
Morton 2006 [137]	Cryosurgery vs. MAL-red light PDT	X	X		

Cryosurgery vs. 5-fluorouracil 0.5% with salicylic acid 10% solution

Population and study design: One randomized study compared 5-FU 0.5% with SA 10% solution with cryosurgery. Sixty-six patients with 4-10 hyperkeratotic lesions (grade II-III according to Olsen) on the face and hairless scalp were included. Individuals with iatrogenic immunosuppression were excluded [138].

Interventions: 5-FU 0.5% with SA 10% was applied as a solution lesion-directed once daily for a maximum of 6 weeks. If poorly tolerated, reduction to three times weekly administration was allowed. Cryosurgery was performed with liquid nitrogen as a spray procedure with a double freeze-thaw cycle, with the duration of icing left to the individual investigator. It could be repeated after 3 weeks, which was also at the discretion of the investigator. The study was unblinded. There was interindividual randomization to one of the two arms in a 1:1 ratio.

Results: The mean lesion reduction per patient at 14 weeks was 5.2 for 5-FU 0.5% with SA 10% and 5.7 for cryosurgery. In the first arm, 33.3% of patients showed complete and 51.5% partial (>75%) healing of all lesions after 98 days. For cryosurgery, these results were 25.0% (complete) and 62.5% (partial). Histological remission rates were lesion-related 62.1% for 5-FU 0.5% with SA 10% and 41.9% for cryosurgery. The recurrence rate (proportion of patients with at least one recurrence) 6 months after the end of therapy was higher for cryosurgery than for 5-FU 0.5% with SA 10% (84.8% vs. 39.4%). Overall response assessed by the investigator and patients was very similar in both arms. Similarly, the cosmetic outcome of both therapies was predominantly rated as "good" or "very good". Side effects tended to be observed more frequently with 5-FU 0.5% with SA 10% and included erythema, crusting and burning. Serious treatment-mediated events occurred in 24.2% of cases, compared with 6.1% with cryosurgery.

Assessment: In terms of mean lesion reduction and complete or partial healing of all lesions, the efficacy of both interventions was comparable with a slightly significant advantage of topical therapy in terms of complete response. Of note, there was a significant effect in the reduction of recurrences of initially healed lesions of 5-FU 0.5% with SA 10%, which may indicate a better long-term efficacy of this agent compared to cryosurgery. This was in contrast to a lower rate and side effects with cryosurgery, which should be considered in the harm-benefit assessment of this comparison. Because of the open-label study design without blinding and a small number of participants, the work was downgraded to an evidence level of 3. Because of the small number of participants and some end points that were not significantly different, superiority of 5-FU 0.5% with SA 10% over cryosurgery remains unclear.

Cryosurgery vs. CO₂ laser

Population and study design: Zane et al. studied 200 patients with a maximum of 4 lesions on the face and hairless scalp without signs of light-induced skin damage or field cancerization. A total of 543 AK of all clinical grades (I-III according to Olsen) were included.

Interventions: Randomization was interindividual 1:1 to either cryosurgery with liquid nitrogen for 10-20 seconds or single treatment with an ablative CO₂ laser [139].

Results: Lesion-wise, the complete healing rate at 3 months was 78.2% for cryosurgery and 72.4% for CO₂ laser. Regarding this endpoint, the subgroup of thicker AK (grade III) responded better to cryosurgery (80.2%) than to CO₂ laser (59.8%). Patient-wise, a greater proportion of patients treated with cryosurgery showed a complete response (71.6% vs. 65.3% for CO₂ laser), although it remains unclear whether the case number calculation was based on individuals or lesions. This superiority was also evident after a 12-month observation period (53% vs. 14% with CO₂ laser). Global cosmetic outcome was rated similarly by blinded investigators and patients for both interventions on a four-point scale (poor, moderate, good, excellent) and was excellent in 50.7% and 48.4% (investigator) and 58.9% and 50.0% (patient), respectively (cryosurgery vs. CO₂ laser, respectively). Subjectively, patient satisfaction was significantly higher on a three-point scale for cryosurgery. Common local side effects were erythema, edema, hemorrhage, blisters, erosion, crusts (cryosurgery), and erosions and crusts (CO₂ laser).

DESIGN: In this study, CO₂ laser ablation was inferior to cryosurgery with respect to the efficacy endpoints of lesion-related healing rate, complete response and partial response. However, the difference in effects was rather small and not consistently significant. Similarly, the cosmetic outcome of both interventions as assessed by the investigators was not significantly different. Only patient satisfaction was significantly higher for cryosurgery. However, the study design was open, which specifically affects the ability to assess subjective endpoints. Therefore, the study was downgraded to evidence level 3.

Cryosurgery vs. 5-fluorouracil 5% cream

Population and study design: Krawtchenko et al. conducted an unblinded, three-arm, randomized trial. Seventy-five subjects with at least 5 histologically confirmed AK in an area no larger than 50 cm² on the head, neck, or décolleté were included. Immunosuppressed individuals were excluded [136].

Intervention: Patients were randomized interindividually 1:1:1 to 5-FU 5% cream twice daily for 4 weeks, imiquimod 5% cream three times weekly for at least 8 h for 4 weeks, or spray liquid nitrogen cryosurgery (20-40 seconds per lesion). The cryosurgery and imiquimod interventions could be repeated once after 2 and 4 weeks, respectively.

Results: Complete clinical healing of all lesions was observed for 5-FU 5% in 96% of patients (23/24), for cryosurgery in 68% (17/25) and for imiquimod 5% in 85% (22/26) (p=0.03). Histopathologically confirmed complete healing rates per patient were 67% (5-FU 5%), 32% (cryosurgery) and 73% (imiquimod 5%; p=0.02), respectively. At 12 months after the end of the study, 54% of all patients treated with 5-FU 5% and 28% of all patients treated with cryosurgery still showed a sustained response of the lesions. The overall treatment field was still unremarkable after this time in 33% (5-FU 5%) and 4% (cryosurgery) of all study participants. Cosmetic outcome at 12 months was similarly poor for both interventions and was considered excellent in only 4% of cases. No serious adverse events were observed. Normal skin appearance after therapy was observed more frequently in the 5-FU 0.5% arm than under cryosurgery (58% vs. 16%). Other adverse events were similarly distributed, although more precise numbers were not reported.

Assessment: In this study, efficacy benefits of 5-FU 5% cream were demonstrated with respect to the endpoints of complete clinical and histological healing of all lesions,

with the difference in treatment effect appearing clinically relevant (96% vs. 68% and 67% vs. 32%, respectively). Because cryosurgery is a primarily lesion-directed therapy and 5-FU 5% is a primarily field-directed therapy, the two modalities have limited comparability in terms of field efficacy. Nevertheless, the results highlight that cryosurgery is likely inferior to field-directed procedures in the presence of multiple lesions or field cancerization. This is also evident in the assessment of long-term outcomes at 12 months. However, bias is possible due to the open study design. Therefore, the study was downgraded to evidence level 3.

Cryosurgery vs. imiquimod 5% cream

Two studies evaluated cryosurgery versus imiquimod 5% cream [135], [136]. A randomized, prospective, controlled trial from Australia compared cryosurgery treatment in 36 patients versus imiquimod therapy in 35 patients for 10 or more AK on the face and scalp [135]. Response was assessed 12 months after initiation of therapy in terms of lesion-related complete cure rate and patient-related complete or partial response. The complete patient-related response for repeated cryosurgery for up to 4 cycles at 3-month intervals was 85%, significantly higher than 66.9% for 2 cycles of imiquimod 5% cream for self-treatment three times per week for 3 to 4 weeks. The adverse event rate was significantly higher with blistering, redness, scaling, crusting and hypopigmentation in 54.8% of patients for cryosurgery than in 24% after Imiquimod. Therapy discontinuation occurred in 13.9% in the cryosurgery group and 28.6% in the imiquimod group, although this is inconsistent with the observed side effects. Evidence of treatment adherence between the two groups was not mentioned. The authors stated that both therapeutic modalities showed high response rates, with imiquimod treatment showing a more favorable side effect profile and better aesthetic results [135].

Another study compared cryosurgery with imiquimod 5% cream and 5-FU 5% cream [136]. In this study, cryosurgery showed lower response rates than either topical therapy and was inferior in terms of complete healing of the entire treatment field at 12 months. The study reported complete clinical healing rates of 68% for cryosurgery, 96% for 5-FU and 85% for imiquimod. In contrast, histological examination showed complete healing rates of only 32%, 67% and 73%, respectively. Long-term complete healing at 12 months of total treatment field was reported at 4%, 33% and 73%, respectively, which highlights the long-term efficacy of field therapy (here, 5-FU and imiquimod) versus lesion-directed therapy (here, cryosurgery) [136].

Cryosurgery vs. MAL red light PDT

Two studies compared cryosurgery with MAL red light PDT [140], [137]. Morton et al. performed an open-label, intraindividual study in 119 patients with a total of 1501 non-hyperkeratotic lesions on the face or hairless scalp (at least 3 per patient) [137]. Kaufmann et al. compared both interventions intraindividually in 121 patients with a total of 1343 non-hyperkeratotic lesions (at least 4 per patient). However, only extrafacial lesions on extremities, neck or trunk were treated [140]. In both studies, one treatment field was treated with MAL cream (160 mg/g) and then incubated for 3 h with an occlusive dressing. Illumination was with a narrow spectrum red light source at a wavelength of 630 nm and a dose of 37 J/cm². The other treatment field was treated with cryosurgery using liquid nitrogen at two freeze-thaw cycles. If the therapeutic success was insufficient, the treatment was repeated after 12 weeks.

After 12 weeks, the mean lesion reduction was slightly better for MAL-PDT than for cryosurgery (86.9% vs. 76.2%; $p < 0.001$). However, both interventions were relatively similar for this endpoint at 24 weeks (89.1% vs. 86.1%; $p = 0.20$). Also lesion-related, a high proportion of AK were completely healed after 24 weeks in both treatment arms, namely 85.8% for MAL-PDT and 82.5% for cryosurgery. However, in terms of global cosmetic outcome, MAL-PDT showed advantages on a four-point scale (poor, moderate, good, excellent), with 77.2% of the investigators classifying the result as excellent after 24 weeks. In comparison, this was the case in only 49.7% of patients treated with cryosurgery. Therefore, MAL-PDT was also preferred as therapy. Regarding tolerability, there were rather minor differences, although slight advantages of MAL-PDT were observed here as well. Nevertheless, both therapies were well tolerated and side effects were mild to moderate [137].

Kaufmann et al. reported similarly high mean lesion reduction rates after 24 weeks, which were 78% for MAL-PDT and 88% for cryosurgery. The latter therapy was significantly superior even with respect to this efficacy endpoint ($p = 0.002$). However, the cosmetic outcome was rated significantly worse by both the practitioner and the patient. Similarly, 59% of patients would prefer MAL-PDT therapy in the future, but only 25% cryosurgery. Both interventions were well tolerated without serious therapy-mediated side effects [140].

In summary, both intraindividual studies showed similar high efficacy values for cryosurgery of more than 80% lesion reduction. In contrast, the cosmetic results were worse than those of MAL-PDT, which were rated significantly better in both studies. Nevertheless, the open study design results in a risk of bias in the global assessment of the cosmetic outcome. In addition, measures of dispersion such as standard deviations were not consistently reported in the study by Morton et al. 2006, which is why this study was downgraded to evidence level 3. Other studies were not included in the comparison of these two interventions because of ambiguities regarding effectiveness endpoints [142], [143].

5.5.2 Surgical procedures

5.4	Consensus-based recommendation	modified 2022
EC	Surgical excision (e.g., by curettage, shave excision or complete excision) should be offered for single actinic keratoses.	
	Strong consensus	

Surgical removal of AK is a commonly performed treatment option in clinical practice, but no evidence from RCTs is available. Our literature search did not identify any randomized, adequately controlled trials that investigated surgical procedures, so an intervention-based presentation is not possible. Similarly, no RCTs on surgical procedures were identified in other systematic reviews or meta-analyses with different search strategies and databases examined [122], [123]. In contrast, there is long-standing use and broad clinical experience with surgical removal of single, clinically well-defined lesions. Various procedures such as curettage, shallow ablation ("shave excision") or complete excision are suitable here; which technique is used depends on

the clinical context and can be regarded as equivalent. The major advantage of surgical procedures is a subsequent possible histological examination, especially to exclude invasive SCC in case of an unclear clinical picture.

Some case series reported lower recurrence rates when combined with electrocautery. Experience has shown that side effect rates are low and healing rates are high with superficial ablation. The technique of surgical removal depends on the anatomical location, the clinical picture, and the individual expertise of the practitioner. Especially in hyperkeratotic lesions, which are often excluded in RCT, mechanical ablation with curette or shallow ablation is reasonable. However, if the removal is too superficial, histological examination is limited. Therefore, complete excision should be considered in high-risk patients or high-risk lesions with potentially invasive growth. Disadvantages of surgical procedures include the need for local anesthesia and general surgical risks such as bleeding, scarring and wound healing problems.

5.5.3 Chemoexfoliation

5.5	Evidence-based recommendation	modified 2022
GoR 0	Chemoexfoliation via peels can be offered for single or multiple actinic keratoses as well as for field cancerization.	
LoE 3	[133], [144] 3: De novo research	
	Strong consensus	

The principle of chemical peels in the treatment of AK is based on a non-specific ablation of skin layers to a certain depth. A single study and a systematic review or meta-analysis on chemical peels were identified [144], [133].

Steeb et al. evaluated chemical peels in a systematic review and meta-analysis [133]. They identified 4 RCT, 2 non-randomized studies and 2 single-arm studies with a total of 170 patients. The protocols were very heterogeneous, which makes comparability difficult. In addition, methodological deficiencies were described, especially in blinding and selective reporting of results. In two studies, TCA 35% was compared with Jessner's solution versus 5-fluorouracil 5% cream. The peel was significantly inferior with respect to the endpoint complete patient-related healing rate (relative risk 0.36; 95% CI 0.14-0.90; p=0.03) [133], [145]. Another two studies compared TCA 35% and TCA 50%, respectively, versus PDT performed conventionally. Similarly, peeling was inferior to PDT with respect to the two endpoints lesion-related healing rate (relative risk 0.75; 95% CI 0.69-0.82; p<0.0001) and mean lesion reduction per patient (mean difference -20.48; 95% CI -31.55 to -9.41; p=0.0003) [146], [144]. This contrasts with a lower pain of treatment with TCA vs. PDT as rated on a visual analog scale of 1-10 (mean difference -1.71, 95% CI -3.02 to -0.41; p=0.010). In the single-arm studies, some reported high healing rates with a combination of 5-fluorouracil 5% cream and glycolic acid (92%) or phenol (90.6%), but there were no control arms [133].

Overall, chemical peels were inferior to topical drug-based procedures in terms of efficacy endpoints. Peels with moderate or deep ablation nevertheless appear to have high healing rates. However, the protocols in the included studies are heterogeneous and methodological flaws have been identified.

Table 15: Overview of included individual studies on chemoexfoliation

Study	Interventions	Single AK	Multiple AK	Field cancerization	Immunosuppression
Holzer 2016 [144]	Trichloroacetic acid vs. ALA red light PDT	(X)	X	X	

Trichloroacetic acid vs. ALA red light PDT

Holzer et al. evaluated trichloroacetic acid (TCA) intra-individually versus conventional ALA-red light PDT [144]. A total of 28 patients with at least 5 lesions or field cancers in two comparable areas of the hairless scalp or face were included. Randomization was 1:1 to peeling with 35% TCA or 20% ALA-PDT with red light. Based on individual lesions, there was a reduction of 31.9% (TCA) versus 58.0% (ALA-PDT). Patients who showed complete or near-complete healing of all lesions after blinded assessment was 54.5% (12/22 patients with ALA-PDT) versus only 11.8% (2/17 with TCA). Although there was no significant difference between the two groups in terms of cosmetic outcome, the ALA-PDT group tended to perform better in this regard. Therapy-related pain, in contrast, was more frequent and more severe in ALA-PDT as measured by a visual analog scale of 1-10 (7.5 versus 5.1). Scarring was observed in 6 patients treated with TCA (21.4%).

5.5.4 Dermabrasion

The effect of dermabrasion is based on mechanical ablation of the uppermost skin layers down to the dermoepidermal junction zone using bur-like instruments. This is a rather older procedure that has been used for field-directed therapy of AK. No RCTs on mechanical dermabrasion have been identified. Retrospective observational studies and case series on dermabrasio in the therapy of AK exist, but they have not been systematically studied, so no consensus- or evidence-based recommendation can be made here.

The technical execution of dermabrasion is poorly standardized, and efficacy and safety depend heavily on the individual expertise of the practitioner. When done correctly, high and sustained complete response rates of 83-96% at 2 years have been reported [147]. Because the procedure is painful, local anesthesia is usually required and analgesia is sometimes necessary for large treatment areas. This significantly reduces the practicality for both the physician and patient. In addition, if the ablation is too deep, there may be pronounced wound healing problems and scarring. Therefore, the risk-benefit ratio of dermabrasion should be carefully weighed, especially against the background of RCT-proven effective treatment alternatives.

5.5.5 Potassium hydroxide

5.6	Evidence-based recommendation	new 2022
GoR 0	Potassium hydroxide 5% solution can be offered for single or multiple actinic keratoses.	
LoE 3	[148] 3: De novo research	
	Strong consensus	

Potassium hydroxide (KOH) is a chemically destructive local therapeutic agent used in the treatment of viral warts such as *Mollusca contagiosa*. In addition, KOH is believed to have keratolytic properties. For the treatment of AK, a medical product is available in pharmacies only in a 5% solution, which is applied lesion-directed to a maximum of 10 lesions (grade I-II according to Olsen) with a maximum diameter of 2 cm. The lesions should be well demarcated and isolated. As a medical device, potassium hydroxide 5% solution occupies an intermediate position between prescription topical medicinal procedures and physically or chemically active destructive local procedures. In this regard, the evidence for potassium hydroxide 5% solution is limited. The literature search identified a single study comparing potassium hydroxide 5% solution with 5-fluorouracil 5% cream [\[148\]](#). Furthermore, data exist from a single-arm, prospective, multicenter medical device study that was excluded due to study design (TAKKOH study, "Treatment of AK with KOH") [\[149\]](#). This study included 73 patients with 1-10 lesions (grade I-II according to Olsen). Potassium hydroxide 5% solution was applied once daily lesion-directed for 14 days, followed by a 14-day therapy break (1 cycle=28 days). A total of up to 3 cycles were allowed. After up to 3 cycles of treatment, the patient-related complete healing rate was 54.9%, and the partial healing rate was 64.8%. Lesion-related healing rate was 69.9%. Overall, 46.6% (37/73 patients treated) experienced adverse events. These were exclusively adverse local reactions such as pain (27%), erythema (6.8%), bleeding (5.5%), pruritus (4.1%), crusting (4.1%) and desquamation (1.4%). These events were of mild intensity in 93%. Tolerability was rated as "very good" or "good" by 90.5% of the investigators and by 93.2% of the patients, indicating good tolerability [\[149\]](#).

Table 16: Individual studies on potassium hydroxide

Study	Intervention	Single AK	Multiple AK	Field cancerization	Immuno-suppression
Salehi Farid 2020 [148]	Potassium hydroxide 5% solution vs. 5-fluorouracil 5% cream	X	X		

Potassium hydroxide 5% solution vs. 5-fluorouracil 5% cream

Population and study design: An Iranian study compared KOH 5% solution vs. 5-fluorouracil 5% cream intraindividually in 18 patients. However, of these, only 13 (KOH) and 10 (5-FU) were followed up over a 3-month period. Patients had at least 2 lesions on each side on the capillitium or face (i.e., at least 4 lesions per patient). A total of 118 were treated, 68 with KOH 5% solution and 50 with 5-fluorouracil 5% cream [148].

Intervention: Patients were randomized intraindividually 1:1 to KOH 5% aqueous solution or 5-fluorouracil 5% cream. Application was once daily in the evening for 4 weeks in both cases. KOH 5% was applied lesion-directed, 5-FU was field-directed.

Results: After 1 month, the lesion-directed healing rate was 81% for KOH 5% and 58% for 5-fluorouracil ($p=0.04$), respectively. After 3 months, this rate was 83% for KOH 5% (38/46 lesions) and 70% for 5-fluorouracil (26/37 lesions; $p=0.2$), respectively. In the KOH-treated side, erosion (30.9% vs. 8%; $p<0.001$) and ulceration (98.5% vs. 8%; $p<0.001$) were observed more frequently. In contrast, erythema (48% vs. 19%; $p<0.001$), scaling (58% vs. 5.9%; $p<0.001$) and swelling (20% vs. 0%; $p<0.001$) were more common in the 5-FU-treated side. Crusting was observed with similar frequency in both interventions (23.5% vs. 18%; $p=0.556$).

Assessment: In this study, there was a slight efficacy benefit for KOH 5% at 1 month, but this was no longer consistent at 3 months. The spectrum of side effects differed depending on the mechanism of action (KOH: ulceration, erosion; 5-FU: erythema, scaling, swelling), so it is not possible to make a blanket statement about which intervention was better tolerated. KOH 5% is a lesion-directed approach, whereas 5-FU is a field-directed therapy. In this population with at least 2 AK per treatment field, KOH 5% showed good lesion-related cure rates of 83%. However, these efficacy values are probably limited to patients with few and single lesions, which are therefore prognostically more favorable anyway. The validity of the study is limited by a high rate of patients who dropped out or were not treated according to protocol ("attrition bias"), a low number of cases, and the lack of female study participants. The level of evidence was therefore downgraded to 3. Also, the application once daily continuously over 4 weeks does not correspond to the current recommended application in Germany (once daily over 14 days followed by 14 days therapy-free interval, maximum 3 cycles), so that transferability is also limited.

Overall, treatment of AK with KOH 5% solution is reasonable in patients without significant risk factors for unfavorable disease progression and with single, small and

well-isolated lesions without signs of field cancerization. Due to a favorable risk-benefit ratio and the status as a medical device available only in pharmacies, KOH 5% is also well suited for self-directed on-demand therapy ("stand-by"-therapy) in this population after appropriate education and instruction.

5.5.6 Laser therapy

5.5.6.1 Ablative laser procedures

5.7	Evidence-based recommendation	modified 2022
GoR 0	Ablative laser procedures can be offered for single or multiple actinic keratoses, as well as for field cancerization.	
LoE 2	[122] , [139] , [150]	
	Consensus	

Laser ablation is important for the treatment of low-risk superficial AK as a less invasive alternative to surgery. Precise, rapid, and strictly localized tissue vaporization can be achieved, for example, with ablative Erbium:YAG and CO₂ lasers [\[151\]](#). However, as with topical-medicinal and with ablative-destructive procedures other than surgical interventions, histopathological confirmation is not done. However, increasingly non-invasive imaging techniques such as confocal laser microscopy with its optical imaging offer the possibility of achieving a control similar to histopathology directly on the patient at the cellular level, thereby improving the efficiency and safety of the ablation procedure (see [Chapter 4.6](#)) [\[152\]](#).

Despite these technical innovations and developments, data on laser procedures from RCTs, on the basis of which evidence-based recommendations can be made, remain limited. The systematic literature search revealed 2 single studies that compared treatment with Erbium:YAG laser with 5-FU 5% cream or CO₂ laser with cryosurgery in immunocompetent patients [\[150\]](#), [\[139\]](#). In a systematic review with meta-analysis by Gupta et al. 2012 [\[122\]](#), regarding ablative laser procedures, the study by Ostertag et al. 2006 [\[150\]](#), and another paper by Hantash et al. 2006 were also analyzed [\[153\]](#). No RCT on laser therapy in immunosuppressed patients were identified.

Some papers investigated the efficacy of a combination of lesion-directed laser therapy with field-directed procedures [\[134\]](#). In this case, pretreatment with ablative fractional laser (AFXL) in particular increased the uptake of topically applied therapeutics and lesion-specific healing rates. This concept of assisted drug delivery ("laser-assisted drug delivery") allows efficient treatment of many dermatologic conditions including AK. Among others, publications are available for fractional laser ablation before application of 5-FU 5% cream [\[154\]](#), IMB gel (IMB) [\[155\]](#), or MAL red light PDT for grade II-III lesions in immunocompetent patients [\[156\]](#), [\[157\]](#). The combination of AFXL with MAL-PDT was also studied in immunocompromised organ transplant patients, where the combination of AFXL and PDT was significantly superior to AFXL alone in terms of complete response (73% vs. 31%; p=0.002) [\[158\]](#).

Table 17: Overview of the included single studies on ablative laser therapy

Study	Interventions	Single AK	Multiple AK	Field cancerization	Immunosuppression
Ostertag 2006 [150]	Laser resurfacing vs. 5-FU 5% cream		X	X	
Zane 2014 [139]	Ablation with CO ₂ laser vs. cryosurgery	X			

Laser resurfacing vs. 5-FU 5% cream

Population and study design: Ostertag et al. investigated the long-term efficacy and recurrence rates of 5-FU 5% cream compared to ablative laser therapy in 55 patients in a randomized, double-blind trial [150].

Intervention: Patients were randomized 1:1 to 5-FU 5% cream twice daily for 4 weeks or a maximum of 7 weeks, if less effective, and to ablative laser treatment with the Derma-K laser (Lumenis®) in Erbium:YAG or CO₂ mode.

Results: After 3 months, the mean lesion reduction per patient was 13.2 for 5-FU 5% and 13.8 for laser treatment. At 6 months, this number was 12.5 and 13.9, and at 12 months, 12.4 and 14.2 (5-FU 5% versus laser), respectively. The differences in absolute lesion reductions were not significant. The mean percent reduction at 12 months was 91.1% for laser therapy and 76.6% for 5-FU 5%. This difference was significant ($p=0.048$). Similarly, recurrence rates at 3, 6, and 12 months were consistently higher for topical treatment with 5-FU 5% than for ablative laser therapy. Improvement with respect to UV-induced skin aging of treated areas was also observed more frequently after laser treatment. This endpoint was measured on a 0-9 scale composed of the individual components wrinkles, skin color or pigmentation, and keratoses. At 12 months, the score on this scale improved significantly more often with laser (74%) than with 5-FU 5% (43%). Side effects of both interventions included erythema, edema, infection, crusting, pain, skin irritation and itching. They tended to be observed more frequently after laser treatment. In this case, edema and infections occurred more frequently shortly after treatment, and erythema and hypopigmentation occurred more frequently in the longer-term course.

Evaluation: The effectiveness of the interventions was not significantly different in terms of absolute lesion reduction, only the percentage reduction was reported to be superior for laser therapy. However, the magnitude of the effect appears to be rather small. Regarding long-term effects, laser therapy was significantly superior, but at the expense of long-term side effects. Therefore, further studies are needed to investigate the risk-benefit ratio of these two interventions.

CO₂ laser vs. cryosurgery

One study was identified [139]. For a comparison of these interventions, [Chapter 5.5.1](#).

Population and design: Zane et al. studied 200 patients with a maximum of 4 lesions on the face and hairless scalp without signs of light-induced skin damage or field cancerization. A total of 543 AK of all clinical grades (I-III according to Olsen) were included.

Intervention: Randomization was 1:1 to either cryosurgery with liquid nitrogen for 10-20 seconds or single treatment with an ablative CO₂ laser.

Results: Lesion-wise, the complete healing rate at 3 months was 78.2% for cryosurgery and 72.4% for CO₂ laser. Regarding this endpoint, the subgroup of thicker AK (grade III according to Olsen) responded better to cryosurgery (80.2%) than to CO₂ laser (59.8%). In terms of individuals, a greater proportion of patients treated with cryosurgery showed a complete response (71.6% vs. 65.3% for CO₂ laser), although it remains unclear whether the case number calculation was based on individuals or lesions. This superiority was also evident after a 12-month observation period (53% vs. only 14% with CO₂ laser). Global cosmetic outcome was rated similarly by blinded investigators and patients for both interventions on a four-point scale (poor, moderate, good, excellent) and was excellent in 50.7% and 48.4% (investigator) and in 58.9% and 50.0% (patient), respectively (cryosurgery vs. CO₂ laser, respectively). Subjectively, patient satisfaction was significantly higher on a three-point scale for cryosurgery. Common local side effects were erythema, edema, hemorrhage, blistering, erosion, crusting (cryosurgery), and erosion and crusting (CO₂ laser).

Assessment: In this study, CO₂ laser ablation was inferior to cryosurgery with respect to the efficacy endpoints of lesion-related healing rate, complete response, and partial response. However, the difference in effects was rather small and not consistently significant. Similarly, the cosmetic outcome of both interventions as assessed by the investigators was not significantly different. Only patient satisfaction was significant and significantly higher for cryosurgery. However, the study design was open, which specifically affects the ability to subjective endpoints. Therefore, the study was downgraded to evidence level 3.

Interestingly, complete response at 12 months was significantly better for cryosurgery than for laser therapy. These results are in contrast to the study by Ostertag 2006, in which laser resurfacing was superior to topical therapy with 5-FU 5% cream, especially with regard to long-term efficacy [150]. The results therefore suggest that the results of CO₂ laser are dependent on the number of lesions and the size of the treated area.

5.5.6.2 Non-ablative laser procedures

5.8	Consensus-based recommendation	modified 2022
EC	Non-ablative laser procedures can be offered for single or multiple actinic keratoses.	
	Strong consensus	

Evidence from RCTs on non-ablative laser procedures in the treatment of AK is limited. No papers with this design were identified in our literature search. Nevertheless, retrospective and non-randomized studies exist on the use of non-ablative lasers such as the Nd:YAG as well as the fractional 1540 nm laser.

Lapidoth et al. treated 17 patients with a 1540 nm fractional non-ablative laser with 75 millijoule fluence, 15 millisecond pulse duration, and a spot size of 10 mm. After 3 months, a blinded evaluation took place and showed a 75% improvement in AK on a four-point scale [159]. The use of a long-pulsed dye laser with 595 nm wavelength as a light source for performing PDT showed comparable results in terms of lesion-specific healing rates, with clearance rates of more than 90% over a follow-up period of up to 8 months. These rates were lower for lesions on the extremities and trunk [160]. Another retrospective, uncontrolled study investigated the Nd:YAG laser ($\lambda=1060$ nm) in the treatment of basal cell carcinoma and other NMSC tumors [161]. Since this work did not primarily treat AK, the transferability of the intervention is currently uncertain and requires further evaluation in future RCTs.

5.6 Topical drug-based procedures

5.6.1 Diclofenac

5.9	Evidence-based recommendation	modified 2022
GoR B	Diclofenac sodium 3% gel should be offered for single or multiple actinic keratoses.	
LoE 1	[162] , [163] , [164] , [127] , [141] , [165] , [166] , [167] , [168] , [169] , [170] , [171] , [172] , [173] , [174] , [175]	
	Strong consensus	

5.10	Evidence-based recommendation	modified 2022
GoR B	Diclofenac sodium 3% gel should be offered for field cancerization.	
LoE 2	[166] , [168] , [170] , [173]	
	Strong consensus	

The non-steroidal anti-inflammatory drug diclofenac has been approved in a 3% gel for the topical treatment of AK in adults since 2011. Its antitumor effects are mainly due to inhibition of cyclooxygenase-2. It is available as a gel that should be applied twice daily in the morning and evening for a maximum of 12 weeks (90 days). The most common adverse effects include local skin reactions such as contact dermatitis, erythema, rash, pain or blisters. During treatment, care should be taken to avoid sun or UV radiation. Prolonged treatment for 6 months was investigated in an open-label, randomized, multicenter study in 418 patients with mild to moderate AK [\[169\]](#). However, this showed no significant benefit in terms of the proportion of patients with complete healing of all lesions with prolonged use (45% for 6 months versus 40% for 3 months), so a treatment duration of 60-90 days is recommended.

The systematic literature search identified 13 randomized individual studies that investigated diclofenac sodium 3% gel. In addition, 4 systematic reviews or meta-analyses were identified [\[141\]](#), [\[122\]](#), [\[127\]](#), [\[164\]](#). The network meta-analysis by Vegter 2014 [\[127\]](#), identified a complete response of 24.7% (95% CI 12.4-37.0%) from a total of 5 studies with a pooled total population of 413 patients, which can be considered rather low compared to other interventions studied. However, only this efficacy endpoint (complete patient-related response) was considered. The comprehensive meta-analysis by Gupta in 2012 [\[122\]](#), among others, favored

treatment with diclofenac sodium 3% gel and calculated from 3 studies with a pooled population of 420 patients that participants treated with diclofenac sodium 3% gel were 2.5 times more likely to have complete healing of lesions compared with vehicle cream. However, it was reported that side effects significantly predominated in the diclofenac group compared with the placebo group. In particular, the rate of patients with treatment-mediated discontinuations was higher in this group (relative risk 3.59; 95% CI 1.92-6.70). The systematic review by Askew 2009 [141] reported a complete lesion-related healing rate of 89% with diclofenac sodium 3% gel. Another network meta-analysis by Ezzedine 2021 calculated an odds ratio of 2.53 (95% CI 0.53-11.64) for the endpoint complete patient-related healing rate for diclofenac 3% gel versus placebo. For the endpoint patient-related partial response, this value was 7.74 (95% CI 0.44-129.20) [164]. Both values are relatively low compared with other interventions, but the CIs for most of the calculations from this analysis are very wide, making it difficult to assess.

The majority of studies investigated diclofenac sodium 3% gel in immunocompetent patients with single or multiple AK. The studies show that there is evidence for the use of diclofenac sodium 3% gel in single and multiple AK, predominantly in mild to moderate lesions (Olsen grade I-II). Gebauer et al. further demonstrated the efficacy of this combination in hyperkeratotic lesions [166]. Several studies investigated diclofenac sodium 3% gel as a field-directed therapy in patients with signs of field cancerization. In addition, another study was identified in organ transplanted patients* with immunosuppression [172], see [Chapter 5.8](#).

Table 18: Overview of individual studies on diclofenac sodium 3% gel

Study	Interventions	Single AK	Multiple AK	Field cancerization	Immuno-suppression
McEwan 1997 [168]	Diclofenac sodium 3% gel vs. vehicle	unclear	unclear	X	
Wolf 2001 [173]	Diclofenac sodium 3% gel vs. vehicle		X	X	
Rivers 2002 [170]	Diclofenac sodium 3% gel 2x/d for 30 days vs. diclofenac sodium 3% gel 2x/d over 60 days vs. vehicle 2x/d over 30 days vs. vehicle 2x/d over 60 days		X	X	

Study	Interventions	Single AK	Multiple AK	Field cancerization	Immuno-suppression
Gebauer 2003 [166]	Diclofenac sodium 3% gel vs. vehicle		X	X	
Akarsu 2011 [165]	Diclofenac sodium 3% gel vs. imiquimod 5% cream vs. placebo	X			
Ulrich 2010 [172]	Diclofenac sodium 3% gel vs. vehicle	X	X	unclear	X
Cose 2008 [167]	Diclofenac sodium 3% gel vs. imiquimod 5% cream	X	unclear		
Stockfleth 2011 [175]	Diclofenac sodium 3% gel vs. 5-FU 0.5% with SA 10% solution vs. Placebo	X	X		
Stockfleth 2012* [176]	Diclofenac sodium 3% gel vs. 5-FU 0.5% with SA 10% solution vs. placebo	X	X		
Segatto 2013 [171]	Diclofenac sodium 3% gel vs. 5-FU 5% cream	X	X		
Zane 2014 [174]	Diclofenac sodium 3% gel vs. MAL-cPDT	X	X		

Study	Interventions	Single AK	Multiple AK	Field cancerization	Immuno-suppression
Ploughfields 2012 [169]	Diclofenac sodium 3% gel for 3 months vs. diclofenac sodium 3% gel for 6 months		X	unclear	
Gollnick 2020 [162]	Diclofenac sodium 3% gel vs. imiquimod 5% cream		X		
Stockfleth 2018 [163]	Diclofenac sodium 3% gel vs. IMB 0.015% gel	X	X		
* Follow-up study of Stockfleth 2011					

Diclofenac sodium 3% vs. placebo (immunocompetent)

A total of six independent studies were identified that compared the use of diclofenac sodium 3% gel with vehicle for efficacy. Of these six studies, one investigated efficacy in organ transplant recipients undergoing immunosuppression [172], which is reported separately.

Population and study design: The oldest study by McEwan in 1997 compared the active ingredient in the carrier gel hyaluronic acid with vehicle in a 1:1 randomized, double-blind, monocentric study. Of the 130 participants included, 73 were male and 57 were female; the age range was 48 to 87 years. AKs of varying severity were included [168]. Scaling of AK reported in 62 of the 65 AKs in the verum group suggests that more severe AK manifestations were also treated. 28 of the 65 documented AKs were on the hands. The study by Wolf (2011) was based on a multicenter, randomized, double-blind, placebo-controlled, parallel-group design in which 58 patients were included in the active group and 59 patients in the control group [173]. Another study by Rivers in 2002 included 195 patients (73% male) with at least 5 AK in a randomized, double-blind, placebo-controlled multicenter trial with parallel group design. Participants were randomized to a total of 4 different groups in a 1:1:1:1 scheme, which differed in treatment duration [170]. The multicenter study by Gebauer 2003 had a randomized, double-blind, placebo-controlled parallel group design and included 150 patients (89 men, 61 women) with a mean age of 68 years (range 27-87 years). 73 of the participants were randomized to the active group and 77 to the placebo group [166]. In another study, the effect of diclofenac sodium 3% gel was compared with the effect of imiquimod 5% cream twice a week and the application of pure base gels (vehicle) in 61 patients [165]. This also resulted in

comparative data from diclofenac sodium 3% gel to drug-free foundation, but these are presented under the comparison to imiquimod.

Interventions: In McEwan's study, diclofenac sodium 3% gel or vehicle was applied only twice daily for 8-24 weeks to areas of varying size and thereby in varying amounts. In addition, sunscreen was applied during the day. In the study by Wolf et al., patients applied 0.5 g of diclofenac sodium 3% gel twice daily per 5 cm² of area for 90 days. In the third study by Rivers, 4 parallel groups with different intervention schedules were present: Group 1 received 0.5 g of 3% diclofenac sodium gel twice daily for 30 days (n=49), and Group 2 received the same therapy but for 60 days (n=48). Group 3 received placebo for a duration of 30 d, and group 4 again received placebo for 60 d (n=49 each). In Gebauer's study, patients applied 0.25 g of gel as active substance or vehicle to a defined area of 5 cm² twice daily for 12 weeks. For more detailed intervention details of the study by Akarsu (2011).

Results: McEwan et al. reported complete healing in 29% and 17% of participants, respectively (diclofenac vs. placebo; p=0.14), and partial healing of at least 75% in 38% and 45% of participants, respectively (p=0.18). Side effects were higher (29%) in the treatment group compared to 5% with baseline only. These were mostly skin irritations. The difference was statistically significant [168].

In the study by Wolf et al., a complete patient-related response (operationalized by a TLNS of 0) in 50% of the intervention group versus 20% in the control group demonstrated the superiority of diclofenac sodium 3% gel (p<0.001). The investigators' assessment of global efficacy using IGII as "completely improved" was higher at 47% vs. 19% than the patients' assessment of the same endpoint using PGII at 41% vs. 17% (diclofenac vs. placebo, respectively). In terms of side effects, local skin symptoms occurred in 90% and 81% of cases, respectively. The most common were pruritus (55% vs. 49%), irritation (34% vs. 20%) and skin dryness (36% vs. 17%, respectively, diclofenac vs. placebo) [173].

Of the 4 groups in the third study by Rivers 2003, the 60-day verum group showed clear superiority over the 60-day placebo group in terms of efficacy. A complete patient-related response (operationalized by a TLNS of 0) was achieved by 33% taking diclofenac sodium 3% gel and by 10% taking placebo, respectively (p<0.005). The global effect assessment by IGII by the investigators as "completely improved" was 31% vs. 10% (p<0.05), similar to the patients' assessment of 29% vs. 10% (PGII; p<0.05). Compliance of the groups was comparable. A total of 10 serious adverse events occurred in 7 participants in the active group, including pruritus, local irritation, paresthesia, rash, edema and contact dermatitis. Of these, 6 side effects were possibly attributable to treatment [170].

In the Gebauer 2003 study, complete healing of lesions per patient occurred in 38% of the intervention group and in 10% of the placebo group (p=0.002). A more than 50% reduction of lesions was present after 16 weeks in more than half of the participants in the diclofenac group (65% vs. 29% under placebo). The difference was statistically highly significant. At 16 weeks, the mean number of lesions also decreased more in the verum than placebo group, by 6.2±7.5 (56.1% reduction) vs. 2.4±4.3 (23.6% reduction). Side effects were predominantly mild and mostly included pruritus, erythema, edema and scaling. 19% of cases with pruritus, 18% with dry skin and 12% of those with skin irritation were reported as severe in this regard [166].

For the results of the study by Akarsu (2011), see [Chapter 5.6.5](#).

Assessment: The collected assessment of the studies is complicated by the different observation times and different treatment protocols. In the study by McEwan et al., no significant superiority to vehicle was observed with respect to complete or partial response. In this collective, a proportion of lesions were on the back of the hands/hands. However, local side effects were significantly more frequent [168]. These results are in contrast to the other studies, in which significantly improved efficacy endpoints were visible versus vehicle in each case. The strength of the effect was moderate. This is also supported by the meta-analysis by Vegter and Tolley, in which lower values were observed for diclofenac sodium 3% gel compared to other interventions with regard to the effectiveness endpoint complete patient-related response [127]. This is in contrast to good cosmetic results and good tolerability. A long application time of 60-90 days implies good therapy adherence. The Wolf 2001 study was downgraded to evidence level 3 due to unclear randomization and asymmetric distribution of study dropouts [173].

Diclofenac sodium 3% gel vs placebo (immunosuppressed)

Population and study design: In 32 organ transplant patients with immunosuppression (31 men, 3 women aged 49-77), diclofenac sodium 3% gel was compared with placebo in a randomized, double-blind, placebo-controlled multicenter trial [172]. 24 of the patients were randomized to the active group and 8 to the control group. Of the 32 patients, 6 had liver transplantation, 18 had kidney transplantation, and 8 had heart transplantation. The evaluation was done after 20 weeks and after 24 months.

Intervention: Application of diclofenac sodium 3% gel or placebo twice daily for 16 weeks.

Results: Complete healing was seen in 41% of patients in the verum group vs. 0% of the placebo group, regardless of which organ had been transplanted. Partial healing of at least 75% was seen in 59% in the active group vs. 16.7% in the control group. Differences according to the organ originally transplanted were present, but the number of cases appear too small for these differences to be meaningful enough and could not have been caused by other, intraindividual factors. One exception, however, is the 18 heart transplanted patients who showed 100% partial improvement on verum and 0% on placebo. The mean reduction in the number of lesions was 53% vs. 17% (verum vs. placebo). The recurrence rate was 55% after a mean of 9.3 months, and side effects reported were mild to moderate erythema, scaling, pruritus, skin irritation and edema.

Rating: Due to the loss of patients and ambiguities in randomization, there is a risk of bias, which is why the level of evidence was downgraded to 3. However, from the reported endpoints of effectivity, there is a large effect of the intervention compared with placebo; the difference in complete response was most pronounced in the heart transplant subgroup. For evidence-based recommendations on the use of diclofenac sodium 3% gel in organ transplant recipients, see [Chapter 5.8](#).

Diclofenac sodium 3% gel vs. imiquimod 5% cream

For more information, see [Chapter 5.6.5](#).

Diclofenac sodium 3% gel vs. 5-fluorouracil 5% cream

A randomized parallel group trial with 28 participants examined this intervention [171]. For more details comparing these interventions, see [Chapter 5.6.2](#).

Diclofenac sodium 3% gel vs 5-fluorouracil 0.5% with salicylic acid 10% solution

One trial and one follow-up evaluated these interventions in a three-arm, interindividual design [175], [176]. For more detailed information comparing these interventions, see [Chapter 5.6.3](#).

Diclofenac sodium 3% gel vs MAL red light PDT

Zane et al. carried out an open-label, monocentric, randomized trial comparing these interventions in 200 patients with a total of 1674 lesions [174]. For more details comparing these interventions, see [Chapter 5.7.1](#).

Diclofenac sodium 3% gel vs. ingenol mebutate 0.015% gel

Population and study design: Stockfleth et al. investigated both interventions in a randomized phase IV study in direct comparison. A total of 502 patients from 33 centers in Germany, Spain and the United Kingdom were randomized. The median age of the participants was 75 years (range 34-96 years), 85.2% were male. The median lesion number per patient was 6 (range 4-9) [163]. The treatment area included a contiguous area of 25 cm² on capillitium and face.

Interventions: The study population was randomized in a 1:1 ratio to one of the two therapies. IMB 0.015% gel was applied once daily for three consecutive days. After 8 weeks, treatment was allowed to be repeated if response was inadequate or new lesions appeared. Diclofenac sodium 3% gel was applied twice daily for 90 days.

Results: After the first treatment cycle (8 weeks for IMB, 17 weeks for diclofenac sodium 3% gel), the patient-specific complete healing rate was 34.5% (IMB) vs. 23.5% (diclofenac). The difference was statistically significant ($p=0.006$). After two cycles (17 weeks), the values were 45.1% vs. 23.5% ($p<0.001$). Patient-related partial response after the first cycle of treatment was 57.6% (IMB) vs. 43.3% (diclofenac; $p=0.001$). The percent lesion reduction after the first cycle was 69.5% vs. 57.7% ($p<0.001$) and after the second cycle was 77.2% vs. 57.7% ($p<0.001$). After two cycles, scores for this endpoint were 69.0% vs. 43.3% ($p<0.001$). Patient satisfaction was significantly higher for IMB at 17 weeks ($p<0.001$). The rate of adverse events was slightly higher for IMB than for diclofenac (49% vs. 41%). In contrast, the rate of treatment discontinuation due to side effects was slightly higher for diclofenac (6%) than for IMB (2%). The following adverse events were reported in this study (IMB vs. diclofenac): erythema 19% vs. 11.5%, crusting/scaling 8.1% vs. 2.6%, pain 6.5% vs. 3.4%.

Assessment: The study was methodologically well executed and without major risks for bias. The only point of criticism remains the lack of blinding. Regarding the efficacy endpoints, there was an advantage for IMB. However, this therapy was allowed twice, whereas the treatment with diclofenac was allowed only once. Considering the effectiveness scores, it appears that much of the effectiveness superiority of IMB in this study was actually caused by the second treatment cycle. Side effects were observed more frequently for IMB. In contrast, the rate of treatment discontinuation due to side effects was slightly higher for diclofenac, which may be due to the longer treatment duration of 90 days in addition to local side effects.

Therefore, this study shows that good treatment adherence is necessary for diclofenac. Despite the efficacy advantage of IMB in this study, this topical is not recommended because of the current dormant approval in Europe and the possible increased incidence of NMSC and melanoma in the treatment area (see [Chapter 5.6.4](#)).

5.6.2 5-fluorouracil

5-Fluorouracil (5-FU) is a cytostatic drug. The pharmacologically active component of 5-FU, 5-fluorodeoxyuridine monophosphate, is an antimetabolite that prevents the methylation of deoxyuridine monophosphate acid to deoxythymidine monophosphate by inhibiting thymidilate synthase. This leads to thymidine deficiency, which impairs DNA synthesis and RNA transcription. Although this affects proliferatively active cells more than normal keratinocytes, the mechanism of action of 5-FU is thus non-specific. It is metabolized predominantly by the enzyme dihydropyrimidine dehydrogenase (DPD). Patients with reduced activity of this enzyme may experience decreased degradation with the risk of severe local or even systemic side effects. In addition, DPD activity is impaired by viral nucleoside analogues such as brivudine. Severe side effects have also been observed with concomitant, systemic administration of methotrexate. In Germany, 5-FU is approved as a 5% cream for the treatment of AK for a maximum area of 500 cm². In addition, a 4% formulation is available for the face, ears and scalp with no area limitation. A combination of low-dose 5-FU (0.5%) with salicylic acid 10% in solution is also approved in Germany for the treatment of AK with an area limitation of 25 cm². In the USA, a 0.5% preparation of 5-FU in a cream base mixed with microspheres is also approved, for which there is no approval in Germany.

5.6.2.1 5-Fluorouracil 5%

5.11	Evidence-based recommendation	modified 2022
GoR B	5-Fluorouracil 5% cream should be offered for single and multiple actinic keratoses.	
LoE 1	[164], [177], [178], [122], [136], [141], [150], [171], [179], [180], [181] 1: De novo research	
	Strong consensus	

5.12	Evidence-based recommendation	modified 2022
GoR B	5-Fluorouracil 5% cream should be offered for field cancerization.	
LoE 2	[177], [150], [182] 2: De novo research	
	Strong consensus	

In Germany, 5-FU is approved as a 5% cream for the treatment of AK for a maximum area of 500 cm². It is applied twice daily for a maximum of 4 weeks. After 1-2 weeks, first treatment effects such as redness or erosion are usually observed. The systematic literature search revealed 6 individual studies that investigated 5-FU at 5% concentration [136], [150], [180], [171], [181], [177]. In addition, identified 4 systematic reviews or meta-analyses that evaluated 5-FU 5% [141], [122], [164], [178]. In a network meta-analysis that synthesized the effectiveness of interventions for AK localized outside the head and neck region, the partial cure rate ($\geq 75\%$) was 100% for 5-FU and 7% for vehicle [129].

All studies carried out in immunocompetent patients with single to multiple AK. No RCTs were identified that explicitly studied 5-FU in immunocompromised patients. In several studies, the clinical grade of the included lesions was not further specified. Therefore, no conclusion can be made as to whether the efficacy of 5-FU also applies to hyperkeratotic (grade III) lesions. Furthermore, no study on 5-FU in immunocompromised or organ transplant patients was identified.

Table 19: Overview of included individual studies on 5-FU (concentration 5%)

Study	Interventions	Single AK	Multiple AK	Field cancerization	Immunosuppression
Jansen 2019 [177]	5-FU 5% cream vs. IMB 0.015% gel vs. imiquimod 5% cream vs. MAL-cPDT		X	X	
Pomerantz 2015 [180]	5-FU 5% cream vs. placebo	X	X		
Ostertag 2006 [150]	5-FU 5% cream vs. laser resurfacing		X	X	
Krawtchenko 2007 [136]	5-FU 5% cream vs. imiquimod 5% cream vs. cryosurgery	X	X		
Tanghetti 2007 [181]	5-FU 5% cream vs. imiquimod 5% cream	X	X		
Segatto 2013 [171]	5-FU 5% cream vs. diclofenac sodium 3% in hyaluronic acid 2.5% gel	X	X		

5-Fluorouracil 5% cream vs. placebo

Population and study design: The long-term efficacy of a single cycle of therapy with 5-FU 5% cream was evaluated in the placebo-controlled, double-blind, randomized VAKCC trial ("Veteran Affairs Keratinocyte Carcinoma Chemoprevention Trial"). The study population was 932 war veterans with AK predominantly on the face and ears recruited from 12 centers within the US. This was a high-risk population with a history

of at least 2 epithelial skin tumors on the ears or face within the last 5 years before study inclusion. Exclusions included patients with DPD deficiency and organ transplant recipients [180].

Intervention: Randomization was 1:1 interindividually to either 5-FU 5% cream twice daily for 4 weeks (56 applications total) or vehicle only (placebo). If side effects occurred, interruption of therapy with topical steroid administration was allowed. If fewer than 28 doses were administered by then, therapy could be resumed with 5-FU 0.5% once daily until 56 administrations were reached.

Results: After 6 months, 38% (5-FU 5%) and 17% (placebo) of patients showed complete healing of all lesions on face and ears, respectively, and this difference was significant ($p < 0.01$). The lesion-related reduction rate was 73% for the active group (from an average of 11.1 to 3.0 AK per patient) and 24% for the control group (from an average of 10.7 to 8.1 AK per person). The difference was slightly smaller for hypertrophic AK. The number of treatments of all lesions ("spot treatments") over the 2-year observation period was lower in the 5-FU 0.5% group than with placebo (6491 versus 12204). Results on tolerability or side effects of treatment were not reported in this publication [180].

Assessment: Data on side effects or tolerability were not published at the time of the literature search. In addition, this study population is a high-risk population that is not immunosuppressed but is defined by a history of multiple epithelial skin. Therefore, the transferability of the results is likely limited. The study was therefore downgraded to an evidence level of 3.

5-Fluorouracil 5% cream vs. laser resurfacing

Population and study design: Ostertag et al. investigated the long-term efficacy and recurrence rates of 5-FU 5% cream compared with ablative laser therapy in 55 patients in a randomized, double-blind study [150].

Intervention: Patients were randomized interindividually 1:1 to 5-FU 5% cream twice daily for 4 weeks or for a maximum of 7 weeks, if less effective, and to ablative laser treatment with the Derma-K laser (Lumenis®) in Er:YAG or CO₂ mode.

Results: After 3 months, the mean lesion reduction per patient was 13.2 for 5-FU 5% and 13.8 for laser treatment. At 6 months, this number was 12.5 and 13.9, respectively, and at 12 months, 12.4 and 14.2 (5-FU 5% versus laser), respectively. The differences in absolute lesion reductions were not significant. The mean percent reduction at 12 months was 91.1% for laser therapy and 76.6% for 5-FU 5%. This difference was significant ($p = 0.048$). Similarly, recurrence rates at 3, 6, and 12 months were consistently higher for topical treatment with 5-FU 5% than for ablative laser therapy. Improvement with respect to UV-induced skin aging of treated areas was also observed more frequently after laser treatment. This endpoint was measured on a 0-9 scale composed of the individual components of wrinkles, skin color/pigmentation, and keratoses. At 12 months, scores on this scale improved significantly more often with laser (74%) compared to 5-FU 5% (43%). Side effects of both interventions included erythema, edema, infection, crusting, pain, skin irritation, and itching. They tended to be observed more frequently after laser treatment. In particular, edema and infections occurred more often shortly after treatment, and erythema and hypopigmentation occurred more often in the longer term [150].

Evaluation: The effectiveness of the interventions was not significantly different in terms of absolute lesion reduction; only the percentage reduction was reported to be superior for laser therapy. However, the magnitude of the effect appears to be rather small. Regarding long-term effects, laser therapy was significantly superior but at the expense of long-term side effects. Therefore, further studies are needed to investigate the harm-benefit ratio of these two interventions.

5-Fluorouracil 5% cream vs. cryosurgery

Population and study design: Krawtchenko et al. examined 5-FU 5% cream versus cryosurgery and imiquimod 5% cream in a three-arm study [136]. For more detailed information, see [Chapter 5.5.1](#).

Intervention: For more detailed information on the study interventions, see [Chapter 5.5.1](#).

Results: Complete clinical healing of all lesions was observed for 5-FU 5% in 96% (23/24 patients), for cryosurgery in 68% (17/25) and for imiquimod 5% in 85% (22/26 patients) of cases ($p=0.03$). Histopathologically confirmed complete healing rates per patient were 67% (5-FU 5%), 32% (cryosurgery) and 73% (imiquimod 5%; $p=0.02$), respectively. At 12 months after study end, 54% of all patients treated with 5-FU 5% and 28% of all patients treated with cryosurgery still showed sustained lesion response. The overall treatment field was still unremarkable after this time in 33% (5-FU 5%) and 4% (cryosurgery) of all study participants. Cosmetic outcome at 12 months was similarly poor for both interventions and was considered excellent in only 4% of cases. No serious adverse events were observed. Normal skin appearance after therapy was observed more frequently after 5-FU 0.5% arm than after cryosurgery (58% vs. 16%). Other adverse events were similarly distributed, although more precise numbers were not reported [136].

Assessment: In this study, efficacy benefits of 5-FU 5% cream were demonstrated with respect to the endpoints of complete clinical and histological healing of all lesions, with the treatment effect difference appearing robust (96% vs. 68% and 67% vs. 32%, respectively). Because cryosurgery is a primarily lesion-directed therapy and 5-FU 5% is a field-directed therapy, the two modalities have limited comparability in terms of field efficacy. In addition, bias is possible due to the open-label study design. Therefore, the study was downgraded to evidence level 3. Nevertheless, this study underscores the long-term efficacy of field therapy (here: 5-FU and imiquimod) over lesion-directed therapy (here: cryosurgery).

5-Fluorouracil 5% cream vs. imiquimod 5% cream

Population and study design: Two studies compared 5-FU 5% cream with imiquimod 5% cream [136], [181]. Krawtchenko et al. conducted an unblinded, three-arm, randomized trial. Seventy-five subjects with at least 5 histologically confirmed AK in an area no larger than 50 cm² on the head, neck, or décolleté were included. Immunosuppressed individuals were excluded [136]. Tanghetti et al. studied 39 patients with at least 4 lesions in an area of 25 cm² on the face, forehead and scalp in an observer-blinded randomized trial. Again, immunosuppressed individuals were excluded [181].

Intervention: Within the first study, patients were randomized interindividually 1:1:1 to 5-FU 5% cream twice daily for 4 weeks, imiquimod 5% cream three times weekly for at least 8 hours for 4 weeks, or spray liquid nitrogen cryosurgery (20-40 seconds per

lesion). The cryosurgery and imiquimod interventions could be repeated once after 2 and 4 weeks, respectively [136]. The second trial was randomized interindividually to 5-FU 5% cream twice daily for 2-4 weeks or imiquimod 5% cream twice weekly overnight for 16 weeks [181].

Results: Complete clinical healing of all lesions was observed in 96% (23/24 patients) for 5-FU 5%, 85% (22/26 patients) for imiquimod 5%, and 68% (17/25) of cases for cryosurgery ($p=0.03$). Histopathologically confirmed complete healing rates per patient were 67% (5-FU 5%), 73% (imiquimod 5%) and 32% (cryosurgery; $p=0.02$), respectively. At 12 months after the end of the study, 54% of all those treated with 5-FU 5% and 73% of all those treated with imiquimod 5% still showed a sustained response of the lesions. The overall treatment field was still unremarkable after this time in 33% (5-FU 5%) and 73% (imiquimod 5%) of all study participants. The cosmetic outcome at 12 months showed slight advantages for imiquimod 5%, as on a four-point scale (poor, moderate, good, excellent) in 81% the outcome was assessed as excellent by the investigators. For 5-FU 5%, this was the case in only 4%. No serious side effects were observed. Dyspigmentation occurred less frequently in the imiquimod group, although more precise figures on the occurrence of adverse effects were not reported [136].

In the second study, the median lesion reduction at 24 weeks was 94% for 5-FU 0.5% compared with 66% with imiquimod 5%, with a higher number of AK at therapy initiation in the first group (646 vs. 490 lesions). Complete healing of all lesions was achieved in 84% (5-FU 0.5%) and in 24% (imiquimod 5%), respectively. This difference was significant. In addition, those treated with 5-FU 0.5% responded more rapidly to therapy. A partial response, defined as a reduction of at least two-thirds of lesions per patient, was achieved at 24 weeks by 100% (5-FU 0.5%) compared with only 53% (imiquimod 5%). Global effectiveness assessment by investigators and patients also showed slight advantages for 5-FU 0.5%. The most common adverse events in both arms were erythema, crusting, erosion, and edema. Specifically, erythema was observed more frequently with treatment with 5-FU 0.5% [181].

Assessment: The study by Krawtchenko et al. (2007) showed slight advantages of imiquimod 5% cream over 5-FU 5% cream, especially in terms of cosmetic outcome and field-related efficacy. However, the study was conducted in an unblinded fashion, which could bias the assessment of the cosmetic outcome by the investigators and patients in particular. Strikingly, there was an extremely large effect difference of this endpoint, although the difference in terms of effectiveness (complete clinical healing of all lesions) was much smaller. In contrast, Tanghetti and Werschler (2007) demonstrated strong efficacy benefits of 5-FU 5% cream in all endpoints studied, but information on allocation of interventions is lacking, patients were not blinded and there is a risk for selective reporting of outcomes. Both studies were therefore downgraded to an evidence level of 3 and do not allow a clear conclusion on the superiority of 5-FU 5% cream over imiquimod 5% cream and vice versa.

5-Fluorouracil 5% cream vs diclofenac sodium 3% gel

Population and study design: Segatto et al. studied both interventions in a randomized, two-arm study of 31 patients (Fitzpatrick skin type I-III) with at least 5 AK on the face, scalp, or hands [171].

Intervention: Patients were randomized interindividually to treatment with diclofenac sodium 3% in hyaluronic acid 2.5% gel twice daily for 12 weeks or with 5-FU 5% cream twice daily for 4 weeks.

Results: The mean lesion count per patient decreased from 13.6 (start of therapy) to 6.6 (8 weeks after end of therapy) with diclofenac sodium 3% in hyaluronic acid 2.5% gel and from 17.4 to 3.2 with 5-FU 5%, so the percent mean reduction was significantly better with 5-FU 5%. Efficacy was evaluated globally by a blinded and a non-blinded investigator. Here, according to the blinded investigator, 5 patients achieved 100% improvement with 5-FU 5%, whereas no patient in the diclofenac arm did. Side effects were erythema (100%), edema (30%), crusts (92%), discomfort (53.8%), and pruritus (53.8%), each occurring more frequently in the 5-FU 5% arm. Twenty-eight patients completed the study according to protocol, and 3 patients discontinued the study, all of whom were treated with 5-FU 5%.

Assessment: In summary, there were slight efficacy benefits of 5-FU 5% cream. However, the open-label study design and the loss of 3 patients in one arm results in a risk for bias. The study population was also rather small with 31 participants. The level of evidence was therefore downgraded to 3 and the study appears to have limited power. In this study, 5-fluorouracil as a finished drug was compared with an extemporaneous (pharmacy) formulation. Thus, it is not an approved finished drug with documented quality.

5-Fluorouracil 5% cream vs. imiquimod 5% cream vs. MAL red light PDT vs. ingenol mebutate 0.015% gel

Population and study design: Jansen et al. investigated the efficacy of four commonly used field-oriented treatments in patients with a clinical diagnosis of ≥ 5 AK on the head in a contiguous area of 25 to 100 cm² (NCT02281682) in a Dutch, multicenter, single-blind, inter-individual RCT. The majority of patients were male (89.4% (558/624)) with a median age of 73 years (range 48-94). Skin types I and II were most common in the collective (skin type:I: 39.3% (245/624), II: 53.4% (333/624), III: 7.4% (46/624)) [177].

Intervention: A total of 624 patients were randomized to treatment with 5-FU 5% cream (twice daily for 4 weeks. (n=155)), imiquimod 5% cream (application 3 days per week for 4 consecutive weeks (n=156)), IMB 0.015% (once daily for 3 consecutive days (n=157)) and MAL-PDT (application of MAL under occlusion for 3 hours, followed by illumination with red LED with a wavelength of 635±18 nm (fluence 37 J/cm² for 7.23 minutes (n=156)).

Results: At 12 months after treatment completion, the cumulative probability of no treatment failure was significantly higher in patients treated with 5-FU 5% cream (74.7%; 95% CI 66.8 to 81.0) than in patients receiving imiquimod 5% cream (53.9%; 95% CI 45.4-61.6), MAL-PDT (37.7%; 95% CI 30.0-45.3), or IMB 0.015% gel (28.9%; 95% CI 21.8-36.3). Compared with 5-FU 5% cream, the hazard ratio for treatment failure was 2.03 (95% CI 1.36-3.04) for imiquimod 5% cream, 2.73 (95% CI 1.87-3.99) for MAL-PDT, and 3.33 (95% CI, 2.29-4.85) for IMB 0.015% gel. Three months after the end of therapy, at least 75% of AK had also healed most frequently in patients in the 5-FU 5% cream group (5-FU 5% cream: 90.6% (135/149) vs. imiquimod 5% cream: 75.8% (113/149) vs. MAL-PDT: 76.0% (117/154) vs. IMB 0.015% gel: 67.3% (101/150)). Also at 12 months, efficacy was most pronounced for patients receiving 5-FU 5% cream (5-FU 5% cream: 82.4% (108/131) vs. imiquimod 5% cream : 71.0%

(76/107) vs. MAL-PDT: 49.6% (57/115) vs. IMB 0.015% gel: 42.9% (42/98)). No serious side effects occurred and the side effects that did occur were consistent with known side effects. Aesthetic outcome was good for all treatments, but was rated best for MAL-PDT and IMB 0.015%.

Assessment: One strength of this study is the long follow-up time of the results over 12 months and the sample size. Furthermore, this RCT is the first to examine four therapeutic approaches in a head-to-head comparison. In addition, patient adherence was very strong. However, the patients were not blinded, which could possibly result in a performance bias. Nevertheless, these results reinforce the use of 5-FU 5%. In addition, further cost-effectiveness analysis in this four-arm study demonstrated the superiority of 5-FU compared with the other interventions [183].

5.6.2.2 5-Fluorouracil 4%

5.13	Evidence-based recommendation	new 2022
GoR B	5-Fluorouracil 4% cream should be offered for single and multiple actinic keratoses and for field cancerization.	
LoE 2	[184], [164] 2: De novo research	
	Strong consensus	

Since September 2020, 5-FU is also available in a concentration of 40mg/g in Germany as a lower-dosed but comparably effective cream for the treatment of patients with AK in the head and neck region. The preparation shows better local tolerability than the higher-dose cream. The approval for the 4% 5-FU does not include an area limitation for use on the face, ears, and scalp. Another advantage is that despite the lower dosage, the product needs to be applied only once a day. The duration of application is normally four weeks, but is based on tolerability. However, application in the case of recurrences has not yet been investigated in detail.

A network meta-analysis was identified in the systematic literature search, which included the new 5-FU formulation [164]. In the network meta-analysis, 5-FU 4% (odds ratio (OR) 22.58), 5-FU 5% (OR 28.84), 5-FU 0.5% (OR 12.66), 5-FU 0.5% + 10% SA (OR 5.88), ALA-PDT (OR 16.59), imiquimod 5% (OR 14.26), IMB 0.015% (OR 11.34) and MAL-PDT (OR 8.71) showed significantly higher complete patient-related healing rates compared with placebo. Here, 5-FU 5% followed by 5-FU 4% achieved the highest probability of complete healing. For the endpoint of partial patient-related healing rate, 5-FU 5% (OR 57.73), 5-FU 4% (OR 59.12), imiquimod 5% (OR 7.33) and IMB 0.015% (OR 22.51) also achieved the best efficacy compared with placebo. However, from a methodological point of view, this work should be criticized for not evaluating the individual risk of bias of the included studies using the gold standard, the Cochrane Risk of Bias Tool. Furthermore, no assessment of the quality of evidence of the endpoints, for example with the GRADE approach, was performed. Also, the calculated confidence intervals are quite large, which makes the accuracy of the odds ratios doubtful. Thus, no statement can be made regarding the actual confidence of

the results and thus the significance of the 5-FU formulations. The network meta-analysis includes data from a multicenter, double-blind, vehicle-controlled study of 841 patients, which compared 5-FU 4% cream once daily versus 5-FU 5% cream twice daily for 4 weeks [184]. After 4 weeks, both interventions showed similar patient-related complete (54.4% for 5-FU 4% vs. 57.9% for 5-FU 5%) and partial (80.5% for 5-FU 4% vs. 80.2% for 5-FU 5%) cure rates. However, the lower concentration of 4% showed improved tolerability and fewer side effects, especially fewer treatment-related discontinuations (10.1% with 4% 5-FU vs. 14.9% with 5% 5-FU) [184].

5.6.2.3 5-Fluorouracil 0.5%

5.14	Evidence-based statement	modified 2022
LoE 2	There is evidence for the efficacy of 5-fluorouracil 0.5% cream in single and multiple actinic keratoses. However, there is currently no approval for this concentration in Germany.	
	[122], [141], [179], [182], [185], [186], [187] 2: De novo research	
	Consensus	

Although 5-FU in the concentration 0.5% is not approved in Germany, the evidence situation will be briefly described and evaluated below. The systematic literature search revealed 4 individual studies that investigated 5-FU in the concentration 0.5% [185], [179], [182], [186]. In addition, 4 systematic review articles or meta-analyses were identified [141], [122], [187], [127]. Four studies were excluded either because they investigated sequential combination therapy of 5-FU 0.5% cream with cryotherapy [188], [189], or did not report any of the critical efficacy endpoints [190], [191].

Table 20: Overview of included individual studies on 5-FU (concentration 0.5%)

Study	Interventions	Single AK	Multiple AK	Field cancerization	Immunosuppression
Jorizzo 2002 [185]	5-FU 0.5% cream vs. placebo	unclear	X		
White 2002 [186]	5-FU 0.5% cream vs. placebo	unclear	X		
Loven 2002 [179]	5-FU 0.5% cream vs. 5-FU 5% cream		X		
Smith 2003 [182]	5-FU 0.5% cream vs. ALA + blue light vs. ALA + dye laser	X	X	unclear	

5-Fluorouracil 0.5% cream vs placebo

Population and study design: Two multicenter, double-blind, randomized trials compared 5-FU 0.5% cream versus placebo [185], [186]. Jorizzo et al. studied a cohort of 207 patients over 18 years of age with at least 5 AK (>4 mm in diameter) on the face or forehead. Most participants were Caucasians with a fair skin type [185]. The study by Weiss et al. involved 177 Caucasian patients similarly with at least 5 lesions on the face or forehead [186]. Information on immunosuppression of the study population is not found in the publications.

Interventions: In both studies, participants were randomized interindividually into 4 arms. In the active three groups, 5-FU 0.5% cream was applied once daily for 1, 2, or 4 weeks. The control group was treated with vehicle only.

Results: The percent lesion reduction from the start of therapy was 69.5% (1 week), 86.1% (2 weeks) and 91.7% (4 weeks) compared with only 21.6% with placebo. This difference was significant. Similarly, the rate of patients with complete healing of all lesions was higher in the active arms: 14.9% for 1 week, 37.0% for 2 weeks, 57.8% for 4 weeks and 0% for placebo. Global response was also rated significantly better by the investigators for 5-FU 0.5% cream. Local skin reactions such as dryness, erythema, erosions, edema, pain and burning were observed significantly more frequently in patients treated with 5-FU 0.5% (89% 1 week, 98% 2 weeks, 96% 4 weeks, 65% placebo). The median time to development of these side effects was 4 days. The study was terminated by 24 participants for adverse events, 12 of whom were in the 4-week treatment arm. Serious adverse events were observed in 5 cases but were not assessed as treatment-mediated [185].

In the study by Weiss et al., mean lesion reduction rates 4 weeks after the end of therapy compared with baseline were 78.5% (1 week), 83.6% (2 weeks), 88.7% (4 weeks) and 34.4% (placebo). On a patient-by-patient basis, the complete cure rate was 26.3% (1 week), 19.5% (2 weeks) and 47.5% (4 weeks) versus 3.4% for placebo. The investigators' global assessment of efficacy was also significantly better for the active therapy arms. No higher-grade adverse events occurred, and 7 patients terminated the study prematurely. Local side effects such as erythema, burning, or dryness were observed significantly more frequently with 5-FU 0.5% than in the control group, with the highest rate of side effects in the 4-week therapy arm (47.5%). Similar to the study by Jorizzo et al., local reactions developed 4-5 days after the start of therapy [186].

Assessment: Both studies are similar in terms of study design, population and endpoints. Although the studies were designed as double-blind, the different durations of therapy were not masked with vehicle cream. Furthermore, no information on how the blinding was conducted was provided in the publications. Therefore, both papers were downgraded to an evidence level of 3.

5-Fluorouracil 0.5% cream vs. 5-Fluorouracil 5% cream

Population and study design: A single-blinded, intraindividual randomized (split-face) study compared 5-FU cream at concentrations of 0.5% and 5% [179]. Twenty-one patients with at least 6 AK on the face or scalp (3 on each side) were included. Individuals with known decreased activity of DPD were excluded.

Intervention: treatment sides were randomized by computer. One side was treated with 5-FU 0.5% cream once daily (0.5%), the other with 5-FU 5% cream twice daily (5%) for 4 weeks.

Results: The mean absolute reduction in lesions compared with the start of therapy at 8 weeks was 8.8 (0.5%-FU) versus 6.1 (5%-FU). This difference was significant. Similarly, the percent lesion reduction was higher in the 0.5% group at 67% compared to 47% in the 5% group. The percentage of patients with complete healing of all lesions was 43% for both interventions. A total of 18 patients terminated therapy prematurely, and one patient withdrew completely from the study because of depression. The most common local side effects were erythema (100% and 100%), skin dryness (71.4% and 85.7%), erosion (81% and 95.2%), burning (66.7% and 85.7%), itching (66.7% and 85.7%), pain (42.9% and 57.1%) and edema (33.3% and 47.6%). Furthermore, eye irritation was observed in 5 patients and nasal obstruction in 2 patients. Side effects tended to be higher in the 5% group, but this difference was not significant. Patients preferred treatment with 5-FU 0.5% cream (85% vs. 15%), citing better tolerance with less skin irritation and easier, only once-daily application.

Assessment: Because of the small number of participants and the high number of patients who did not complete therapy according to protocol, the study was downgraded to an evidence level of 3. Although the lesion-related cure rate was higher below 0.5%, the effect difference compared to 5%-FU seems rather small. This is also evident from the same complete response rate of 43%, so the inferred superiority of 5-FU 0.5% over 5-FU 5% should be critically evaluated, especially since there is no other RCTs that provide a direct comparison of the two concentrations. Moreover, 5-FU 0.5% is not approved for the treatment of AK in Germany.

5-Fluorouracil 0.5% cream vs. ALA blue light PDT

Population and study design: A three-arm, randomized, open-label study evaluated 5-FU 0.5% cream versus ALA-PDT in 36 patients. The mean median age was 61 years. More detailed information on the study population, location, and distribution of lesions was not reported [182].

Intervention: Study participants were randomized interindividually into three arms. Two of them tested a one-hour incubation with 20% ALA followed by activation by either an artificial blue light source for 1000 seconds (blue light) or by a pulsed dye laser with a wavelength of 595 nm (laser). After 30 days, these two interventions were repeated. The third arm was treated with 5-FU 0.5% cream field-directed twice daily for 4 weeks (5-FU 0.5%).

Results: Complete healing of all lesions was achieved 4 weeks after the end of treatment by 50% (5-FU 0.5%), 50% (blue light) and 8% (laser) of treated patients. A partial response (reduction of at least 75% of lesions per patient) was present in 75% (5-FU 0.5%), 75% (blue light) and 42% (laser) of cases, respectively. Cosmetic improvement in terms of overall appearance after treatment, roughness of lesions, and hyperpigmentation was observed for all three treatment arms. Local side effects included erythema, burning, crusting, and erosions. Erythema was observed more frequently in patients treated with 5-FU 0.5%. One participant terminated the study prematurely because of marked redness of the entire face. More detailed frequency data on adverse events were not reported.

Assessment: Due to the three-arm, interindividual design of the study, the case size per treatment arm appears relatively small. In addition, a detailed description of randomization is missing and blinding was not performed. Therefore, the study was downgraded to an evidence level of 3.

5.6.3 5-fluorouracil with salicylic acid

5.15	Evidence-based recommendation	modified 2022
GoR B	5-Fluorouracil 0.5% with salicylic acid 10% in solution should be offered for single or multiple actinic keratoses as well as for field cancerization.	
LoE 2	[138], [175], [176], [192] 2: De novo research	
	Strong consensus	

The cytostatic agent 5-fluorouracil (5-FU) 0.5%, in combination with salicylic acid (SA) 10%, has been approved since 2011 for the topical treatment of mild to moderate AK (Olsen grade I to II) in immunocompetent adults. It is available as a solution (5 mg/g 5-FU with 100 mg/g SA) that should be applied once daily to a maximum treatment area of 25 cm² for a maximum of 12 weeks. Here, the keratolytic effect of SA enhances the cytostatic effect of 5-FU. The combination has been investigated in several randomized trials [138], [175], [192], [176] and in a meta-analysis of

randomized trials [193]. The body of studies illustrates that evidence exists for the use of 5-FU 0.5% with SA 10% solution in single and multiple AK, predominantly in mild to moderate lesions (Olsen grade I-II) and in lesion-directed application [175], [176]. Furthermore, Simon et al. showed the efficacy of this combination also in hyperkeratotic and grade III lesions, but more side effects were also observed here compared to cryosurgery [138]. Nevertheless, the incidence of treatment discontinuation due to intolerance is low (<1%) and side effects are mild to moderate in most treated patients. In addition, use can be reduced to up to 3x weekly if there is a response. Although a response should be visible as early as 4 weeks after therapy, the average duration of therapy tends to be long at 6-12 weeks. This assumes good adherence to therapy. Another study investigated 5-FU 0.5% with SA 10% in solution as field-directed therapy in patients with evidence of field cancerization [192]. No RCT was found for immunosuppressed patients.

Table 21: Overview of included individual studies on 5-FU with SA

Study	Intervention	Single AK	Multiple AK	Field cancerization	Immunosuppression
Stockfleth 2011 [175]	5-FU 0.5% with SA 10% solution vs. diclofenac sodium 3% in hyaluronic acid 2.5% gel vs. Placebo	X	X		
Stockfleth 2012* [176]	5-FU 0.5% with SA 10% solution vs. diclofenac sodium 3% in hyaluronic acid 2.5% gel vs. placebo	X	X		
Stockfleth 2017 [192]	5-FU 0.5% with SA 10% solution vs. placebo	X	X	X	
Simon 2015 [138]	5-FU 0.5% with SA 10% solution vs. cryosurgery	X	X		
* Follow-up study by Stockfleth 2011					

5-Fluorouracil 0.5% with salicylic acid 10% solution vs. placebo

Population and study design: Two independent studies were found comparing 5-FU 0.5% with SA 10% solution versus placebo. The first study examined 470 patients with

4-10 lesions on the face or hairless scalp. The primary endpoint was histological healing of a predefined AK lesion 8 weeks after the end of therapy. AK of grades I and II according to the Olsen classification were included. The study design was inter-individual and double-blind (grade I-II according to Olsen) [175]. The second study included 166 patients with 4-10 lesions on the face or hairless scalp in an area of 25 cm² with field cancerization. The primary endpoint of this study was complete clinical healing 8 weeks after the end of therapy. Grade I and II AK were included. The study was double-blind [192].

Interventions: In the first study, patients were randomized 2:1:2 to 5-FU 0.5% with SA 10%, vehicle (placebo) or diclofenac sodium 3% in hyaluronic acid 2.5% gel, which were indistinguishable externally. Therapy was applied once daily (5-FU 0.5% with SA 10% or placebo) or twice daily (diclofenac sodium 3% in hyaluronic acid 2.5% gel) for 12 weeks or until lesions healed. Treatment was lesion-directed; that is, the product was applied directly to clinically manifest AK with a brush applicator or the finger [175]. In the second study, randomization was 2:1 to 5-FU 0.5% with SA 10% or vehicle. Application was once daily over a contiguous area of no more than 25 cm², in which 4-10 AK or signs of field cancerization were present, and thus field directed, in contrast to the previous study [192]. In both papers, reduction of active therapy to three times weekly (5-FU 0.5% with SA 10%) or once daily (diclofenac sodium 3% in hyaluronic acid 2.5% gel) was possible.

Results: The histologically proven reduction rate at the end of the study was 72.0% (5-FU 0.5% with SA 10%) and 44.8% (vehicle), respectively, and the mean lesion reduction was equally significantly higher in the group of patients treated with 5-FU 0.5% with SA 10%. The number of patients with complete healing of all lesions at 20 weeks was significantly better in the active arm (55.4% vs. 15.1%). 74.5% of all lesions treated with 5-FU 0.5% with SA 10% had healed, compared with only 35.5% in the control group (vehicle). Global assessment of treatment success after 20 weeks was also highest in the 5-FU 0.5% with SA 10% group. 92.0% of investigators and 93.2% of patients gave an assessment as "very good" or "good". In contrast, local side effects such as burning and inflammatory reactions were also observed more frequently in the active arm. These were mostly mild to moderate. Itching occurred in both groups. Serious adverse events were recorded in 1.1% (5-FU 0.5% with SA 10%) and 4.1% (vehicle), respectively, but were not assessed as treatment-mediated [175]. A follow-up study reported later observation time points at 6 and 12 months within the same study population [176]. Based on healed lesions at week 20, lesion-related healing rates of 85.8% (5-FU 0.5% with SA 10%) versus 79.8% (placebo) were reported at 12 months ($p=0.04419$). Similarly, global assessment of treatment success at 6 and 12 months was significantly higher in active therapy, with 94.7% of treated patients recommending therapy with 5-FU 0.5% with SA 10%. However, local reactions such as burning (81.3% vs. 57.4%) or inflammatory reactions (70.3% vs. 22.3%) were again more frequently reported [176].

In the primary field-directed therapy study, the number of patients with complete healing of all lesions 8 weeks after the end of treatment was 49.5% (5-FU 0.5% with SA 10%) versus 18.2% (placebo) in the intention-to-treat analysis. Similarly, a reduction of at least 75% of clinically visible lesions was achieved in 69.5% vs. 34.6%. Both endpoints were significantly different. The percent lesion reduction relative to the start of therapy was 78.0% for active therapy vs. 46.9% with placebo. Global treatment response was also rated as "very good" or "good" by the investigator in 90.2% of patients treated with 5-FU 0.5% with SA 10%. Side effects of active therapy reported

were erythema (88.9%), pain (69.4%) and skin irritation (59.3%), all of which occurred more frequently than with placebo [192].

Assessment: One strength of these studies is a long follow-up period of results over 12 months. In the follow-up study, lesion-related healing rates based on healed lesions at week 20, were determined at 12 months. However, the strength of the effect of treatment with 5-FU 0.5% with SA 10% in solution appears to progressively decrease over the observation period. This is particularly evident at 12 months, where the lesion-related healing rates of active therapy and placebo and vehicle were close (85.8% vs. 79.8%, respectively). The high healing rate in the control arm could be due to either some efficacy of vehicle or a high natural remission rate (see [Chapter 5.2](#)). Therefore, further studies are needed to further investigate the long-term efficacy of 5-FU 0.5% with SA 10% in solution.

5-Fluorouracil 0.5% with salicylic acid 10% solution vs. cryosurgery

Population and study design: There is one randomized trial comparing 5-FU 0.5% with SA 10% with cryosurgery. Sixty-six patients with 4-10 hyperkeratotic lesions (grade II-III according to Olsen classification) on the face and hairless scalp were included. Individuals with iatrogenic immunosuppression were excluded [138].

Interventions: 5-FU 0.5% with SA 10% was applied as a solution lesion-directed once daily for a maximum of 6 weeks. If poorly tolerated, reduction to three times weekly administration was allowed. Cryosurgery was performed with liquid nitrogen as a spray procedure with a double freeze-thaw cycle, with the duration of icing left to the individual investigator. It could be repeated after 3 weeks, which was also at the discretion of the investigator. The study was not blinded. There was interindividual randomization to one of the two arms in a 1:1 ratio.

Results: The median lesion reduction per patient at 14 weeks was 5.2 for 5-FU 0.5% with SA 10% and 5.7 for cryosurgery. In the first arm, 33.3% showed complete and 51.5% partial (>75%) healing of all lesions after 98 days. For cryosurgery, it was 25.0% (complete) and 62.5% (partial). Histological remission rates were lesion-related 62.1% for 5-FU 0.5% and 41.9% for cryosurgery. The recurrence rate (proportion of patients with at least one recurrence) 6 months after the end of therapy was higher for cryosurgery than for 5-FU 0.5% with SA 10% (84.8% vs 39.4%). The overall response assessed by the investigator and patients was very similar in both arms. Similarly, the cosmetic outcome of both therapies was predominantly rated as "good" or "very good". Side effects tended to be more common with 5-FU 0.5% with SA 10% and included erythema, crusting and burning. Serious treatment-mediated events occurred in 24.2% of cases compared with only 6.1% with cryosurgery [138].

Assessment: In terms of mean lesion reduction and complete or partial healing of all lesions, the effectiveness of both interventions was comparable. Of note, there was a significant effect in the reduction of recurrences of originally healed lesions of 5-FU 0.5% with SA 10%, which may indicate a better long-term efficacy of this agent compared to cryosurgery. This was in contrast to a lower rate and side effects with cryosurgery, which should be considered in the harm-benefit assessment of this comparison. Because of the open-label study design, the work was downgraded to an evidence level of 3.

5-Fluorouracil 0.5% with salicylic acid 10% solution vs diclofenac sodium 3% gel

Population and study design: One study examined these interventions in a three-arm, interindividual design [175].

Interventions: Randomization was 2:1:2 to 5-FU 0.5% with SA 10%, vehicle (placebo), or diclofenac sodium 3% in hyaluronic acid 2.5% gel.

Results: The histologically proven reduction rate at study end was 72.0% (5-FU 0.5% with SA 10%) vs. 59.1% (diclofenac sodium 3% in hyaluronic acid 2.5% gel), and the clinically measured reduction rate was 74.5% (5-FU 0.5% with SA 10%) vs. 54.6% (diclofenac sodium 3% in hyaluronic acid 2.5% gel). The number of study patients with complete healing was 55.4% (5-FU 0.5% with SA 10%) vs. 32.0% (diclofenac sodium 3% in hyaluronic acid 2.5% gel). Lesion-wise, 74.5% and 54.6% of all AK had healed at 20 weeks, respectively. Global treatment response was consistently rated better by investigators for 5-FU 0.5% with SA 10%. Thus, in 92.0%, outcomes were found to be "very good" or "good"; in the diclofenac arm, this was the case in 73.8%. Similarly distributed was the global response assessed by patients (93.2% vs. 81.6%). In contrast, the rate of adverse events was higher in the experimental arm (95.2%) than in the active diclofenac arm (76.8%). Serious adverse events were observed in 1.1% (5-FU 0.5% with SA 10%) and 4.9% (diclofenac sodium 3% in hyaluronic acid 2.5% gel), respectively, but were not judged to be treatment-mediated. Thirty-five patients terminated the study prematurely, of whom 14 were treated with 5-FU 0.5% with SA 10% and 16 with diclofenac sodium 3% in hyaluronic acid 2.5% gel [175]. At 12 months, 85.8% and 81.0% of lesions originally healed at week 20 were still healed, respectively. Significant clinical improvement ("good/very good") was present in 93.2% and 81.6%, respectively, according to the investigators here (5-FU 0.5% with SA 10% vs. diclofenac sodium 3% in hyaluronic acid 2.5% gel). Patient assessment here was slightly lower for both groups [176].

Assessment: 5-FU 0.5% with SA 10% was significantly superior to diclofenac sodium 3% in hyaluronic acid 2.5% gel after 20 weeks with respect to the investigated efficacy endpoints.

5.6.4 Ingenol mebutate

5.16	Evidence-based recommendation	modified 2022
GoR A	Ingenol mebutate shall not be offered for actinic keratosis therapy.	
LoE 2	[122], [193], [194], [195], [196], [197], [198], [199], [200], [201] 2: De novo research	
	Strong consensus	

In January 2020, in consultation with the European Medicines Agency (EMA), it was decided to suspend the approval of ingenol mebutate (IMB) for AK. This decision was based on a 3-year safety analysis with 484 patients, which showed a higher incidence of SCC with IMB compared to imiquimod (3.3% vs. 0.4%). Furthermore, a higher incidence of skin tumors including basal cell carcinoma, Bowen's disease and SCC in

the treatment field was also observed compared with vehicle in four clinical trials with ingenol disoxate (an ester related to IMB) involving 1,234 patients (7.7% vs. 2.9% with vehicle). In addition, a higher incidence of benign tumors was noted with IMB (n=1,262 patients, IMB 1.0% vs. vehicle 0.1%). Although these data have not yet been published and are available only in two red-hand letters, the EMA currently recommends suspension of marketing authorization in Europe as a precautionary measure. Treated patients should be closely monitored for the occurrence of skin tumors in former treatment fields. Against the background of numerous interventions, IMB should not be offered and other therapies should be preferred.

5.6.5 Imiquimod

5.6.5.1 Imiquimod 5%

5.17	Evidence-based recommendation	modified 2022
GoR B	Imiquimod 5% cream should be offered for single or multiple actinic keratoses, as well as for field cancerization.	
LoE 1	[162], [164], [177], [122], [127], [135], [165], [181], [202], [203], [204], [205], [206], [207], [208] 1: De novo research	
	Strong consensus	

The specific toll-like receptor (TLR) 7 agonist imiquimod 5% has been approved since 2006 for the topical treatment of clinically typical, non-hyperkeratotic, non-hypertrophic AK (Olsen grade I to II) on the face or scalp in immunocompetent adults. It is available as a cream portioned in individual sachets (12.5 mg), which is the maximum dose per treatment day. Imiquimod 5% cream should be applied to a maximum treatment area of 25 cm² three times weekly for 4 weeks at a time and left on the skin for approximately 8 hours. After a four-week treatment-free period, the healing of the AK should be checked and, if necessary, a second treatment cycle over 4 weeks should be followed. Studies [202], [204] on this application regime show comparable therapy results with shorter therapy duration compared to the original 16-week [205], [206], [208] or 12-week treatment [207]. However, one study was able to show that the more frequent application of more than three times a week was less well tolerated, complete healing of lesions was poorer and only partial healing could be demonstrated. However, the corresponding AK were localized to the extremities and not to the face or capillitium [203].

Two systematic reviews [141], [193] and respectively, four meta-analyses [122], [209], [127], [164] of several randomized trials of different treatment modalities of AK underscore the evidence presented. A meta-analysis by Vegter et al. determined a complete healing rate of 63.3% for the treatment cycle of 16 weeks from a total of 5 studies with a pooled total population of 966 patients. However, complete healing of all lesions after only 4 weeks of treatment was calculated to be 56.3% from 3 studies with a total of 278 patients [127]. Comparable values (complete healing of lesions: 65.9% and complete healing in the patient: 54.5%) were also found in a systemic

review by Askew et al. who analyzed a total of 8 studies, using imiquimod 5% as a comparator arm of other treatments [141].

There is one study on field-directed therapy in immunocompromised patients that showed comparable results to immunocompetent patients in terms of complete healing of lesions over a 16-week treatment period [136]. An area of up to 100 cm² was treated with a maximum of two sachets (each 12.5 mg). However, except for mild to moderate effects, there were no serious side effects (especially rejection reactions in organ transplanted patients). For evidence-based recommendation on imiquimod 5% cream in this subgroup, see [Chapter 5.8](#).

Table 22: Overview of individual studies on imiquimod 5%

Study	Interventions	Single AK	Multiple AK	Field cancerization	Immunosuppression
Korman 2005 [205]	Imiquimod 5% cream 3x/week vs. placebo	X	X		
Lebwohl 2004 [206]	Imiquimod 5% cream 2x/week vs. placebo	X	X		
Szeimies 2004 [208]	Imiquimod 5% cream 3x/week vs. placebo	X	X		
Alomar 2007 [202]	Imiquimod 5% cream 3x/week (max. 2 cycles) vs. placebo	X	X		
Jorizzo 2007 [204]	Imiquimod 5% cream 3x/week (max. 2 cycles) vs. placebo	X	X		
Chen 2013 [210]	Imiquimod 5% cream 3x/week vs. placebo	X	X	unclear	
Ooi 2006 [211]	Imiquimod 5% cream 3x/week vs. placebo	X	X	unclear	

Study	Interventions	Single AK	Multiple AK	Field cancerization	Immunosuppression
Ortonne 2010 [212]	Imiquimod 5% cream 3x/week vs. placebo	X	X	unclear	
Stockfleth 2002 [207]	Imiquimod 5% cream 3x/week vs. placebo	X	X		
Gebauer 2009 [203]	Imiquimod 5% cream 2x/week vs. imiquimod 5% cream 3x/week vs. imiquimod 5% cream 5x/week vs. imiquimod 5% cream 7x/week vs. placebo		X	X	
Ulrich 2007 [213]	Imiquimod 5% cream 3x/week vs. placebo	X	X	X	X
Foley 2011 [135]	Imiquimod 5% cream vs. cryosurgery		X		
Krawtchenko 2007 [136]	Imiquimod 5% cream vs. cryosurgery vs. 5-FU 5% cream	X	X		
Akarsu 2011 [165]	Imiquimod 5% cream vs. diclofenac sodium 3% gel vs. placebo	X			

Study	Interventions	Single AK	Multiple AK	Field cancerization	Immunosuppression
Kose 2008 [167]	Imiquimod 5% cream vs. diclofenac sodium 3% gel	X	unclear		
Tanghetti 2007 [181]	Imiquimod 5% cream vs. 5-FU 5% cream	X	X		
Gollnick 2020 [162]	Imiquimod 5% cream vs. diclofenac sodium 3% gel	X	X		
Jansen 2019 [177]	5-FU 5% cream vs. IMB 0.015% gel vs. imiquimod 5% cream vs. MAL-cPDT		X	X	

Imiquimod 5% cream vs. placebo (immunocompetent)

Population, study design, and intervention: Several randomized studies of the efficacy of imiquimod 5% cream versus placebo can be identified. Of these, three studies [205], [206], [208] evaluated efficacy against placebo over a treatment period of 16 weeks, each with three or two applications per week. These studies included 492 patients, 436 patients and 286 patients randomized 1:1 against vehicle. Patients were treated on the face or hairless head and had between 4-81.2 and 5-9 AK, respectively, over an area of 25 cm².

Two other studies [202], [204] also investigated efficacy against placebo in patients with 4-85 or 5-94 AK on an area of 25 cm² on the face or on the hairless head; in these studies, application was with one to two cycles of therapy of 4 weeks each. After an initial treatment cycle of 4 weeks, each with three applications per week, an assessment was made after an additional 4 weeks to determine whether AK were still detectable in the treatment area. If so, another 4-week treatment cycle was performed. Again, a 1:1 randomization of imiquimod 5% versus placebo was done. None of the five studies mentioned had explicitly excluded hyperkeratotic AK (as defined by Olsen III).

Results: The three studies by Korman et al., Lebwohl et al. and Szeimies et al. demonstrated complete healing rates of 48.3% (imiquimod) vs. 7.2% (vehicle), 45.1% vs. 3.2%, and 57.1% vs. 2.2%, respectively, and partial lesion reduction of 64.0% vs.

13.6%, 59.1% vs. 11.8%, and 72.1% vs. 4.3%, respectively. In this regard, the assessment in all studies was performed 8 weeks after the end of treatment and was evaluated clinically in two of the three studies and by histology in Szeimies et al. Adverse events in the treatment arm were higher in the active treatment arm than in the vehicle arm in all three studies. The most commonly reported adverse events in the active arm in the treatment area were pruritus 20.5%-28.9%, burning 5.6%-7.4%, and erythema 30.6%, crusting 29.9% and erosion 10.2%.

The two studies by Alomar et al. and Jorizzo et al. showed overall (i.e., after either one or two cycles of treatment) complete healing of all lesions of 55.0% (imiquimod) vs. 2.3% (vehicle) and 57.7% vs. 14.6%, respectively. Regarding partial lesion reduction, values of 65.9% (imiquimod) vs. 3.8% (vehicle) and 61.0% vs. 25.2%, respectively, were achieved. Adverse events were observed in 53.5% (imiquimod) vs. 30.8% (vehicle) of cases. In the other study, 16% of patients rated adverse events (erythema, pruritus, crusting) as severe.

Three other studies compared Imiquimod 5% cream with placebo, but are not further reported here given a small study size, a relatively short follow-up period and comparable results to the studies already described [210], [211], [212].

Imiquimod 5% cream vs. placebo (immunosuppressed)

A multicenter, randomized, placebo-controlled trial by Ulrich et al. in 43 organ transplant patients evaluated the efficacy and interaction of the immunomodulator in this high-risk patient population [213]. Due to the need for field-directed therapy, this study used two sachets per application over an area of 100 cm². Randomization was 2:1 (30 patients in the active arm) and therapy was given three times per week for 16 weeks. Complete healing was reported in 62.1% of cases and partial healing in 79.3% of cases. Thus, the results are comparable or even better than in immunocompetent patients, although the application (2 sachets, larger area) differs from the established regimen. One important finding of this study is that the immunomodulatory mode of action of Imiquimod did not lead to any side effects in terms of organ rejection, functional impairment of the transplanted organ or relevant laboratory abnormalities [Chapter 5.8.2](#).

Imiquimod 5% cream vs. cryosurgery

Population and study design: One monocentric study of 70 patients was found comparing cryosurgery versus imiquimod 5% treatment in patients with 10 AK [135]. Lesions were classified clinically according to Olsen et al., with even Olsen grade III lesions (in the presence of ≥ 10 lesions) receiving preferential treatment. Another three-arm study compared imiquimod 5% with cryosurgery and 5-fluorouracil [136]. A total of 75 patients with 5-10 AK in a treatment field of 50 cm² were included. Randomization was 1:1:1 and AK were histologically confirmed before therapy.

Interventions: Randomization was 1:1 and treatment by cryosurgery was performed by open spray in up to four sessions three months apart. In contrast, imiquimod 5% cream was applied three times per week for 3-4 weeks, and if healing was not yet complete, another treatment cycle was performed [135]. In the three-arm comparative study, open spray cryosurgery was applied for 20-40 s per lesion and repeated one more time within 2 weeks if AK were still present. 5-Fluorouracil 5% cream was applied twice daily for 4 weeks in the treatment area. Imiquimod 5% cream was

applied three times a week for 4 weeks and again applied in the same manner after a four-week break if AK remained [136].

Results and assessment: The complete healing rate of the treated lesions was very high compared to other studies (98.7% cryosurgery and 93.6% Imiquimod), especially considering that hyperkeratotic lesions were also treated. Complete healing of a patient's lesions was also high (90.3% vs. 68.0%) and, in contrast, partial healing was considered low (9.7% vs. 28.0). As long-term side effects, hypopigmentation in the treatment area played a significant role and differed significantly in both treatment regimens (54.8% vs. 24.0%) [135]. The second study reported complete clinical healing rates of 68% for cryosurgery, 96% for 5-fluorouracil and 85% for imiquimod. In contrast, histological examination showed complete healing rates of only 32%, 67%, and 73%, respectively. Long-term complete healing at 12 months of total treatment field was reported at 4%, 33%, and 73%, respectively, which illustrates the long-term efficacy of field therapy (here: 5-FU and imiquimod) versus lesion-directed therapy (here: cryosurgery) [136].

Imiquimod 5% cream vs. diclofenac sodium 3% gel

Population and study design: Three independent studies were identified comparing imiquimod 5% cream vs diclofenac sodium 3% in hyaluronic acid 2.5% gel. The first study examined 61 patients, each with a lesion that had been previously confirmed histologically. Localization or clinical condition (Olsen classification) was not restricted. The study design was interindividual and blinded to the investigator [165]. The second study examined 49 patients with at least 3 lesions, and this study also did not restrict the localization or clinical nature of AK. Lesions were diagnosed and evaluated clinically. The study design was interindividual and not blinded [167]. The third study was a pooled analysis from two RCTs (NCT00777127/NCT01453179; LEIDA 1/2) with a total of 479 patients with Olsen grade I-II lesions in a contiguous field of 50 cm². Histological diagnosis confirmation was mandatory in this study [162]

Interventions: In the first study, patients were randomized 1:1:1 to imiquimod 5% cream, diclofenac sodium 3% in hyaluronic acid 2.5% or base cream. Treatment was lesion directed. Diclofenac sodium 3% in hyaluronic acid 2.5% gel and the base cream were applied twice daily for 12 weeks, and imiquimod 5% cream was applied twice weekly for 16 weeks [165]. In the second study, patients were randomized 1:1 and applied three times a week in the imiquimod arm and once a day in the diclofenac arm for 12 weeks each. Again, lesion-directed application was performed [167]. In the third study, randomization was 1:1 to either imiquimod 5% cream three times a week overnight for 4 weeks followed by 4 weeks off therapy. If response was inadequate, a second cycle of therapy was given. The other group received diclofenac sodium 3% gel twice daily for 12 weeks followed by an 8-week break in therapy [162].

Results: Clinically complete healing of lesions following therapy (diclofenac sodium 3% in hyaluronic acid 2.5% gel at 12 weeks, imiquimod at 16 weeks) was slightly higher in the imiquimod arm compared with diclofenac and base cream (20% vs. 19.1% vs. 0%). Follow-up at 24 weeks from study start showed a more pronounced difference (45% vs. 14.3% vs. 0%). Lesion thickness assessed clinically according to a semi-quantitative scale differed significantly only at the time of follow-up and was thinner in the imiquimod arm than in the diclofenac arm (p=0.034). The tolerability of the therapies was rated as good by the investigators and side effects were reported at a frequency of 75% (erythema, erosions, edema) for imiquimod and 28% (erythema,

scaling) for diclofenac sodium 3% in hyaluronic acid 2.5% gel [165]. In Kose et al. 2008 [167], assessment with the IGII 7-point clinical scale at the end of treatment comparing imiquimod versus diclofenac sodium 3% in hyaluronic acid 2.5% gel showed a proportion of moderate improvement of 5% to 36%, significant improvement of 73% to 52%, and complete improvement of 22% to 12%. Patients reported complete healing in 23% with imiquimod and in 28% with diclofenac sodium 3% in hyaluronic acid 2.5% gel. The investigators rated both therapies as well tolerated. Mild to moderate adverse events reported were erythema, pruritus, dry skin, and scaling, which resulted in at least one adverse event in 15 patients in the imiquimod arm and in 12 patients in the diclofenac arm [167]. In the third study by Gollnick et al. 2020 [162], the patient-related complete healing rate 20 weeks after the start of the study was 52.1% for imiquimod compared with 35.4% for diclofenac. Treatment-mediated adverse events occurred in 21% (imiquimod) and 18% (diclofenac), the most common being pruritus in 5.3% and 6.7%, respectively, at the application site. Overall, more patients discontinued therapy with diclofenac than with imiquimod (38.8% vs. 28.9%) [162].

Assessment: In summary, all three studies showed a small advantage for treatment with imiquimod in terms of complete healing rate, although caveats must be made regarding study design in duration of application, inclusion of lesions (localization: face vs. extremities; thickness: Olsen grade I vs. grade III), and standardization of assessments. The evidence level of the study by Kose 2008 et al. [167], was downgraded to evidence level 3 because of its open, unblinded design. In the study of the Turkish study group, a preparation available in Turkey was used.

Imiquimod 5% cream vs. 5-fluorouracil 5% cream

Population and study design: A total of 36 patients with at least 4 AK on an area of 25 cm² on the head were included in a multicenter study. It was randomized into a 5-fluorouracil and an imiquimod 5% arm in a 1:1 ratio [181].

Intervention: Treatment of the 25 cm² was with 5-fluorouracil 5% cream twice daily for a period of 2-4 weeks. Imiquimod 5% cream was applied field-directed twice weekly for 16 weeks.

Results and assessment: The mean reduction in the number of lesions was reported to be statistically significantly different at 94% (5-FU) and 66% (imiquimod), respectively. The complete healing rate of patients was reported as 84% versus 24%, and the partial healing rate was reported as 100% versus 53%, each of which was also significantly different. Compared to other studies [135] or compared to placebo, the values for imiquimod 5% proved to be low. The investigators reported comparable tolerability for both treatment modalities.

Imiquimod 5% cream vs. 5-fluorouracil 5% cream vs. MAL red light PDT vs. ingenol mebutate 0.015% gel

For more detailed information see [Chapter 5.6.2.1](#).

5.6.5.2 Imiquimod 3.75%

5.18	Evidence-based recommendation	modified 2022
GoR B	Imiquimod 3.75% cream should be offered for multiple actinic keratoses as well as for field cancerization.	
LoE 2	[214] , [215] , [216] 2: De novo research	
Strong consensus		

The specific TLR-7 agonist imiquimod 3.75% has been approved since 2012 for the topical treatment of clinically typical, non-hyperkeratotic, non-hypertrophic AK (grade I to II according to Olsen) on the face or hairless scalp in immunocompetent adults. In this case, the treatment area corresponds to an area of more than 25 cm², which should not exceed an area of 200 cm². The number of AK located in the treatment area is independent of efficacy [\[216\]](#). It is available as a cream portioned in individual sachets of 250 mg each. It is applied over two treatment cycles of two weeks once daily, separated by a two-week treatment-free period [\[215\]](#). A longer treatment interval (twice 3 weeks separated by a 3 week treatment break) were comparable in terms of efficacy, but showed a significantly higher rate of local skin reactions [\[214\]](#). The efficacy of field-directed application was shown in two randomized trials [\[214\]](#), [\[215\]](#) a systematic review of randomized trials [\[193\]](#) and a meta-analysis of randomized trials [\[127\]](#). No data on the use of imiquimod 3.75% cream in immunosuppression are available from RCTs.

A systematic review of randomized trials of multiple treatment modalities reported complete cure rates of 34.0%-35.6% for the included trials of imiquimod 3.75% versus placebo [\[214\]](#), [\[215\]](#) and a difference from the respective placebo arms of 28.5%-29.3% [\[193\]](#). A meta-analysis by Vegter et al. calculated a complete healing rate of 39.9% vs. a rate of 6.9% for placebo for both studies [\[214\]](#), [\[215\]](#) averaged across all studies examined [\[127\]](#).

Table 23: Overview of individual studies on imiquimod 3.75%

Study	Interventions	Single AK	Multiple AK	Field cancerization	Immunosuppression
Hanke 2010 [214]	Imiquimod 3.75% cream vs. imiquimod 2.5% cream vs. placebo		X	unclear	
Swanson 2010 [215]	Imiquimod 3.75% cream vs. imiquimod 2.5% cream vs. placebo		X	unclear	
Peris 2015 [216]	Imiquimod 3.75% cream vs. placebo		X	unclear	

Imiquimod 3.75% cream vs. placebo

Population and study design: Two independent studies were identified that compared the efficacy of imiquimod 3.75% versus imiquimod 2.5% and placebo. The first study included 490 patients with 9-20 AK in an area greater than 25 cm² on the face or on the hairless head. Patients were randomized in a 1:1:1 ratio [214]. The second study involved the analysis of 479 patients and had an identical design [215]. In both studies, assessment occurred 8 weeks after the second cycle of therapy.

Intervention: In the first study, patients in the two active treatment arms received field-directed treatment daily for 3 weeks, then paused therapy for 3 weeks regardless of treatment outcome, and then received daily therapy for an additional 3 weeks [214]. In contrast, the second study examined daily use in shortened therapy cycles of 2 weeks of therapy, 2 weeks of pause, and renewed 2-week therapy; also independent of the presence of AK after the first 2-week cycle [215].

Results and assessment: The first study reported complete healing rates of 25.0% (imiquimod 2.5%) vs. 34% (imiquimod 3.75%) vs. 5.5% (placebo). Partial healing of 42.7% vs. 53.7% and 12.8%, respectively, and a mean reduction in lesions compared with baseline of 66.7% vs. 80% and 23.6%, respectively, were observed. Significant differences for both imiquimod concentrations compared with placebo were seen in all 3 outcomes (complete and partial healing and for lesion reduction). The two active arms showed increased adverse events corresponding to the higher concentration (28.2% vs. 44.7% erythema; 23.9% vs. 30.4% erosions; 22.7% vs. 30.4% crusting) [214]. Swanson et al. reported comparable complete healing rates of 30.6% (imiquimod 2.5%) vs. 35.6% (imiquimod 3.75%) and 6.3% (placebo), respectively. Partial healing (48.1% vs. 59.4% vs. 22.6%) and mean lesion reduction scores compared with baseline

(71.8% vs. 81.8% vs. 25.0%) were also comparable to those with longer cycles of therapy. However, local skin reactions were significantly lower (14.4% vs. 25.2% erythema; 9.4% vs. 10.7% erosion; 9.4% vs. 13.8% crusting) [215]. With comparable efficacy, this justifies the use in the context of twice 2 weeks of therapy with a two-week therapy break between cycles.

Another study by Peris et al. [216], examined the data from the work of Swanson et al. [215], and Stockfleth et al. 2014 in terms of efficacy and number of lesions treated. The study design or interventions are the same as those in Swanson 2010 [215]. It is a matter of applying the so-called L_{max} -concept for the evaluation (L_{max} : lesion reduction of clinical and subclinical lesions; for this purpose, subclinical AK becoming visible under therapy after the first week of therapy and existing clinically visible AK are counted to determine the actual total number of all therapeutically relevant AK). Second, this analysis divides and compares the patient population into patients with ≤ 10 AK ($n=162$) and with > 10 AK ($n=152$). This results in a comparable mean lesion reduction of L_{max} (first week of treatment) vs. 8 weeks after end of treatment of 91.5% (≤ 10 AK) vs. 93.0% (> 10 AK). Looking at lesion reduction from baseline vs. 8 weeks after end of treatment, 78.9% vs. 82.6% are reported [216].

5.6.6 Tirbanibulin

5.19	Evidence-based recommendation	new 2022
GoR B	Tirbanibulin 1% ointment should be offered for single or multiple actinic keratoses, as well as for field cancerization.	
LoE 2	[217] 2: De novo research	
	Strong consensus	

Tirbanibulin (KX2-391) is a dual small molecule inhibitor that inhibits intracellular protein tyrosine kinase Src and tubulin polymerization. Increased Src activity has been found in both primary tumor growth and metastasis [218]. Because Src is expressed more abundantly in AK and it appears to play a role in progression to cSCC (16), the efficacy of topical therapy with tirbanibulin in AK has now been investigated. A phase II open-label study was initially conducted in the United States in 168 patients with 4–8 AK on an area of 25 cm² on the face or scalp. Eight weeks after treatment initiation with tirbanibulin 1% ointment, the complete patient-related cure rate (100%) was higher in the five-day treatment cohort ($n=84$) than in the three-day treatment cohort (43% versus 32%) [217]. Local skin reactions were mild and mostly included erythema, scaling, crusting and swelling that resolved quickly. Side effects occurred infrequently and were mostly mild, such as transient itching, tenderness and pain. Based on the results of the Phase II study, two identical, multicenter, double-blind, vehicle-controlled Phase III studies were initiated with the 1% ointment in a total of 702 patients with AK on the face and scalp, which reaffirmed the efficacy and safety of tirbanibulin 1% ointment compared to vehicle (see Tirbanibulin 1% ointment vs. placebo).

Tirbanibulin is the first clinical Src inhibitor from the class of peptidomimetics. Due to its mode of action, namely blocking the substrate-binding site instead of the ATP-binding site as with previous kinase inhibitors, tirbanibulin is able to inhibit Src kinase much more specifically and already at lower concentrations, in contrast to multikinase inhibitors [218], this results in fewer off-target effects and therefore a more favorable side effect profile. The patient-related cure rates achieved with tirbanibulin in the pivotal study are comparable to already approved topicals. As of July 16, 2021, tirbanibulin is approved for the topical treatment of non-hyperkeratotic, non-hypertrophic AK (Olsen Grade I) on the face or scalp in adults with an area limit of 25 cm².

Table 24: Overview of included single studies on tirbanibulin

Study	Interventions	Single AK	Multiple AK	Field cancerization	Immuno-suppression
Blauvelt 2021 [217]	Tirbanibulin 1% ointment vs. placebo		X	X	

Tirbanibulin 1% ointment vs. placebo

Based on the results of the Phase II study, two identical, multicenter, double-blind, vehicle-controlled Phase III studies were initiated with the 1% ointment in a total of 702 patients with AK on the face and scalp [217]. Participants received tirbanibulin ointment 1% or vehicle (1:1) to be self-applied once daily for 5 consecutive days. After 57 days, complete (100%) as well as partial ($\geq 75\%$) healing rates were significantly higher in patients receiving tirbanibulin in both studies (tirbanibulin vs vehicle, complete healing rates: 44–54% vs 5–16%; partial healing rates: 68–76% vs 11–16%). After 1 year, recurrence occurred in 124 of the 174 tirbanibulin-treated patients who previously had complete responses. The most common local reactions to tirbanibulin were erythema in 91% of patients and scaling in 82%. Most treatment-related adverse events were mild to moderate transient application site pruritus or pain that did not require additional treatment.

5.7 Photodynamic therapy

5.20	Evidence-based recommendation	modified 2022
GoR B	Photodynamic therapy with red light illumination using 5-aminolevulinic acid (ALA) or its methyl ester (MAL) should be offered for single or multiple actinic keratoses and for field cancerization.	
LoE 1	[219] , [122] , [137] , [140] , [141] , [144] , [174] , [180] , [182] , [199] , [220] , [221] , [222] , [223] , [224] , [225] , [226] , [227] , [228] , [229] , [230] , [231] , [232] , [233] , [234] , [235] , [236] , [237] , [238]	
	1: De novo research	
	Strong consensus	

5.21	Evidence-based recommendation	modified 2022
GoR B	Photodynamic therapy with natural or simulated daylight with 5-aminolevulinic acid (ALA) or its methyl ester (MAL) should be offered for single or multiple actinic keratoses, as well as for field cancerization.	
LoE 1	[239] , [240] , [241] , [200] , [242] , [243] , [244] , [245] , [246] , [247]	
	1: De novo research	
	Strong consensus	

5.7.1 Photodynamic therapy with methyl aminolevulinate

Methyl aminolevulinate (MAL) in combination with red light has been approved since 2003 for topical PDT of mild to moderate AK (grade I to II according to Olsen) in immunocompetent adults. It is available as a cream (1 g cream contains 160 mg methyl (5-amino-4-oxopentanoate) as hydrochloride) and, in the case of conventional PDT, is applied to the lesion area (for field cancerization up to approximately 20 cm²) after lesion pretreatment (removal of scales and crusts and roughening of the surface) with a layer thickness of 1 mm.

After an exposure time of 3 hours under a light-tight occlusive dressing and wiping off excess ointment residues, illumination with red light (continuous wavelength spectrum between 570 and 670 nm and a total light dose of 75 J/cm²; alternatively, narrow-spectrum light (e.g., by means of LED lights around 630 nm) can be used, with adjustment of the light dose (usually 37 J/cm²). Light sources with a broader emission spectrum are also possible, but the evidence here is limited [\[236\]](#). Due to selective porphyrin synthesis in the abnormal keratinocytes of AK, illumination causes a localized phototoxic reaction resulting in necrosis and apoptosis. This is a single treatment; repeat treatment after 3 months is possible. In contrast, twice weekly therapy showed little benefit in thick lesions [\[235\]](#). One study demonstrated slight benefits with field-directed versus primarily lesion-directed application of MAL-PDT in a conventional setting [\[237\]](#).

Conventional MAL-PDT has been studied versus placebo or other interventions in several RCTs [229], [230], [140], [227], [234], [232]. Here, the study evidence highlights evidence for the use of MAL cream for PDT in single and multiple AK, predominantly in mild to moderate lesions (grade I-II according to Olsen) [229], [230], [234], [232]. Moreover, Kaufmann et al. demonstrated the efficacy of MAL-PDT also for AK on the extremities [140]. Similarly, Kohl et al. studied the efficacy of MAL in combination with pulsed light ("intensified pulsed light", IPL) in AK on the back of the hands [238]. Dragieva et al. investigated the use of MAL-PDT in immunosuppressed transplant recipients [248]. One study compared MAL-PDT with ALA-PDT as field-directed therapy in a half-scalp trial ("split-scalp"-design) [227]. The evidence for MAL-PDT in conventional delivery is presented below on an intervention basis.

Table 25: Overview of included individual studies on MAL-PDT

Study	Interventions	Single AK	Multiple AK	Field cancerization	Immunosuppression
Pariser 2008 [234]	MAL-PDT vs. vehicle-PDT	X	X		
Pariser 2003 [233]	MAL-PDT vs. vehicle-PDT	X	X		
Szeimies 2009 [232]	MAL-PDT vs. vehicle-PDT	X	X		
Dragieva 2004 [248]	MAL-PDT vs. vehicle-PDT		X	unclear	X
Kaufmann 2008 [140]	MAL-PDT vs. cryosurgery	X	X		
Morton 2006 [249]	MAL-PDT vs. cryosurgery	X	X		
Dirschka 2012 [230]	MAL-PDT vs. BF-200 ALA-PDT vs. vehicle-PDT	X	X		

Study	Interventions	Single AK	Multiple AK	Field cancerization	Immunosuppression
Dirschka 2013* [229]	MAL-PDT vs. BF-200 ALA-PDT vs. vehicle-PDT	X	X		
Moloney 2007 [227]	MAL-PDT vs. 20% ALA-PDT	X	X	unclear	
Zane 2014 [174]	MAL-PDT vs. diclofenac sodium 3% gel	X	X		
Zane 2016 [199]	MAL-PDT vs. IMB 0.015% gel		X	X	
Cabbage 2016 [238]	MAL-PDT with IPL vs. vehicle-PDT with IPL	X			
Seubring 2016 [237]	MAL-PDT lesion-directed vs. MAL-PDT field-directed	X	X	X	
Tarstedt 2005 [235]	MAL-PDT once vs. MAL-PDT twice with interval 1 week	X	X		
von Felbert 2010 [236]	MAL-PDT irradiated with broadband spectrum (580-1400 nm) vs. MAL-PDT irradiated		X	X	

Study	Interventions	Single AK	Multiple AK	Field cancerization	Immunosuppression
	with narrow spectrum (590-660 nm) each ± spray-cooling				
Jansen 2019 [177]	5-FU 5% cream vs. IMB 0.015% gel vs. imiquimod 5% cream vs. MAL-PDT		X	X	
Miola 2018 [250]	MAL-PDT vs. colchicine 0.5% cream	X	X		

* Follow-up study by Szeimies 2010 and Dirschka 2012; abbreviations: IMB=ingenol mebutate, IPL=intense-pulsed light.

MAL-PDT vs. placebo (immunocompetent)

Population and study design: Several independent studies were found comparing MAL-PDT versus placebo [234], [233], [232]. They studied 100 [234] or 80 [233] patients with 4-10 lesions on face or hairless scalp. Non-pigmented, non-hyperkeratotic grade I and II AK according to the Olsen classification were included. The study design was inter-individual and double-blind in both cases. Another study included 115 patients with identical parameters [232].

Interventions: Patients were randomized 1:1 to MAL-PDT or vehicle (placebo). After 3 hours of incubation, LED light was used to illuminate and treatment was repeated after 1 week [234], [233], [232].

Results: After 3 months, the complete lesion response rate was recorded. This was 86.2% (MAL) vs. 52.2% (placebo) [234] and 83.3% vs. 28.7% [232]. The high proportion of placebo healing rate in the Pariser et al. study was explained by lesion pretreatment. On a patient basis, 59.2% vs. 14.9% healed in the Pariser et al. study and 68.4% vs. 6.9% in the Szeimies et al. study. Main side effects in both studies were pain, erythema, and burning in the active groups.

MAL-PDT vs. placebo (immunosuppressed)

Population and study design: A prospective, monocentric, randomized, double-blind, placebo-controlled intraindividual comparative study was conducted in 17 organ

transplant patients under chronic immunosuppression (129 mild to moderate AK) [248].

Interventions: Two lesion-bearing areas received two PDTs one week apart with white light (75 J/cm²). One area was treated with MAL, the other with placebo cream.

Results: The complete lesion-related response rate was evaluated 16 weeks after the second treatment; it was 90.3% for the MAL site and 0% for the placebo site. Side effects were not precisely quantified. However, pain, erythema, edema and crusts were more pronounced in the verum region [248]. For evidence-based recommendations on MAL-PDT in immunosuppressed individuals, see [Chapter 5.8](#).

MAL-PDT vs. cryosurgery

For more detailed information comparing these interventions, see [Chapter 5.5.1](#).

MAL-PDT vs. ALA-PDT

Population and study design: One study examined these interventions for mild to moderate AK of the face and capillitium in a three-arm, interindividual design [230]. This was a multicenter, randomized, investigator-blinded, placebo-controlled trial of BF-200 ALA-containing gel (7.8%) vs MAL (16%) vs placebo. Illuminations could be either red light from LED lights or broad spectrum lamps [230]. Another monocentric study compared the efficacy of an ALA-PDT with that of a MAL-PDT in a field-directed approach, double-blind in a half-side trial ("split-scalp" design) [227].

Interventions: Randomization was 3:3:1 to MAL-PDT, ALA-PDT, or ALA vehicle (placebo) [230]. 1:1 comparison intraindividually in the study by Moloney et al. [227].

Results: In the study by Dirschka et al., clinical complete healing of AK on a per patient basis at 3 months was 78.2% for BF-200 ALA vs. 17.1% placebo (p<0.0001) and 64.2% for MAL (p<0.05). Healing rates on the face or forehead were better than on the capillitium for both sensitizers. Statistically relevant differences in cosmetic outcome, incidence of side effects and mean pain score (VAS) were not evident between the two sensitizers [230]. At 12 months, the overall healing rate for BF-200 ALA was 47% (although further inclusion of a placebo-controlled comparator in this evaluation), and that for MAL was 36% [229]. In the subgroup analysis at 12 months, the healing rate using the LED lighting systems was significantly better than for the broad spectrum lamps 60.3% vs. 56.3% for BF-200 ALA and 59.3 vs. 50.7 for MAL [230]. Moloney et al. achieved complete healing of treated AK fields with ALA in 40% of cases (MAL 46.7%). The mean reduction in the number of AK from baseline was 6.2 for ALA vs. 5.6 for MAL (no statistically significant difference) [227].

MAL-PDT vs. diclofenac sodium 3% gel

Population and study design: Zane et al. conducted an open-label, monocentric, randomized trial comparing these interventions in 200 patients with a total of 1,674 lesions. There were 58 women in this cohort, and the age range was 42-93 years. Patients had at least 5 AK of all grades on the face or hairless scalp and signs of actinic damage [174].

Intervention: Interindividual randomization was 1:1 to either MAL-PDT in a standard conventional manner (MAL cream 160 mg/g, 3 hours incubation, illumination with red light at a dose of 37 J/cm²) or treatment with diclofenac sodium 3% in hyaluronic

acid 2.5% gel twice daily for 90 days. In case of insufficient success, MAL-PDT could be repeated once after 3 months.

Results: After 3 months, 68% of patients treated with MAL-PDT but only 27% of those treated with diclofenac sodium 3% in hyaluronic acid 2.5% gel showed complete response of all AK. Lesion-related healing rates were 85.9% (MAL-PDT) and 51.8% (diclofenac sodium 3% in hyaluronic acid 2.5% gel). The cosmetic outcome was also judged to be significantly better for MAL-PDT compared to diclofenac sodium 3% in hyaluronic acid 2.5% gel by both the respective investigator and the patients themselves. However, the study was not blinded. Subjective patient satisfaction was also better with treatment with MAL-PDT. Here, 59% of all patients rated the outcome of the intervention as excellent in contrast to only 6% under diclofenac sodium 3% in hyaluronic acid 2.5% gel. Interestingly, this study also compared the cost-effectiveness of the two therapies. Again, advantages were seen for MAL-PDT, which achieved a complete response at a lower cost than diclofenac sodium 3% in hyaluronic acid 2.5% gel [174].

Assessment: Because of the open study design, there may be bias from the patient satisfaction and cosmetic outcome endpoints. There were also differences in lesion pretreatment between the two study arms (see evidence tables). In addition, there is a high potential for bias due to the high proportion of hyperkeratotic AK (moderate/thick) and sequential PDT therapy preceded by curettage for scaling/crusting. Therefore, the study was downgraded to evidence level 3.

MAL-PDT vs. ingenol mebutate 0.015% gel

One study was identified [199]. For comparison of these interventions, see [Chapter 5.6.4](#).

MAL-PDT vs. colchicine 0.5% cream

Miola et al. studied MAL-red light PDT versus colchicine 0.5% cream in 36 patients with AK on the forearms [250]. The two interventions were randomized 1:1 in intraindividual comparison. The patient-related complete healing rate was 17% (colchicine) versus 19% (MAL-PDT), and the partial healing rate was 44% versus 67%. The lesion-related healing rate was 45% for colchicine and 40% for MAL-PDT. Side effects were at a similar incidence in both arms. The low healing rates in this study demonstrate that AK is more difficult to treat on the forearms than on the face or capillitium. Both interventions were similar in terms of efficacy endpoints, but colchicine is not approved as a topical treatment for AK.

MAL-PDT vs. 5-fluorouracil 5% cream vs. imiquimod 5% cream vs. ingenol mebutate 0.015% gel

For a comparison of this intervention, see [Chapter 5.6.2.1](#) [177].

5.7.2 Photodynamic therapy with 5-aminolevulinic acid

The principle of PDT is based on the application of light-sensitizing substances. These photosensitizers accumulate selectively in the diseased epidermis in atypical keratinocytes and are activated by illumination with light of suitable wavelength. In this process, photochemical and photophysical processes generate reactive oxygen species (ROS), which lead to cell damage and cell death of precancerous changes. In the therapy of AK, the external application of ALA or its methyl ester MAL has become

established. ALA is a precursor (prodrug) of endogenous heme synthesis, which is converted in the skin to the actually active photoactive porphyrins such as protoporphyrin IX.

Classical formulations of ALA in creams, gels, solutions or ointments are not very stable and are rapidly degraded in the microenvironment of the skin. In addition, ALA is somewhat more hydrophilic than MAL and therefore has relatively poorer penetration properties, especially in thicker, hyperkeratotic lesions. Nevertheless, several studies showed good efficacy of conventional 20% ALA formulations compared to placebo [222], [223], [224], [225], [226]. In the USA, a 20% ALA solution in combination with blue light illumination is approved. In Germany, however, conventional ALA mixtures are available only as individual formulations or extemporaneous preparations (R007). Typical protocols here include exposure times of 3-4 hours under occlusion with an opaque dressing followed by illumination by red light.

Our literature search revealed two papers that investigated the influence of different illumination parameters on efficacy and side effects such as pain. In a study of 88 Caucasian patients, different sources of red light were evaluated after application of a 20% ALA gel. After 5 hours, the gel was removed and followed by irradiation with either a broadband spectrum water cuvette (595-1400 nm) at a dose of 350 J/cm² for 30 minutes or an incoherent halogen light source (600-720 nm) at a dose of 100 J/cm² for 10-11 minutes. Both groups showed similar complete response rates of 79-97%. However, illumination with the broadband spectrum was found to be less painful [221]. Similarly, another paper reported that painfulness was related to illumination intensity and increased at higher fluence rates up to 75 mW/cm² [220], .

Since 2012, a nanoemulsion equivalent to a 10% ALA preparation has been available (BF-200 ALA). A network meta-analysis has shown this formulation of ALA to be effective in mild to moderate AK with complete healing rates per patient around 75.8% (95% CI: 55.4-96.2%) vs. 6.9% (95% CI: 5.5-8.3%) with placebo [127]. BF-200 ALA is approved for the treatment of mild to moderate AK and field cancer on the face or scalp and on the trunk, extremities, and neck. The approval extension for ALA nanoemulsion in extrafacial localization is based on a phase III study in 50 patients in which the patient-related complete healing rate was 67.3% vs. 12.2% with placebo (p<0.0001) [251]. There are also data for the conventional 20% ALA formulation in combination with blue light illumination from an RCT with 269 patients. Here, the patient-related complete healing rate at 12 weeks was 31% versus 13% with placebo (p<0.0001) [252]. A network meta-analysis synthesizing the effectiveness of interventions for AK localized outside the head and neck area showed patient-related complete healing rates for MAL-PDT between 19-100% and for ALA-PDT between 0-67% compared to 0-12% for vehicle [129]. Lesion-related healing rates were 70-85% for ALA-PDT and 33% for MAL-PDT compared with 33% for placebo. Partial healing rates (≥ 75%) were 67-100% for MAL-PDT, 27-51% for ALA-PDT, and 75% for vehicle. In 2020, PDT with BF-200 ALA received an extension of approval for the treatment of AK localized outside the head and neck region [253]. This study was not identified in the systematic literature search.

ALA is applied to the area of the lesion or whole carcinomatized fields of up to 20 cm² with a film thickness of 1 mm, incubated for 3 hours under an opaque dressing, and then illuminated. Here, red light sources with a narrow spectrum at 630 nm at a dose of 37 J/cm² are preferable, as higher patient- and lesion-related response rates (84.8-90.9% and 93.6-96.3%, respectively) were consistently achieved in the relevant

studies than with broader spectra [229], [230], [231], [228]. Although much of the response persisted even after 6 and 12 months of follow-up, one should monitor the success of therapy after 3 months and repeat a cycle of therapy if lesions are still persistent. After 12 months, the recurrence rate for PDT with BF-200 ALA was 22% [229].

A self-adhesive patch with ALA is available for lesion-directed therapy of single mild to moderate AK. It measures 4 cm² and contains 8 mg of the active ingredient. An incubation time of 4 hours prevailed over shorter application times in a multicenter, randomized study in 149 participants with single lesions (3-4 per patient, 530 total). The percentage of patients with complete healing here was 74%. Also lesion-wise, 86% of all treated AK showed complete healing [254]. In terms of effectiveness in mild to moderate lesions, the patch also showed slight advantages over cryosurgery, lasting up to 12 months after therapy [219], [255]. Up to six patches can be applied per session, which are left in place for 4 hours and then irradiated with a narrow-band light source with a spectrum of approximately 630 nm (red light) and a dose of 37 J/cm². Local side effects such as redness, burning and itching occur in almost all cases. In addition, headaches have been reported more frequently with this therapy [254], [219]. Hypopigmentation was observed significantly less frequently than under cryosurgery [219]. An advantage of this procedure is the standardization of the procedure and the reduction of possible sources of error in the application of the photosensitizer.

No RCT were identified in which ALA-PDT were explicitly studied in immunocompromised patients. The individual studies on which the above recommendations are based are briefly described below.

Table 26: Overview of included individual studies on ALA-PDT

Study	Interventions	Single AK	Multiple AK	Field cancerization	Immunosuppression
Szeimies 2010 [228]	BF-200 ALA-PDT vs. vehicle-PDT	X	X		
Dirschka 2012 [230]	BF-200 ALA-PDT vs. MAL-PDT vs. vehicle-PDT	X	X		
Dirschka 2013* [229]	BF-200 ALA-PDT vs. MAL-PDT vs. vehicle-PDT	X	X		
Reinhold 2016 [231]	BF-200 ALA-PDT vs. vehicle-PDT	X	X	X	

Study	Interventions	Single AK	Multiple AK	Field cancerization	Immunosuppression
Moloney 2007 [227]	20% ALA-PDT vs. MAL-PDT	X	X	unclear	
Jeffes 2001 [222]	20% ALA-PDT vs. vehicle-PDT (each randomized to blue light at 2, 5, 10 J/cm ²)	X	X		
Pariser 2016 [223]	20% ALA-PDT field-directed 1h incubated vs. 20% ALA-PDT field-directed 2h incubated vs. 20% ALA-PDT field-directed 3h incubated vs. 20% ALA-PDT lesion-directed 2h incubated vs. vehicle-PDT		X	X	
Piacquadio 2004 [224]	20% ALA-PDT vs. vehicle-PDT	X	X	X	
Schmieder 2012 [225]	20% ALA-PDT with occlusion vs. 20% ALA-PDT without occlusion vs	X	X		

Study	Interventions	Single AK	Multiple AK	Field cancerization	Immunosuppression
	vehicle-PDT with occlusion vs. vehicle-PDT without occlusion				
Taub 2011 [226]	20% ALA-PDT 2 cycles vs. vehicle-PDT 2 cycles	X	X		
Holzer 2016 [144]	20% ALA-PDT vs. trichloroacetic acid	X	X	X	
Smith 2003 [182]	20% ALA-PDT (blue light) vs. 20% ALA-PDT (pulsed dye laser 595 nm) vs. 5-FU 0.5% cream	unclear	unclear	unclear	unclear
Brian Jiang 2020 [252]	20% ALA-PDT (blue light) vs. placebo	X	X		
Hauschild 2009 [219]	ALA patch incubated for 4 h vs. ALA patch incubated for 2 hrs. ALA patch incubated for 1.5 h vs. ALA patch incubated for	X			

Study	Interventions	Single AK	Multiple AK	Field cancerization	Immunosuppression
	0.5 h				
Giehl 2014 [221]	20% ALA-PDT irradiated with broadband spectrum (595-1400 nm) vs. 20% ALA-PDT irradiated with incoherent light source (600-720 nm)	unclear	unclear	unclear	
Apalla 2011 [220]	20% ALA-PDT 25 mW/cm ² vs. 20% ALA-PDT 50 mW/cm ² vs. 20% ALA-PDT 75 mW/cm ²	X	X		unclear

* Follow-up study by Szeimies 2010 and Dirschka 2012

PDT with 5-ALA nanoemulsion (BF-200 ALA) vs. placebo

Szeimies et al. evaluated BF-200 ALA-PDT versus vehicle-PDT in a multicenter, randomized, double-blind, placebo-controlled, two-arm study [\[228\]](#). 122 patients (105 men, 17 women) with a mean age of 71 years (age range 57-85 years) with 4-8 mild to moderate lesions were randomized 2:1 to therapy with BF-200 ALA-PDT (81 participants) or vehicle-PDT (41 participants). Three hours after gel application, lesions were irradiated. To represent clinical practice within Europe, two different light sources were used: first, a narrow-spectrum source with an emission spectrum between 590 and 670 nm and a recommended light dose of 37 J/cm², and second, an incoherent broad-spectrum source with emissions between 580 and 1400 nm at a light dose of 170 J/cm². The light sources varied depending on the participating study center and were not randomized. If necessary, a PDT cycle was allowed to be repeated 12 weeks after the first therapy. Already after the first treatment BF-200 ALA-PDT was significantly superior to vehicle PDT (49% vs. 11%). Overall, the complete cure rate after one or two cycles of therapy was 64% vs. 11% on a patient-by-patient basis. The difference was highly statistically significant. Lesion-wise, the proportion of

completely healed AK was 81% in the ALA-PDT group and 22% in the vehicle-PDT group after both cycles of therapy. Interestingly, patient- and lesion-related healing rates were consistently higher for narrow-spectrum source illumination than for broad-spectrum source illumination. In 49% of participants in the intervention group and in 27% of the control group, the overall cosmetic result was rated as very good or good by the investigator. However, it was classified as unsatisfactory in 22% in the control group, compared with only 4% in the ALA-PDT group. In addition, skin quality improved in the BF-200 ALA-PDT group in terms of roughness, dryness, scaling, and hyperpigmentation. No side effects occurred solely as a result of the application of the gel before illumination. Local side effects such as pain, itching or burning during and after illumination were more frequent in patients irradiated with narrow spectrum [228].

Dirschka et al. conducted a multicenter, randomized, placebo-controlled, investigator-blinded phase III study of 570 patients with 4-8 mild-to-moderate AK (Olsen grade I or II) on the face and hairless scalp [230]. 84% of participants were male, and the median age was 71.0 years (range 39-87 years). Participants were randomized in a 3:3:1 ratio to BF-200 ALA-PDT (n=248), MAL-PDT (n=247) and placebo-PDT (n=76) arms. Illumination was provided by several different light sources. A follow-up study summarized the results from two randomized trials with a total of 663 patients (104 women, age range: 39-87 years), one of which included the population originally described by Dirschka et al. [229]. The proportion of patients with completely healed lesions was significantly superior to the vehicle group after three months in the BF-200 ALA-PDT group (78.2% vs. 17.1%; $p < 0.0001$). Treatment of lesions on the face and forehead was more effective than on the hairless scalp. The percentage of completely healed lesions at three months was also higher after treatment with BF-200 ALA-PDT than under vehicle, with a rate of 90.4%, although relatively good results were also observed (37.1%). Similarly, the cosmetic outcome was better after treatment with BF-200 ALA-PDT. In 43.1% of cases, BF-200 ALA-PDT was rated as "very good/good", compared with 36.4% of cases with vehicle-PDT. Side effects occurred more frequently in the BF-200 ALA group (96.4%) than in the placebo group (72.4%) in the study. Redness (78.2%), burning (85.9%), and pain (69.4%) were reported most frequently and were also the most severe. After a follow-up of 12 months, 47% of patients remained with complete healing and no recurrence. However, the cosmetic outcome was rated similarly in both groups at the time points. At 6 months, it was 39.7% ("very good") and 43.1% ("good") for BF-200 ALA-PDT and 34.8% ("very good") and 44.1% ("good") for vehicle, respectively. After 12 months, values of 38.9% ("very good") and 45.0% ("good") were still observed for BF-200 ALA-PDT and for 32.8% ("very good") and 46.9% ("good") for vehicle, respectively.

Reinhold et al. investigated the efficacy, safety as well as the cosmetic outcome of BF-200 ALA-PDT in a multicenter, randomized, double-blind, placebo-controlled phase III study using a red light lamp of a wavelength of 635 nm and a light dose of 37 J/cm² [231]. The photosensitizer was applied field-directed to an area of approximately 20 cm². A total of 94 patients with 4-8 mild to moderate lesions on the face and/or scalp participated. Of these, 87 patients (79 men, 8 women) with a mean age of 71.6 years (standard deviation 6.4 years) were randomized: 55 to the BF-200 ALA-PDT group and 32 to the vehicle-PDT group. If lesions persisted three months after initial therapy, PDT was repeated once. Overall, treatment with ALA-PDT was significantly superior to treatment with vehicle. After two cycles of PDT, the complete response rate was 91% in the active compared to 22% in the control group ($p < 0.0001$). The proportion of patients with at least 75% healed lesions was also significantly higher in

the active group (94% vs. 25%; $p < 0.0001$). In terms of lesions, 94.3% of all treated AK healed completely in the BF-200 ALA-PDT group, but this number was only 32.9% in the control arm ($p < 0.0001$). A higher response of lesions treated with active therapy was also confirmed histopathologically (78% vs. 22%; $p < 0.0001$). Side effects occurred in all patients in the BF-200 ALA-PDT group (100%) and in only 69% in the vehicle-PDT group. The most commonly reported side effects included pain at the application site (96.4% and 50.0%, respectively), skin redness, and itching. Side effects were described as mild to moderate in intensity. On average, pain was reported as significantly more severe in the active than in the vehicle group, during both the first and second treatments (mean BF-200 ALA VAS score: 1st treatment 5.5, 2nd treatment 5.8; vehicle group: 1st treatment 0.9, 2nd treatment 0.3). This difference was not statistically significant. The overall cosmetic result of BF-200 ALA-PDT was rated as "very good" in 59% of cases and "good" in 31%. This was also reflected in the subjective satisfaction of the participants, as 91% in the BF-200 ALA-PDT group were "very satisfied" or "satisfied" (45% for vehicle PDT) [231].

ALA-PDT vs MAL-PDT

Study design and population: Three studies (including one follow-up study) compared the efficacy and safety of 5-ALA-PDT with MAL-PDT. Dirschka et al. conducted a multicenter, randomized, placebo-controlled, investigator-blinded phase 3 study of 570 patients with 4-8 mild-to-moderate AK on the face and hairless scalp. 84% of patients were male, and the median age was 71.0 years (range, 39-87 years). Patients were randomized in a 3:3:1 ratio to BF-200 ALA-PDT (N=248), MAL-PDT (N=247), or vehicle-PDT (N=76) [230]. The follow-up study pooled results from two randomized trials with a total of 663 patients (104 women, age range: 39-87 years), one of which included the population originally described by Dirschka et al. [229]. A randomized, double-blind, intraindividual, monocentric study by Moloney et al. examined 16 men with a mean age of 71 years (age range: 59-87 years). Multiple lesions of all grades including hyperkeratotic AK were included. The two treatment fields per patient were randomized to either MAL-PDT or ALA-PDT therapy [227].

Intervention: In the studies by Dirschka et al., patients were randomized to BF-200 ALA gel (7.8%), MAL cream (160 mg/g), or vehicle gel followed by illumination by various light sources (narrow spectrum around 630 nm with 37 J/cm², broad spectrum between 580-1400 nm with 170 J/cm², spectrum 600-750 nm with 100 J/cm²) [229], [230]. In the study by Moloney et al., randomization was to application of MAL for 3 hours or a 20% ALA cream for 5 hours followed by illumination of a light source with 580-740 nm at a dose of 50 J/cm² [227].

Results and assessment: In Dirschka et al. the percentage of patients with completely healed lesions at 3 months in the BF-200-ALA group was significantly superior to the MAL group (78.2% vs. 64.2%; $p < 0.05$). At 12-month follow-up, this proportion was also higher for BF-200 ALA (BF-200 ALA: 47%, MAL-PDT: 36%). Both treatments were each more effective for lesions on the face and forehead than on the scalp. The percentage of healed lesions at three months was also higher after treatment with BF-200 ALA than with MAL (71%-83.2%), with a rate of 87%-90.4%. In the study by Moloney et al., the percentage of completely healed treatment fields was 40% with ALA-PDT and 46.7% with MAL-PDT. The mean reduction of lesions here was higher in the ALA-PDT group (6.2 ± 1.9 vs. 5.6 ± 3.2 for MAL-PDT). However, the difference was not statistically significant. The overall cosmetic outcome of treatment with MAL-PDT was rated as "very good/good" in 45.2% and with BF-200 ALA-PDT as "very good/good" in 43.1%. After a follow-up of 6 months, it was again rated similarly in

both groups (ALA-PDT: 39.7%-43.1%, MAL-PDT: 42.6%). Side effects occurred more frequently in the MAL-PDT group (98.0%) than in the BF-200 ALA-PDT group (96.4%) in the study by Dirschka et al. Redness, burning, and pain were reported most frequently and were also the most severe. In the study by Moloney et al., only mild redness and erosion occurred in 2 patients. Pain (measured by VAS scale) occurred less frequently in the MAL-PDT group (4.0 ± 3.58) than in the BF-200 ALA-PDT group (4.8 ± 3.61) in the studies by Dirschka et al. This difference was not statistically significant. These results were confirmed in the study by Moloney et al., in which mean VAS score at 12 minutes was 3.9 in the ALA-PDT group and 2.2 in the MAL-PDT group. The difference was statistically significant. Participants felt discomfort for a longer time when treated with ALA-PDT, and two-thirds preferred treatment with MAL-PDT.

PDT with conventional 5-ALA formulation vs. placebo

A 20% ALA formulation is not approved in Germany, unlike in the USA (Levulan Kerastick®). Illumination with blue light is also not recommended. Nevertheless, the following studies are discussed for the sake of completeness.

Jeffes et al. conducted a multicenter, randomized, single-blinded (investigator-blinded) vehicle-controlled, intraindividual study of 36 patients (30 men, 6 women; mean age 68.8 years, range 38-100 years) to evaluate the safety and efficacy of 20% ALA PDT at various doses of blue light (2, 5, and 10 J/cm²) in the treatment of single or multiple AK on the face and scalp (minimum 4) [222]. In each patient, two lesions were treated with vehicle and two other lesions were treated with 20% ALA. The incubation period was 14 to 18 hours. Subsequently, all lesions in a patient were irradiated with the same dose randomized per patient. After 8 weeks, the rate of completely healed lesions was significantly higher for ALA-PDT than for vehicle-PDT (66% vs. 17%; $p < 0.001$). It continued to increase significantly to 85% for active therapy at 16 weeks, whereas it dropped to 6% for vehicle. However, there was no difference in the rate of at least 50% healed lesions (17% for both treatments at 8 weeks). After 16 weeks, it was only 6% for ALA-PDT-treated lesions. In 46% of the study population, both ALA-PDT-treated lesions were completely healed after 8 weeks (vehicle-PDT 6%). Regarding randomized light doses, treatment with the highest dose of 10 J/cm² was found to be most effective. Under this, 88% of all treated lesions showed a complete response after 8 weeks. The dose of 5 J/cm² performed second best, with a complete response rate of 62%. In general, thin (grade I) lesions responded better to therapy than thicker (grade II) lesions. Burning and stinging during PDT were significantly more common for 20% ALA than for vehicle (89% vs 3%), with burning reported as severe in 18% of treated patients. Furthermore, pain (43%) and itching (39%) were more common in active therapy [222].

The randomized, vehicle-controlled, investigator-blinded, multicenter study by Pariser et al. compared the effect of a short incubation period of ALA-PDT with vehicle in the treatment of AK on the face and scalp [223]. For this, a total of 236 participants (211 men, 23 women; mean age: 68 years, range 40-88 years) with 6-20 Olsen grade 1-2 lesions on the face or scalp were randomized interindividually to 5 different treatment arms: large area application of 20% ALA for 1, 2 or 3 hours followed by illumination with blue light ($n=47$, $n=48$, $n=47$), spot application of 20% ALA for 2 hours followed by illumination with blue light ($n=46$) or application of vehicle followed by illumination with blue light ($n=46$). The majority of patients had Fitzpatrick skin type II or III (44% and 43%, respectively), with 6% each having skin type I. Overall, the ALA-PDT groups performed significantly better in healing AK

compared with the vehicle group. The median rate of completely healed lesions in the active treatment arms (large-area application and 1, 2, or 3 hours of incubation, and spot application and 2 hours of incubation) was significantly superior to the vehicle-PDT group at 12 weeks (ALA-PDT: 68-79%, vehicle-PDT: 7%). In each case, the highest median rate of completely healed lesions was achieved by the ALA-PDT group with 3 hours of incubation and the group with 2 hours of incubation and spot application, respectively (57.1%±37.0 and 57.1%±43.8). The 2-hour incubation group showed a median reduction of 52.5%±37.2, with 1-hour incubation 35.7%±42.0, and the vehicle group 5.7%±33.5. Likewise, rates of patients with completely healed lesions at 12 weeks were significantly higher in the intervention groups than in the vehicle PDT group (ALA PDT group: 17%-30%, vehicle PDT group: 2%; p=0.0041). Here, the longest incubation time of 3 hours achieved the highest complete response rate of 17%, the group with an incubation time of 2 hours had a rate of 14.6%, with one-hour incubation time only 6.4% remained, and the group with punctual application and 2 hours incubation time 8.7% compared to 0% with vehicle. Regarding the rate of patients with at least 75% of lesions completely healed, a similar trend of increasing efficacy with longer incubation time could be observed in each cohort: 31.9% (3 hours), 27.1% (2 hours), 21.3% (1 hour), 28.3% (spot and 2 hours) and 2.2% (vehicle). The differences were significant in each case to the vehicle group. 79% of all patients in the ALA-PDT groups rated the treatment outcome as satisfactory, whereas only 35% in the vehicle group. Regarding tolerability, 63.8% of patients with 1-hour incubation, 79.2% with 2-hour incubation, 78.7% with 3-hour incubation, and 58.2% with 2-hour incubation and spot application rated stinging and burning during treatment as moderate or severe. The incidence of skin redness increased in all treatment groups shortly after illumination compared with baseline measurements but was more severe in the ALA groups than in the vehicle group. The increase was highest in the 3-hour incubation group (61.7%), followed by the 2-hour incubation group (58.3%). In the 1-hour incubation group, 38.3% of patients had skin redness, compared with 41.3% in the 2-hour incubation and spot application group and 6.5% in the vehicle group. The incidence of edema was highest in patients with the longer incubation times. All participants in the intervention groups showed an increase in skin scaling and skin dryness at a visit between 24 and 48 hours after initial treatment compared with baseline. The evidence level of the study was downgraded to 3 because of ambiguities in randomization.

Piacquadio et al. reported the results of two identical phase III studies within one publication [224]. These were two multicenter, randomized, placebo-controlled, investigator-blinded trials in a parallel-group design with 243 patients (203 men and 40 women aged 34-89 years). Inclusion criteria were 4-15 discrete AK on the face or hairless scalp. Overall, participants were randomized to lesion-directed application of 20% ALA (n=181) or vehicle (n=62). This was followed by illumination with blue light within 14 to 18 hours. Treatment with ALA-PDT was significantly more effective and superior to the vehicle group in terms of efficacy. 66% of participants in the ALA-PDT group had completely healed lesions after 8 weeks (complete response). In the vehicle group, only 11% had completely healed AK. After another month, the rate of patients with completely healed lesions still increased to 89% in the intervention group and decreased to 13% in the vehicle group. Also, at 8 weeks, 77% of patients in the intervention group and 18% in the vehicle group had at least 75% healed lesions; at 12 weeks, the rate increased to 89% in the ALA-PDT group and decreased to 13% in the vehicle group. Lesion-wise, 83% of AK were completely healed at 8 weeks in the active group, and as many as 91% at 12 weeks. In the vehicle group, however, only 31% of lesions had healed after 8 weeks and 25% after 12 weeks. A total of 113

adverse events were observed, of which 92% were classified as mild or moderate. The most common side effects included skin redness and edema at the treated sites and stinging and burning during illumination. In addition, crusting (49%), itching (30%), and scaling (31%) were reported. 6.6% of patients in the intervention group and 3.2% in the vehicle group reported headache, 5.0% and 1.6%, respectively, reported injury in the treatment area, and 1.7% in the ALA-PDT group reported hypertension and hypertension. The evidence level of the study was downgraded to 3 because of ambiguities in blinding.

Schmieder et al. compared 20% ALA-PDT with vehicle-PDT with blue light illumination in a multicenter, randomized, investigator-blinded, vehicle-controlled phase II trial [225]. As a special feature, they investigated whether occlusion improved treatment efficacy. Seventy patients with at least 4 AK on the upper extremities (hands, arms), including 45 men and 25 women with a mean age of 64 years (range 44-83 years), participated in the study. Each patient was randomized to treatment with either ALA or vehicle (interindividual). Then, the left and right arms were each randomized to occlusive or non-occlusive application of the assigned substances (intraindividual). The intervention consisted of application of 20% ALA hydrochloride or vehicle to the dorsum of the hand or dorsal forearms, respectively, for 3 hours, followed by illumination with blue light. If lesions persisted after 8 weeks, treatment was repeated. Treatment with ALA-PDT generally achieved significantly better results with respect to all end points compared with vehicle-PDT. In the additional comparison of occlusive vs. non-occlusive treatment, the former was again significantly more effective. The proportion of patients with completely healed lesions at 12 weeks was 34.3% for ALA-PDT with occlusion and only 20.0% without occlusion compared with 0% and 2.9%, respectively, for vehicle. The proportion of participants with at least 75% of lesions healed also showed a very similar trend (ALA-PDT with occlusion 60% and without occlusion 42.9%; vehicle-PDT with occlusion 8.6% and without occlusion 5.7%). The median lesion reduction rate was consistently higher in patients treated with ALA-PDT than with vehicle-PDT. Again, there were slight benefits after occlusion of ALA (88.7% vs. 70% without occlusion). Subjectively, participants were also satisfied with ALA-PDT in occlusion; 83% here rated the improvement in treated AK as moderate or excellent. Side effects occurred in all treatment arms. Skin redness increased in both groups after blue light treatment, but more markedly in patients treated with ALA-PDT (100% vs. 88.6%). Scaling and dry skin were also observed significantly more frequently under ALA-PDT (91.4% with vs. 85.7% without occlusion) than under vehicle-PDT (71.4% with vs. 68.6% with occlusion). Additional erysipelas and muscle pain occurred in 3% of participants treated with ALA-PDT. The study was downgraded to an evidence level of 3 because of ambiguities in treatment assignment and randomization.

Taub et al. compared 20% 5-ALA with vehicle in a randomized, blinded, intra-individual, vehicle-controlled trial [226]. The mean age of the 15 patients (11 women, 4 men) was 55.8 years with a standard deviation of 9.4 years. Participants had at least 4 lesions each on the dorsum of the hand or the dorsal aspect of the forearm of both sides. Treatment was given twice at eight-week intervals and consisted of therapy with 20%-ALA hydrochloride or vehicle on one side at a time (randomized) followed by illumination with blue light. Treatment with 20% 5-ALA was superior in this study. The percent mean reduction of lesions here was 58.4% (± 22.2), statistically significantly higher than in vehicle-treated lesions ($24.8 \pm 20.6\%$; $p=0.0004$). In 73% of extremities treated with ALA-PDT, the number of lesions decreased by half, but this number was only 13% with vehicle. This difference was also highly statistically significant. Side

effects 48 hours after illumination such as skin redness, edema, stinging and burning were more frequent and severe in the active group. Overall, 86.7% of all participants were satisfied with the treatment. The level of evidence was downgraded to an evidence level of 3 because of ambiguities in randomization and a small number of cases.

Brian-Jiang et al. conducted a randomized trial of 20% ALA formulation versus placebo on the arms and dorsum of the hands, respectively. A total of 269 patients with 4-15 lesions (grade I-II according to Olsen) were randomized 1:1 to ALA-PDT or placebo (188 men, mean age 68 years) [252]. The patient-related complete healing rate at 12 weeks was 31% versus 13% with placebo ($p < 0.0001$). In percentage terms, the mean healing rate was 69.1+37.4% for ALA-PDT and 29.9%+51.5% for placebo. Side effects were significantly more common with ALA-PDT, with burning (93% vs. 17%), erythema (91% vs. 58%), edema (30-40% with ALA-PDT), and scaling (76% with ALA-PDT) recorded most frequently.

PDT with conventional 5-ALA formulation vs. trichloroacetic acid

For a comparison of these interventions, see [Chapter 5.5.3](#).

PDT with conventional 5-ALA formulation vs. 5-fluorouracil 5% cream

Study design and population: Smith et al. compared the efficacy and tolerability of ALA-PDT with blue light or laser illumination versus 5-FU in a study population of 36 patients (29 men, 7 women) with a mean age of 61 years. Treatments were field-directed. The face or hairless scalp was treated either with ALA topically for 1 hour followed by blue light or laser light, or with 0.5% 5-FU. The number of lesions per patient and the degree of AK included were not reported in detail [182].

Intervention: Group 1: application of 20% ALA for 1 hour followed by blue light illumination; group 2: application of 20% ALA for 1 hour followed by pulsed dye laser at 595 nm; group 3: application of 0.5% 5-FU cream once or twice daily for a total of 4 weeks.

Results: The percentage of patients with completely healed lesions was highest under 5-FU and ALA with blue light, 50% each. Only 8% of patients in the ALA with laser illumination group showed a complete response. Regarding the proportion of patients with at least 75% completely healed lesions, treatments with 5-FU and ALA with blue light also achieved similar and at the same time the most effective results (75% each); in the treatment with ALA plus dye laser (group 2), only 8% of patients had at least 75% healed lesions. Global response was classified as "complete/almost complete" in 8% with 5-FU, 17% with ALA plus blue light, and 8% with ALA plus dye laser. Global response was classified as moderate in 58% (5-FU), 33% (ALA plus blue light), and 42% (ALA plus dye laser). Skin redness was most common. Patients in the 5-FU group had the highest incidence of skin redness on average. Local skin reactions such as crusts and erosions were likewise most frequently observed in the 5-FU group and were less pronounced in the other two treatment arms. Overall, ALA plus blue light or plus dye laser illumination was better tolerated than treatment with 5-FU. The level of evidence was downgraded to an evidence level of 3 because of ambiguities in randomization and a small number of cases.

5.7.3 Photodynamic therapy with daylight

A new approach and approved therapy since 2015 is daylight PDT, in which, for the same indication, ALA or MAL is applied thinly to large areas of the face and capillitium after prior application of a chemical photoprotective filter and roughening of keratotic areas, and the patient is exposed to daylight for 2 hours under suitable weather conditions (March-October, outside temperature >10°C, cloudless to overcast sky, no rain) [247], [256], [246], [244], [243], [242].

Two pivotal phase III trials in Australia and Europe compared daylight and conventional PDT with MAL cream in a multicenter, investigator-blinded, controlled, intraindividual trial approach in terms of noninferiority analysis [247], [246]. The main target criteria were complete lesion-level response (mild- and moderate-type AK in the facial and scalp areas) and painfulness of the treatments. The intraindividual approach could be achieved by applying a chemical photoprotective filter to the side exposed to daylight PDT, subsequent lesion treatment, and application of MAL cream followed by light exposure for 2 hours. The contralateral side in each case received MAL cream application for 3 hours under occlusion in parallel, so that immediately after termination of daylight exposure the other side could be illuminated conventionally with red light (LEDs). At 12 weeks after a single session, the complete healing rate at the lesion level was not inferior to classical MAL-PDT performed conventionally (89% vs. 93% in Australia, 70% vs. 74% in Europe). The poorer healing rates in Europe were based on the higher proportion of moderate AK and the inclusion of a higher percentage of AK on the scalp than on the face. The VAS pain score was significantly different (0.8 vs. 5.7 in Australia, 0.7 vs. 4.4 in Europe) [247], [246].

Furthermore, a total of three studies have been published by the same research group on MAL-PDT with daylight [244], [243], [242]. The multicenter randomized, investigator-blinded, parallel-group study of 120 patients with daylight MAL-PDT published in 2011 compared different incubation periods of MAL [244]. There was a 1:1 randomization to daylight MAL-PDT with 1.5 or 2.5 hours of exposure time. The mean clinically demonstrated lesion-based reduction rate at the end of the study (after 3 months) was 77.2% (1.5 h) vs. 74.6% (2.5 h), and the mean reduction in the number of lesions did not differ (9.8 vs. 9.7). The mean pain score (VAS score) during daylight PDT was 1.3 and did not differ between groups [244]. In the 2008 monocentric comparative study with intraindividual design, daylight MAL-PDT was compared with MAL-PDT performed conventionally with red LED light [242]. There was a statistically nonsignificant difference in mean reduction of AK 3 months after intervention (79.0% vs. 71.1%), but painfulness of treatment was significantly lower with daylight MAL-PDT (3.74 vs. 5.46) [242]. In another similarly designed study, the authors also demonstrated that the response of daylight MAL-PDT was dependent on the severity of the lesions treated. Thus, mild AK lesions (Olsen grade I) healed completely in 80.2% of cases, moderate lesions in 63.8% (Olsen II), and severe lesion grades (Olsen III) in only 39.3% [243].

In another study of 70 patients with at least 3 AK on the face or hairless scalp, daylight MAL-PDT was shown to be slightly inferior to conventional in terms of effectiveness but significantly less expensive [245]. Furthermore, one paper was identified that compared daylight MAL-PDT with IMB.

Assikar et al. demonstrated the non-inferiority of daylight MAL-PDT compared to MAL-PDT performed conventionally with blue light in an intraindividual study of 26

patients with AK on the face and capillitium. The lesion-related healing rate was 90.5% for dIPDT and 94.2% for cPDT. Likewise, the mean lesion reduction was almost the same for both arms (dIPDT: 19.6+/-6; cPDT: 20.0+/-6.9). However, the dIPDT was found to be significantly and substantially less painful [239]. However, this study was downgraded to an evidence level of 3 because of a small case number and other methodological flaws.

Dirschka et al. compared BF-200 ALA versus MAL in dIPDT in a large-scale, multicenter noninferiority study in a half-side comparison (split-face). 52 patients were intraindividually randomized one face/scalp side to one of the two photosensitizers. 96.2% were male, the mean number of lesions per patient was 6.4+/-2.2, a total of 316 lesions were treated. The patient-specific complete cure rate was 42.9% for ALA-dIPDT versus 38.8% for MAL-dIPDT. The endpoint of lesion-related healing rate was also similar for both photosensitizers (79.8% for ALA-dIPDT vs. 76.5% for MAL-dIPDT). The study reported a significantly higher recurrence rate for MAL-dIPDT (31.6%) compared with ALA-dIPDT (19.9%) after 12 months of follow-up. The usual PDT-mediated adverse events occurred with similar frequency in both treatment arms. Painfulness during illumination was also estimated to be low for both arms. This study demonstrates that both MAL and ALA can be used reliably and safely for dIPDT. Patient-related and lesion-related healing rates were similar for both photosensitizers. The recurrence rate for MAL-dIPDT was significantly higher. However, with the relatively small number of cases, the clinical relevance of this difference remains unclear [240].

A similar comparison of ALA-dIPDT and MAL-dIPDT was provided by Räsänen et al. 2019 in a multicenter double-blind study of 69 patients. Both photosensitizers were applied to one side of the face each in an intraindividual comparison. In total, 767 individual lesions were treated (n=375 with BF-200 ALA and n=392 with MAL). The lesion-specific healing rate was 79.7% for ALA-dIPDT (299/375 lesions) versus 73.5% for MAL-cPDT (288/392 lesions). The patient-related complete healing rate was 27.5% for both interventions. Painfulness during treatment would be equally low for both arms (1.51 for ALA-dIPDT vs. 1.35 for MAL-dIPDT). Interestingly, local skin reactions were slightly more severe with ALA than with MAL (26 vs. 7 reactions) [241].

Table 27: Overview of included individual studies on daylight PDT

Study	Interventions	Single AK	Multiple AK	Field cancerization	Immunosuppression
Moggio 2016 [200]	MAL-dIPDT vs. IMB 0.015% gel 3 days	X	X		
Neittaanmaki-Perttu 2016 [245]	MAL-dIPDT vs. MAL-PDT	X	X	X	
Wiegell 2011 [244]	MAL-dIPDT 1.5 h incubation vs. MAL-dIPDT 2.5 h incubation	X	X		
Wiegell 2009 [243]	MAL-dIPDT 8% vs. MAL-dIPDT 16%	unclear	X	X	
Wiegell 2008 [242]	MAL-dIPDT vs. MAL-PDT	unclear	X	X	
Dirschka 2019 [240]	ALA-dIPDT vs. MAL-dIPDT	X	X		
Assikar 2020 [239]	MAL-dIPDT vs. MAL-PDT (blue light)	X	X		
Räsänen 2019 [241]	ALA-dIPDT vs. MAL-dIPDT	X	X		

Abbreviations: LED=light-emitting diode

5.8 Therapy in immunosuppression and organ transplantation

Chronic immunosuppressed patients show significantly increased morbidity and also mortality due to the development of cutaneous SCC compared to immunocompetent comparison groups [257]. In addition to an early modification of immunosuppressive therapy protocols by eliminating azathioprine and switching to mTOR inhibitor-containing immunosuppression, exploiting the preventive effect of photoprotection as well as vitamin B6 on the progression of AK also in immunosuppressed patients, the early therapy of AK in terms of secondary prevention is of increased importance. There were 4 RCTs identified that investigated area therapy of AK in immunosuppressed organ transplant recipients [248], [213], [172], [258]. Another study investigated in a subgroup analysis the use of a topical lotion with DNA repair enzymes compared to sunscreen filters in OTR [259]. Here, in addition to the therapy efficiency, a possible interaction of the applied topical therapy in terms of immunosuppression and graft safety in terms of visible rejection reactions must be considered.

Table 28: Overview of the included individual studies for the immunosuppressed subgroup

Study	Interventions	Single AK	Multiple AK	Field cancerization	Immuno-suppression
Dragieva 2004 [248]	MAL red light PDT vs. vehicle PDT		X	unclear	X
Togsverd-Bo 2018 [258]	Imiquimod 5% cream vs. MAL red light PDT	X	X	unclear	X
Ulrich 2007 [213]	Imiquimod 5% cream 3x/week vs. placebo	X	X	X	X
Ulrich 2010 [172]	Diclofenac sodium 3% gel vs. vehicle	X	X	unclear	X
Veronese 2019 [259]	Topical lotion with DNA repair enzymes (2/day) vs. Sunscreen filters (UV-B, UV-A) for 6 months.	X	X	Unclear	X

5.8.1 Photodynamic therapy

5.22	Evidence-based recommendation	modified 2022
GoR B	Photodynamic therapy with red light illumination using 5-aminolevulinic acid (ALA) or its methyl ester (MAL) should be offered for single or multiple actinic keratoses and for field cancerization in immunosuppressed patients.	
LoE 2	[258], [260], [248] 2: De novo research	
	Strong consensus	

Dragieva et al. studied 14 kidney and 3 heart transplanted patients with two lesional skin areas each in a monocentric, prospective, double-blind, placebo-controlled, intra-individual study. Patients received two treatment sessions one week apart with topical MAL or placebo cream followed by illumination with 75 J/cm² visible light (600-730 nm). With a total of 129 mild-to-moderate AK at baseline, the lesion-related complete response rate assessed 16 weeks after the second cycle of therapy was 90.3% (56/62 AK lesions) in the MAL-treated group vs. 0% (0/67) in the placebo group (p=0.0003). Complete response of the entire treatment field was achieved in 75.4% (13/17; 95% CI: 9-16), partial response (>75% of all lesions per field healed) in 94.1% (CI not stated). None of the areas treated with placebo showed a response. Described local side effects in the MAL-PDT group were erythema, edema and crusts, but their frequencies were not reported. Premedication with acetaminophen (1 g) applied orally one hour before treatment and the use of cooling ventilation resulted in MAL-PDT-associated treatment pain in the study being reported in the lower and middle VAS range. Due to the selective lack of confidence intervals and p-values, selective reporting of results cannot be excluded. In addition, there are uncertainties regarding randomization and blinding, which is why the study was downgraded to evidence level 3. Strikingly, there was a very large effect size of MAL-PDT compared to placebo in all investigated efficacy endpoints. However, treatment-mediated adverse effects were not consistently and quantitatively reported, so that an assessment of the benefit-harm ratio is possible only to a limited extent.

Another European, open-label, multicenter, intraindividual study of 81 organ transplant recipients compared treatment of AK by MAL-PDT versus lesion-adapted cryosurgery. This study was excluded because of its primarily preventive approach and was not considered significantly in the recommendation, but the results will nevertheless be briefly outlined [261]. For the study, one skin area with a total of 476 lesions in each patient was initially treated twice at weekly intervals and then optionally at months 3, 9 and 15 with a classic red light MAL-PDT. The control areas with a total of 413 lesions were initially treated once and then consecutively at months 3, 9 and 15 with cryosurgery. While there were significantly fewer AK in the areas treated with MAL-PDT than in those treated with cryosurgery at the 3-month evaluation (p=0.006), the treatment effect was no longer significantly different after 27 months (253 vs. 312 lesions; p=0.06). This work implies that MAL-PDT was superior to cryosurgery at least in short-term lesion reduction [261].

In addition, a systematic review synthesized the current evidence on the effectiveness and safety of various interventions for the treatment of AK in organ transplant patients [260]. A literature search of mainstream medical databases and gray literature was conducted through August 22, 2018. Of 663 publications initially identified, eight RCTs involving 242 organ transplant patients were included in a qualitative synthesis. Most studies investigated PDT with methylaminolevulinate (MAL-PDT), followed by ablative fractional laser (AFXL) and diclofenac sodium 3% in hyaluronic acid, imiquimod 5% cream and 5-fluorouracil 5% cream (5-FU). MAL-PDT had the highest rates of complete patient-related healing (40-76.4%), followed by imiquimod (27.5-62.1%), diclofenac (41%) and 5-FU (11%). Similar results were reported for lesion-specific healing rates. Treatment with AFXL alone resulted in low lesion clearance (5-31%). Local skin reactions were most severe in participants treated with a combination of AFXL and MAL-PDT in daylight. No treatment-related graft rejections or worsening of graft function occurred in any of the studies. The overall risk for bias was considered high. Limited evidence is available for the treatment of AKs in organ transplant recipients. MAL-PDT is currently the best studied intervention. Lesion-specific therapies may not be sufficient to control the disease. Field-specific therapies are preferable in this high-risk group.

Togsverd-Bo et al. examined the efficacy and safety of field-directed MAL-PDT and imiquimod for AK in OTRs compared in an intraindividual study [258]. A total of 35 organ transplant patients with 572 AKs (grades I-III) in two similar areas on the face, scalp, dorsum of the hands or forearms were included. All patients received MAL-PDT and imiquimod treatment (three applications per week for a period of 4 weeks) in each study area according to randomization. Treatments were repeated after 2 months (imiquimod) or 3 months (PDT) in the absence of response. The majority of randomized areas received two treatment sessions (PDT n=25 patients; IMIQ n=29 patients). Compared with imiquimod, PDT treatment resulted in a higher lesion-related healing rate at 3-month follow-up and shorter-lasting but more intense skin responses. The median patient-related healing rate was 78% in areas treated with PDT and 61% in areas treated with imiquimod. Depending on the grade of AK, PDT was more effective than imiquimod in grade I thin AKs (median CR 82% vs. 66%) and grade II and III keratotic AKs (median complete response 33% vs. 25%). Fewer new-onset AKs were observed in PDT-treated areas than with imiquimod (0.7 vs. 1.5 AK). Patients developed more intense inflammatory skin reactions after PDT, which resolved more rapidly compared with imiquimod (median 10 days vs. 18 days, $p < 0.01$). Patient preference and cosmetic outcome were similarly rated by patients. Limitations of this study include that patients were not blinded due to the study design, which limits interpretation of patient-reported outcomes.

5.8.2 Imiquimod

5.23	Evidence-based recommendation	modified 2022
GoR 0	Imiquimod 5% cream may be offered for single or multiple actinic keratoses and for field cancerization in immunosuppressed patients. For the latter, the lack of regulatory approval should be noted.	
LoE 2	[258], [260], [213] 2: De novo research	
	Strong consensus	

A European, multicenter, double-blind, interindividual randomized (2:1) study evaluated imiquimod 5% cream versus placebo in 30 kidney, 4 liver and 9 heart transplant patients [213]. They were treated with 3 weekly applications of 500 mg imiquimod 5% for 16 weeks. Complete healing of AK in the treatment area (complete response) was 62.1% in the imiquimod group (100% in the liver transplant group, 65% in the kidney transplant group, and 42.9% in the heart transplant group) vs. 0% on placebo. Rejection-specific and graft-specific laboratory values examined by a blinded group of experienced transplant physicians during the study period showed no relevant abnormalities in either the placebo or imiquimod treatment arms. Side effects of imiquimod were local nonspecific reactions at the site of application (1/29), fatigue (8/29), headache (1/29), diarrhea (1/29), nausea (1/29), rash (1/29), unspecified skin reactions (1/29) and leukopenia (1/29). An important finding of this work was that imiquimod as an immunostimulant did not result in rejection reactions. Furthermore, the effect of treatment with imiquimod versus placebo was strikingly high, as a complete response of 62.1% vs. 0% was achieved with placebo. These data suggest a good benefit-harm ratio in the organ transplant subgroup. However, the approval for topical imiquimod for immunosuppressed patients is limited in routine use. In addition, severe adverse events have sometimes been observed after topical application of imiquimod, such as a case report of acute renal tubular necrosis published in 2011. However, since the patient in this published report had already undergone triple pre-transplantation, from today's perspective this reaction can be attributed only to a limited extent as an immunological interaction of imiquimod therapy [262].

Furthermore, a systematic review identified patient-specific healing rates ranging from 27.5 to 62.1% for imiquimod 5% cream [260]. In an intra-individual comparative study of imiquimod 5% cream with MAL-PDT in 35 OTR, treatment with imiquimod 5% was inferior to MAL-PDT [258].

5.8.3 Diclofenac

5.24	Evidence-based recommendation	modified 2022
GoR B	Diclofenac sodium 3% gel should be offered for single or multiple actinic keratoses and for field cancerization in immunocompromised patients.	
LoE 3	[260], [172] 3: De novo research	
	Strong consensus	

In a double-blind, placebo-controlled, randomized study published in 2010, 32 organ transplant patients (18 renal, 8 heart and 6 liver transplant patients) were treated with either diclofenac sodium 3% in hyaluronic acid 2.5% gel or vehicle gel only [172]. The application of the study substances was twice daily for a total of 16 weeks. The complete healing of all lesions in the treatment area was evaluated 4 weeks after the end of therapy and again after 24 months in the follow-up phase. In the first evaluation, the total healing rate in the verum group was 41% (kidney 30.7%, liver 40%, heart 75%) vs. 0% in the vehicle group. Partial healing of at least 75% was seen in 59% in the active group vs. 16.7% in the control group. Differences according to the organ originally transplanted were present, but the number of cases appears too small for these differences to be meaningful enough and could not have been caused by other, intraindividual factors. However, one exception is the 18 heart transplanted patients, 100% of whom showed partial improvement with verum and 0% with placebo. The mean reduction in the number of lesions was 53% vs. 17% (verum vs. placebo). The recurrence rate was 55% after a mean of 9.3 months, and side effects reported were mild to moderate erythema, scaling, pruritus and skin irritation and edema. There was no development of SCC in the treatment areas. Unequal loss of patients in the groups and ambiguities in randomization result in a risk for bias, which is why the level of evidence was downgraded to 3.

However, the reported effectiveness end points indicate a large effect size of the intervention compared with placebo, which justifies the strong recommendation level.

5.9 Other interventions

The literature search revealed a number of other substances that have been investigated in topical or systemic application for efficacy and tolerance in AK. These individual substances are currently neither approved in Germany nor are there reliable RCTs on these interventions.

Table 29: Overview of individual studies on other topicals

Study	Interventions	Single AK	Multiple AK	Field cancerization	Immunosuppression
Akar 2001 [263]	Colchicine 0.5% cream vs. colchicine 1% cream	X	X		
Alberts 2000 [264]	Difluoromethyl ornithine 10% in ointment base vs. placebo	X	X		
Evans 2014 [265]	Canola phenolic acid 7.8% cream vs. placebo	X	X		
Moloney 2010 [266]	Nicotinamide 1% in hydrophilic base vs. placebo	X	X		
Plugfelder 2015 [267]	Oleogel-S10 once daily vs. oleogel-S10 twice daily vs. placebo once daily vs. placebo twicedaily	X	X		
Tong 1996 [268]	Glucan-containing gel (β -1,3-D-glucan) vs. placebo	X	X		
Thompson 1993 [269]	Sunscreen filters (UV-B, UV-A) over 7 months vs. placebo	X	X	unclear	

Study	Interventions	Single AK	Multiple AK	Field cancerization	Immunosuppression
Stoddard 2017 [270]	Lotion with DNA repair enzymes (2/week) vs. placebo	X	X	X	
Veronese 2019 [259]	Lotion with DNA.repair enzymes (2/day) vs. sunscreen filters (UV-B, UV-A) over 6 months.	X	X	unclear	X
Yang 2018 [271]	SR-T100 gel under occlusion for 8 h vs. placebo		X	X	
White 2017 [272]	Ingenol disoxate 0.037% gel 2 days vs. ingenol disoxate 0.05% gel 2 days vs. placebo	X	X	unclear	
Bourcier 2016 [273]	Ingenol disoxate 0.006% gel 2 days vs. ingenol disoxate 0.012% gel 2 days vs. ingenol disoxate 0.018% gel 2 days vs. placebo	X	X		
Sinnya 2016 [201]	Ingenol disoxate 0.025% gel 2 days vs. ingenol disoxate 0.05% gel 2 days vs.		X		

Study	Interventions	Single AK	Multiple AK	Field cancerization	Immunosuppression
	ingenol disoxate 0.075% gel 2 days vs. IMB 0.05% gel 2days				
Szeimies 2008 [274]	Resiquimod 0.01% gel vs. resiquimod 0.03%gel vs. resiquimod 0.06% gel vs. resiquimod 0.1% gel	X	X		

5.9.1 Birch cork

Population and study design: Birch cork is rich in triterpenes such as betulin or betulinic acid, which are believed to have anti-inflammatory and anti-proliferative properties. The birch cork extract oleogel-S10 was studied as an active ingredient in a multicenter randomized trial in 165 patients with at least 2 mild to moderate AK on the face or head [267]. Histological confirmation was required for study inclusion. The study was double-blinded.

Intervention: Randomization was 2:2:1:1 interindividually into 4 different treatment arms (A-D). Interventions consisted of oleogel-S10 once daily (arm A), oleogel-S10 twice daily (arm B), vehicle once daily (arm C), or vehicle twice daily (arm D) for 3 months.

Results: Treatment success was evaluated clinically and histopathologically after 18 weeks. Overall, 43.9% showed histological "downgrading" according to Cockerell classification, with no significant difference between the active and placebo-controlled arms. A reduction of more than 75% of all lesions was observed in 15% (A), 18% (B), and 13% (C+D). Complete healing of all lesions was achieved by 2% in arm A and 5% in arm B compared with 0% in the placebo arms. However, these differences were not significant. Twenty-nine adverse events were recorded, including 5 serious events that were not therapy-associated. Tolerability of active therapy was reported as "very good" by 56.4% of patients and "good" by 18.2%. Itching was most frequently reported.

Assessment: Therapy with oleogel-S10 appeared well tolerated overall, but not superior to placebo in all efficacy endpoints studied. Betulin-based oleogel was investigated by Huyke et al. in two other studies, but these were not included due to

lack of randomization and combination with cryosurgery [275], [276]. Overall, therefore, there is a lack of evidence of benefit for this substance in the treatment of AK.

5.9.2 Colchicine

Population and study design: One study evaluated the alkaloid colchicine in 16 patients with single or multiple AK on the face, hands, hairless scalp, and arms or hands (Akar 2001). All study patients were Caucasians.

Intervention: Colchicine was applied as a 0.5% or 1% cream twice daily for 10 days. These two arms were compared without an additional placebo arm.

Results: The rate of patients with complete healing of all lesions was 6/7 (1%) and 6/8 (0.5%). The rate of reduction of individual lesions was 73.9% (1%) versus 77.7% (0.5%), and the mean reduction of lesions per patient was 0.7 ± 1.3 (1%) and 0.6 ± 1.7 (0.5%). AK on the face appeared to perform better than at other sites in this study (Akar 2001).

Assessment: Although no major methodological flaws were identified, the lack of a placebo arm severely limits the study's power in terms of efficacy and safety. No other studies (RCT) of this intervention were identified, so no evidence-based recommendations can be made at this time.

5.9.3 Canola phenolic acid

Population and study design: Canola phenolic acid is a chemical compound rich in sinapic acid. It is believed to have antiproliferative and cytotoxic effects. One study evaluated canola phenolic acid in 45 patients with 3-10 AK within a treatment field of 20 cm² [265]. This double-blind, placebo-controlled study was conducted in the Dominican Republic.

Intervention: Canola phenolic acid was applied as a 7.8% preparation in a hydrophilic cream twice daily after showering for 12 weeks.

Results: The primary endpoints of the study were complete or partial healing of lesions in the treated area. No patient showed complete healing of all AK. After 3, 6, and 12 weeks of treatment, there was a significant reduction in lesions compared with placebo. A total of 56 adverse events occurred, 45 in the treatment arm and 11 in the placebo arm.

Assessment: Canola-phenolic acid showed superiority to placebo in terms of lesion reduction but not in terms of patient-related response. Therefore, the magnitude of the effect remains difficult to interpret. No other studies (RCTs) of canola phenolic acid were identified. Because the work was conducted in the Dominican Republic, transferability to a Caucasian population is questionable.

5.9.4 Difluoromethyl ornithine

Population and study design: Difluoromethyl ornithine is an irreversible inhibitor of ornithine decarboxylase. It was tested in a study in 48 patients with moderate to severe AK on the forearms; study patients had at least 10 lesions [264].

Intervention: Difluoromethyl ornithine was applied in a 10% hydrophilic ointment base twice daily and compared against vehicle intraindividually on the opposite side. The duration of therapy was 6 months.

Results: After this time point, the number of lesions significantly decreased by 23.5% on the difluoromethyl ornithine-treated arm, whereas no improvement was seen on the vehicle-only arm. Five patients (10.4%) showed moderate local side effects such as erythema.

Assessment: No other RCTs on difluoromethyl ornithine were identified. Although no major methodological flaws of the study were identified, further studies need to investigate the place of difluoromethyl-ornithine in the therapy of AK. In particular, accurate data on side effects and tolerability, which are necessary to evaluate the harm-benefit ratio, are lacking.

5.9.5 Glucans

Population and study design: Glucans are polysaccharides linked by glycosidic bonds. They are found in cell walls of bacteria and fungi, among others, and have immunomodulatory effects. Tong et al. studied a glucan-containing gel (β -1,3-D-glucan) in 20 patients with 10-50 AK on their arms. All participants were Caucasian and had fair skin type (I according to Fitzpatrick) [268].

Intervention: treatment was intraindividually randomized as a half-side trial of both arms, with glucan gel or placebo twice daily for 7 days.

Results: After 8 weeks, a mean lesion reduction from 22.5 to 16.8 was measured in the active therapy and from 23.9 to 15.6 in the placebo arm. The difference between the two arms was not significant at any observation time point (week 1, week 4, week 8). The side effects erythema and burning sensation were not observed in any study patient. All patients completed the study regularly [268].

Assessment: The study was downgraded to evidence level 3 because of the small population and uncertainties regarding randomization and allocation of treatment arms. Because the intervention was not superior to placebo in any of the efficacy endpoints examined and no other RCTs were found on this intervention, clear evidence of benefit is lacking here.

5.9.6 Nicotinamide

Population and study design: Nicotinamide (vitamin B3) is an essential cofactor for the provision of cellular ATP and DNA repair mechanisms, for example after ionizing or UV radiation damage. A study from Australia examined 30 immunocompetent patients with at least 4 nonhyperkeratotic AK on the face, hairless scalp or arms. The study design was interindividual, double-blind and placebo-controlled [266].

Intervention: Randomization to nicotinamide 1% in hydrophilic base or vehicle application twice daily for 6 months was performed.

Results: After 3 months, a mean lesion reduction of 10.0% (vehicle) versus 21.8% (nicotinamide) was recorded. This difference was significant for the active arm compared with therapy start. At 6 months, the reduction rates were 22.6% (vehicle) and 24.6% (nicotinamide) but this improvement was now not significant. Men tended to show a better lesion response to nicotinamide. 2 patients terminated the study

prematurely. However, more detailed data regarding tolerability and the occurrence of side effects were not presented [266].

Assessment: This topical intervention should not be confused with the systemic administration of nicotinamide, which has value in the primary and secondary prevention of non-melanocytic skin cancer. In this study, only the endpoint of mean lesion reduction at 3 months showed significant superiority for topical nicotinamide. However, the magnitude of the effect compared with placebo appears small and was no longer evident at the later time point after 6 months. Therefore, clear evidence of benefit is lacking to date.

5.9.7 **Ingenol disoxate**

See [Chapter 5.6.4](#).

5.9.8 **DNA repair enzymes**

Topical lotion with DNA repair enzymes vs. placebo

Population and study design: Stoddard et al. evaluated the efficacy of a topical lotion containing DNA repair enzymes as a field therapy for AKs in a double-blind RCT involving a total of 15 patients with AK on the face or scalp. The sample included a total of 10 men and 5 women [270].

Intervention: DNA repair lotion or placebo was self-applied to the treatment area twice daily for 8 consecutive weeks by the patient.

Results: Compared to baseline, patients using the repair enzyme had significantly fewer AKs after 8 weeks of treatment than patients using the control lotion. Specifically, the number of AKs decreased by 46.6 % in the DNA repair enzyme group, while it decreased by 32.7% in the placebo group.

Assessment: These results suggest that topical DNA repair enzymes may help reduce the number of AKs in individuals with moderately to severely photodamaged skin. However, further studies with a larger population are needed to draw definitive conclusions.

Topical lotion containing DNA repair enzymes vs. sunscreen filters (UV-B, UV-A, SPF 100+)

Population and study design: An RCT was conducted to evaluate the efficacy of a new class I medical device (MD, DNA repair enzymes) for the prevention and treatment of AKs compared with conventional sunscreen alone (SPF 100+). The medical device consists of physical and chemical UVA-UVB filters (corresponding to SPF 100+) and active ingredients with antioxidant and repairing effects, the most important of which is DNA repair complex (a complex of amino acids, acetyl tyrosine and proline, ATP, and plant protein hydrolysate). The sample included 90 participants, including 62 immunocompetent and 28 OTR. Mean age was 75.98 years; median duration of immunosuppression was 11.43 years [259].

Interventions: Included patients applied the medical device, lotion with DNA repair enzymes or sunscreen twice daily (morning and early afternoon) for 6 months.

Results: In immunocompetent patients who used the lotion with DNA repair enzymes, the mean number of AKs at the end of the study was reduced by 54.7% versus 9.43%

with sunscreen. For OTRs, the overall reduction after using lotion with DNA repair enzymes MD was 36.7% compared to 14.3% with sunscreen. The prevalence of NMSCs was 11.11 in patients treated with DNA repair enzymes MD and 17.18 with sunscreen; the incidence was 19.7 in patients treated with DNA repair enzymes MD and 32.1 in those treated with sunscreen.

Assessment: The power of the study is limited due to the unblinded design. Furthermore, patient compliance may underestimate the results due to the long application period of 6 months. Also, the potential graft rejection rate was not investigated, although almost 1/3 of the patients were OTR.

5.9.9 SR-T100 gel

Population and study design: A randomized, double-blind, phase III study was conducted to evaluate the efficacy and safety of topical SR-T100 gel in the treatment of AK [271]. Patients with at least two clinically visible, non-hyperkeratotic and non-hypertrophic AK were enrolled in the study, and one of the lesions had to be greater than 4 mm in diameter. One of the lesions was confirmed histopathologically. A total of 113 patients with a mean age of 76 years were included.

Intervention: SR-T100 (n=76) or vehicle (n=37) were applied to a continuous or noncontinuous area of 25 cm² (approximately 0.3-0.5g study gel) under occlusion for at least 8 hours. The study included up to 16 weeks of treatment and an 8-week post-treatment period. Medications were applied daily with an occlusive dressing.

Results: In the SR-T100 and vehicle groups, 32.39% and 17.14% of patients, respectively, achieved complete healing of AK while 71.83% and 37.1% of patients, respectively, had at least 75% of AK healed. Severe local reactions were reported in only one patient using SR-T100. At least one adverse reaction occurred in 55.3% (42) and 51.4% (19) of patients, respectively, of which 13.2% (10/76) vs. 13.5% (5/37) were classified as serious. However, all were assessed as not treatment-induced. The skin reactions most commonly encountered included redness and burning or stinging sensation.

Assessment: This study involved a population of Taiwanese patients; thus the results have limited applicability to a European population. The drawback of the study was that not all treated AK lesions were confirmed histopathologically. Diagnostic uncertainty may contribute to the high proportion of healing rates in the vehicle group, as clinically diagnosed AK had a higher healing rate than histopathologically confirmed AK. The use of an occlusive dressing was another possible explanation for the high placebo effects. The results suggest that topical SR-T100 gel may be an effective and safe treatment for field-directed therapy of AK.

5.9.10 Resiquimod

Resiquimod activates toll-like receptors 7 and 8 and therefore has a strong similarity to imiquimod. However, in vitro studies suggest that resiquimod leads to greater immune activation through the additional activation of toll-like receptor 8 [277]. This was the rationale for testing resiquimod for use in AK. Our literature search revealed one study on resiquimod [274]. Szeimies et al. investigated resiquimod gel at various concentrations in a randomized, multicenter, double-blind phase II study. A total of 132 patients with 4-8 clinically typical, non-hypertrophic or hyperkeratotic AK within an area of 25 cm² on face or hairless scalp were included. 109 patients were male, 23 female. The mean age was 70 years. Immunosuppressed individuals were excluded.

Randomization was 1:1:1:1 interindividually to use resiquimod 0.01%, 0.03%, 0.06%, or 0.1% gel once daily three times a week for 4 weeks. Therapy was allowed to be repeated once 8 weeks later if results were inadequate. The overall lesion-free rate at 24 weeks was 77.1% (0.01%), 90.3% (0.03%), 78.1% (0.06%), and 85.3% (0.1%) in the intention-to-treat analysis. After only one cycle of therapy, it was 40.0% (0.01%), 74.2% (0.03%), 56.3% (0.06%), and 70.6% (0.1%), respectively. The overall proportion of patients with at least 75% lesion reduction at 24 weeks was 63% (0.01%), 81% (0.03%), 63% (0.06%), and 76% (0.01%), respectively. Twenty-eight patients terminated the study prematurely during the first cycle of therapy, and 3 patients terminated during the second cycle of therapy. Local adverse events at the application sites were the most common adverse events. They tended to occur more frequently in the higher concentration groups of resiquimod. Serious adverse events were also observed more frequently here: 0% (0.01%), 35% (0.03%), 16% (0.06%), and 38% (0.1%). They included erythema, edema, erosion and ulceration, exudation, scaling, crusting, and skin dryness. Similarly, at higher concentrations of resiquimod, flu-like symptoms such as joint pain, myalgia, headache, lethargy, fatigue, and rigor were also observed [274]. Resiquimod showed good efficacy even at low concentrations. In contrast, side effects increased significantly with higher concentrations. However, the assessment of efficacy remains problematic due to the lack of a placebo group within the study, especially since high cure rates were sometimes observed in placebo arms of other studies with similar populations. Therefore, based on the evidence we identified on resiquimod, no firm recommendations on its use in AK can be derived.

5.9.11 Sunscreen

Population and study design: An Australian study investigated regular use of a sunscreen with a SPF of 17 for UV-B and a broad spectrum filter for UV-A [269]. It included 588 patients over 40 years of age with 1-30 AK. The study was randomized but not blinded.

Intervention: As an intervention, approximately 1.5 ml of the sunscreen or placebo only (vehicle) was applied to a treatment area once in the morning and during the day if necessary for 7 months.

Results: 157 patients terminated the study prematurely. After 7 months, patients in the active arm showed a mean absolute lesion reduction of 0.6, whereas a mean lesion increase of 1.0 was observed in the placebo arm. The relative risk of new lesions was 0.62 (95% CI 0.57-0.71) in patients with regular sunscreen use compared with placebo. The median number of remissions of histologically confirmed lesions was 25% (sunscreen) versus 18% (vehicle). A total of 333 (sunscreen) and 508 (vehicle) new lesions were observed during the study. Regarding treatment adherence, 81% of patients reported applying the cream once daily for at least 80% of the observation period. Here, there was no difference in the amount applied between the two groups. More detailed evidence on tolerability or side effects was not reported [269].

Assessment: Sunscreens with effective filters in the UV-B and UV-A range are an important and scientifically proven preventive measure of AK and non-melanocytic skin cancer. Regular application of an effective photoprotective filter is a basic measure and should be consistently applied in addition to any other intervention or combination of therapies.

5.9.12 Retinoids

5.25	Evidence-based statement	checked 2022
LoE 2	Data currently do not allow recommendations for therapy of actinic keratosis with topical or systemic retinoids.	
	[122] , [278] , [279] , [280] , [281] 2: De novo research	
	Strong consensus	

Retinoids are derivatives or synthetic analogues of retinoic acid, an end product of vitamin A metabolism. They have pleiotropic effects on proliferation and differentiation of keratinocytes. According to chemical and pharmacological properties, three generations of retinoids are distinguished, which can be used both topically and systemically. First-generation substances include tretinoin (all-trans-retinoic acid), isotretinoin (13-cis-retinoic acid), and alitretinoin (9-cis-retinoic acid). Second-generation retinoids have an aromatic ring in their structure. For example, the substances acitretin and etretinate fall into this category. Poly-aromatic retinoids such as adapalene and arotinoid are classified as third generation [\[282\]](#).

Some retinoids such as acitretin have been shown to have a chemopreventative effect for the development of epithelial skin tumors such as basal cell carcinoma and SCC. However, this effect seems to be temporally linked to the respective treatment interval [\[283\]](#). The place of retinoids in the therapy of manifest AK is less clear. The de novo literature search identified 4 individual studies investigating isotretinoin, tretinoin and adapalene in topical application and etretinate in systemic application (oral) [\[278\]](#), [\[280\]](#), [\[279\]](#), [\[281\]](#). All studies are relatively old. Three studies were excluded from making the evidence-based recommendation because either none of the critical effectiveness endpoints were reported [\[284\]](#), or a sequential combination of 5-fluorouracil in combination with retinoids was evaluated [\[141\]](#), [\[285\]](#).

The retinoid etretinate studied by Moriarty et al. in 1982 [\[281\]](#), is currently no longer available in Germany [\[281\]](#). The other interventions studied either had a low effect size [\[278\]](#), [\[280\]](#), or were not compared against placebo, which makes a robust assessment of effectiveness difficult [\[279\]](#). Therefore, no safe, evidence-based recommendations on the role of retinoids in the treatment of AK can currently be derived.

Table 30: Overview of the included single studies on retinoids

Study	Interventions	Single AK	Multiple AK	Field cancerization	Immunosuppression
Alirezai 1994 [278]	Isotretinoin 0.1% cream vs. placebo		X		
Misiewicz 1991 [279]	Tretinoin 0.05% cream vs. arotinoid methyl sulfone 0.05% cream (Ro 14-9706)	X	X		
Kang 2003 [280]	Adapalene 0.1% gel vs. Adapalene 0.3% gel vs. placebo		X		
Moriarty 1982 [281]	Etretinate 75 mg orally 1x/d vs. placebo	unclear	unclear	unclear	unclear

Isotretinoin 0.1% cream vs. placebo

Population and study design: Alirezai et al. studied the efficacy of isotretinoin (13-cis-retinoic acid) in 0.1% cream base in 100 patients in France. Patients had at least 5 AK on hairless scalp, face or arms including hands [278].

Intervention: As the intervention, 0.3-0.5 g of isotretinoin 0.1% cream was applied twice daily to the field to be treated for 24 weeks and compared interindividually with vehicle.

Results: There was a significant mean lesion reduction of 3.9 (isotretinoin) versus 1.7 (vehicle) on the face. Complete or partial healing of lesions was observed here in 66% (isotretinoin) versus 45% (vehicle). For lesions on the hairless scalp, mean lesion reductions were 4.1 (isotretinoin) vs. 3.6 (vehicle). This difference was not significant. Similarly, there was no significant change in lesions on the arms or hands, with a mean lesion reduction of 2.9 (isotretinoin) vs. 1.0 (vehicle). Signs of local skin irritation such as erythema, scaling, burning, or itching were more frequent in the isotretinoin arm [278].

Assessment: In summary, this study showed significant improvement over placebo in only two efficacy endpoints examined, whereas lesion reduction on the capillitium and arms or hands was not significantly different. The strength of the effect in terms of mean lesion reduction appears rather small.

Tretinoin 0.05% cream vs. arotinoid methyl sulfone 0.05% cream

Population and study design: Another study compared a topical formulation of tretinoin (all-trans retinoic acid) with the third-generation retinoid arotinoid methyl sulfone (Ro 14-9706, see above) in 26 patients with more than three lesions on the face [279].

Intervention: This was an intra-individual hemiparesis comparison of tretinoin 0.05% cream with Ro 14-9706 0.05% cream applied to both sides of the face twice daily for 16 weeks.

Results: After 16 weeks, the mean lesion reduction was 37.8% for Ro 14-9706 and 30.3% for tretinoin (significant compared with therapy initiation). Complete healing of all lesions occurred in 0% (Ro 14-9706) and 8% (tretinoin) of patients. A partial response was observed in 48% (Ro 14-9706) and 40% (tretinoin), with no significant difference in efficacy between the two faces. Treatment with Ro 14-9706 was better tolerated in terms of redness and scaling of the treatment areas. In contrast, therapy with tretinoin had to be interrupted or reduced in 58% of cases due to adverse side effects [279].

Assessment: Due to a missing placebo arm of the study, a robust assessment of the effectiveness of the two interventions investigated is possible only to a limited extent. Furthermore, the endpoint "complete healing of all lesions" reaches low values of 0-8% compared to other interventions, suggesting a rather low effect size. This is in contrast to a high percentage of therapy interruptions or dose reductions of tretinoin.

Bercovitch et al. studied a combination of tretinoin 0.05% cream with 5-fluorouracil 5% cream in 19 patients with multiple AK [285]. However, this study was excluded from an evidence-based recommendation because of the combination of two different agents.

Adapalene 0.1% and 0.3% gel vs placebo

Population and study design: A three-arm, interindividual randomized, controlled, investigator-blinded study compared adapalene gel in 90 Caucasian patients (Fitzpatrick skin types I and II) with 5 to 25 AK or solar lentiginos with a minimal clinical spread of 2 mm per lesion [280].

Intervention: Patients were randomized in equal proportions to adapalene 0.1% gel, adapalene 0.3% gel, or vehicle. Treatment was initially applied once daily. If well tolerated, it was increased to twice daily application after 4 weeks and therapy was continued for a maximum of 9 months.

Results: At the end of therapy, there was a mean absolute lesion reduction of 0.5 (adapalene 0.1%) and 2.5 (adapalene 0.3%), whereas a lesion increase of 1.5 was observed with placebo. Global response after IGII was significantly better for adapalene 0.3% gel versus placebo at 3, 6, and 9 months and significantly better for adapalene 0.1% versus placebo at 1 and 6 months. Overall, 62% (adapalene 0.1%) and 66% (adapalene 0.3%) of treated patients were evaluated as completely ("clear"),

almost completely ("marked"), or moderately ("moderate") healed. This rate compared with 34% in the placebo arm. No serious side effects of adapalene were observed, with 3 patients terminating the study prematurely. Erythema, scaling, dryness, burning and pruritus were recorded more frequently in the two active arms and were consistently classified as mild. Mild dermatitis of the treated area occurred most frequently, in 40% (adapalene 0.1%), 25% (adapalene 0.3%) and 9% (placebo) [280].

Rating: Because the study selectively reported endpoints, it was downgraded to evidence level 3. Overall, adapalene at both concentrations showed significantly better efficacy with respect to the efficacy endpoints studied compared with placebo. However, the magnitude of the effect appears rather small, especially when measured by the absolute mean lesion reduction. This is in contrast to more frequent, albeit mild, side effects in both active arms, so that further studies are needed for a harm-benefit assessment.

Etretinate vs. placebo

Population and study design: The retinoid etretinate was compared with placebo in systemic administration in one study. It was a randomized, double-blind, crossover study. Fifty patients with histologically confirmed AK were included. However, information on the number and location of lesions is lacking. Also, it remains unclear whether patients with field cancerization or immunosuppression were within the studied population [281].

Intervention: Patients received either etretinate at a dose of 75 mg once daily or placebo for 2 months, followed by the previously unadministered therapy in each case (crossover study).

Results: After the first 2 months, the proportion of patients with complete healing was 22.7% (5/22) on etretinate compared with 0% on placebo. A partial response was defined as at least 50% size reduction in at least 75% of all treated lesions. At 2 months, 63.6% (14/22) of patients treated with etretinate but only 4.3% (1/23) of participants on placebo achieved a partial response. At the end of therapy, of 44 patients who fulfilled the protocol regularly with etretinate, 37 (84%) showed complete healing of all lesions or a partial response compared with only 2 patients (5%) on placebo. Adverse effects of etretinate were dry mouth (86.1%), unspecified rash with pruritus (15.9%), increased skin scaling (70.4%), and nausea (4.5%). Dose reduction was carried out in 17 patients, and 6 patients terminated the study prematurely due to adverse events [281].

Assessment: The study was downgraded to an evidence level of 3 due to ambiguities in randomization and allocation of treatment arms. In addition, endpoints were not fully reported (reporting bias). Etretinate is not available in Germany due to unfavorable pharmacokinetic properties such as strong lipophilicity or a long half-life.

5.10 Summary and balancing presentation of approved therapy options

Table 31: Balance sheet of ablative and physical procedures

Intervention	TA	Type and application of the intervention	Anatomical location	Clearance rates ¹	Side-effects and tolerability ²	Cosmesis ³	Duration of the treatment ⁴	Direct treatment costs per cycle ⁵	Practicability ⁵		Strength of recommendation and evidence base by subgroups ⁷			
									Physician	Patient	Single AK (1-5)	Multiple AK (≥6)	Field cancerisation	Immuno-suppression
Cryosurgery	L	One to two freeze-thaw cycles with liquid nitrogen (-196°C)	Face, scalp	++/+++										
		Cold exposure of the target lesions for 15-60 seconds ("whitening")	Neck	Lesion-specific clearance rate: 41.9%-88%	+++	+ / ++	∞	€	++++	+++	↑	↑		
		Open spray method	Trunk	Patient-specific clearance rate: 25%-90.3							2	2		
		Contact method (cryo stamp, cryo probe)	Extremities											
Surgical procedures ⁵	L	Curettage ± electrocautery	Face, Scalp	+++	++	+ / ++								
		Shave excision	Neck	(No data available from RCT) ⁸	(No data available from RCT) ⁸	(No data available from RCT) ⁸	∞	€-€€	+++	++	↑			↑
		Complete excision	Trunk								EC			EC
			Extremities											
Chemo-exfoliation	L+F	Ablation of superficial skin layers using chemical agents (e.g. trichloroacetic acid, Jessner's solution, phenol)	Face, Scalp	++										
			Neck	Lesion-specific clearance rate: 31.9%	++/+++	+++	∞	€-€€	++	++	↔	↔	↔	
			Trunk	Patient-specific clearance rate: 11.8%-92%							3	3	3	
			Extremities											
Dermabrasion ⁶	L+F	Mechanical removal of the uppermost skin layers up to the dermoepidermal junction zone	Face, Scalp	+	+	++								
			Neck	(No data available from RCT) ⁸	(No data available from RCT) ⁸	(No data available from RCT) ⁸	∞	€€	+ / ++	+				
			Trunk											
			Extremities											

Intervention	TA	Type and application of the intervention	Anatomical location	Clearance rates ¹	Side-effects and tolerability ²	Cosmesis ³	Duration of the treatment ⁴	Direct treatment costs per cycle ⁵	Practicability ⁶		Strength of recommendation and evidence base by subgroups ⁷			
									Physician	Patient	Single AK (1-5)	Multiple AK (≥6)	Field cancerisation	Immuno-suppression
Potassium hydroxide 5% solution (Solcera [®])	L	Single and well defined lesions <2 cm in diameter Max. 10 lesions 1 cycle: 2x/d over 14 days, then 14 days treatment-free interval (max. 3 cycles = 12 weeks) Availability as a medical device	Face, Scalp Neck Trunk Extremities	++ Lesion-specific clearance rate: 69.9%-83%. Patient-related complete healing rate: 54.9	+++	++	☹☹☹☹☹	€	+++	++++	↔ 3	↔ 3		
Laser ⁶	L+F	Ablative laser treatment (e.g. CO ₂ laser, Er:YAG laser)	Face, Scalp Neck Trunk Extremities	++ Lesion-specific clearance rate: 72.4%-91.1% Patient-specific clearance rate: 8%-65.3%	++	++/+++	☹	€-€€	+++	++	↔ 2-3	↔ 2-3	↔ 2-3	
	L	Non-ablative laser procedures ⁶ (e.g. Nd:YAG laser, fractional 1540 nm laser)		++ (No data available from RCT) ⁸	+++ (No data available from RCT) ⁸	++ (No data available from RCT) ⁸	☹	€-€€	+++	+++	↔ EC	↔ EC		

¹ Semiquantitative assessment taking into account lesion- and patient-related response rates: + little effective, ++ moderately effective, +++ effective, ++++ very effective
² Semiquantitative assessment taking into account frequency and severity of therapy-mediated side effects: + poorly tolerated/ many side effects, ++ moderately tolerated, +++ well tolerated, ++++ very well tolerated
³ Semiquantitative assessment taking into account investigator- and patient-assessed endpoints such as dyspigmentation, improvement of hyperkeratosis, global assessment: + poor, ++ moderate, +++ good, ++++ excellent
⁴ ☹ short (<1 week), ☹☹ medium (1-6 weeks), ☹☹☹ long (>6 weeks)
⁵ € <100 Euro, €€ 100-500 Euro, €€€ >500 Euro; only direct treatment costs per cycle performed were considered; topical drugs were based on the public pharmacy dispensing prices in Germany (as of August 2021); procedural procedures were based on the assessments of the Gebührenordnung für Ärzte (GOÄ, as of August 2021).
⁶ Taking into account expert assessments
⁷ Strength of recommendation: Can ↔, Should ↑, Shall ↑↑; indication of evidence levels according to Oxford 2011.
⁸ When applying the mentioned search strategy and inclusion and exclusion criteria
 Abbreviations: L=lesion-directed, F=field-directed, AK = actinic keratosis(s), EC = expert consensus, FK = field cancerization, RCT = randomised controlled trial, TA = therapeutic approach.

Table 32: Balance sheet drug interventions

Intervention	TA	Mechanism of action Application	Recommended max. area of the treatment field	Approval for anatomical location	Efficacy ¹	Side-effects and tolerability ²	Cosmesis ³	Duration of treatment ⁴	Immediate treatment costs per cycle ⁵	Practicability ⁶		Strength of recommendation and evidence base by subgroups ⁷			
										Doctor	Patient	Single AK (1-5)	Multiple AK (≥6)	Field canze- risation	Immuno- suppression
Diclofenac sodium 3% gel (Solaraze®) (Solacutan®) (Diclofenac acis®) (Diclofenac AbZ®) (Diclofenac-ratiopharm®)	F	Cyclooxygenase-2 inhibitors 2x daily for 60-90 days	8g/d or max. 200 cm²	Face and scalp	++ Lesion-specific clearance rate: 51.8%-81.0 Patient-specific clearance rate: 27%-50%.	+++ /++++	+ /+++	☒☒☒	€-€€	++++	++	↑ 1	↑ 1	↑ 2	↑ 3
5-Fluorouracil 5% cream (Efudix®)	F	Cytostatic 2x daily until erosion stage (usually 2-4 weeks) Application with finger cloth or glove No nucleoside analogues (e.g. brivudine, sorivudine) for at least 4 weeks	500 cm² (approx. 23 x 23 cm)	Face and scalp Neck Trunk Extremities	+++ /++++ Lesion-specific clearance rate: 47%-94% Patient-specific clearance rate: 38%-96%.	++	++ /++++	☒☒☒	€	+++	+++	↑ 1	↑ 1	↑ 2	
5-Fluorouracil 4% cream (Tolak®)	F	Cytostatic 1x daily for 4 weeks No nucleoside analogues (e.g. brivudine, sorivudine) for at least 4 weeks	None (in studies 240-961 cm²)	Face and scalp	+++ Patient-specific clearance rate: 80.5%	+++	+++	☒☒☒	€	+++	+++	↑ 2	↑ 2	↑ 2	
5-Fluorouracil 0.5% with salicylic acid 10% in solution (Actikerall®)	F+L	Cytostatic and keratolytic agent 1x daily until the lesions have cleared completely	25 cm²	Face and scalp Neck Trunk Extremities	+++ Lesion-specific clearance rate: 39.4%-98.7% Patient-specific clearance rate:	+++	+++	☒☒☒☒☒	€	+++	++	↑ 2	↑ 2	↑ 2	

Intervention	TA	Mechanism of action Application	Recommended max. area of the treatment field	Approval for anatomical location	Efficacy ¹	Side-effects and tolerability ²	Cosmesis ³	Duration of treatment ⁴	Immediate treatment costs per cycle ⁵	Practicability ⁶		Strength of recommendation and evidence base by subgroups ⁷			
										Doctor	Patient	Single AK (1-5)	Multiple AK (≥6)	Field canze-ri-sation	Immuno-suppression
		(max. 12 weeks) No nucleoside analogues (e.g. brivudine, sorivudine) for at least 4 weeks			55.4%										
Ingenol mebutate gel (Picato®)	F	Garden spurge extract (cytotoxic) 0.015% (face and scalp): 1x daily for 3 consecutive days 0.050% (trunk, extremities): 1x daily for 2 consecutive days	25 cm ²	Face and scalp Neck Trunk Extremities	+++ Face/ scalp: Lesion-specific clearance rate: 62.9%-87.2% Patient-specific clearance rate: 36.4%-61.6% Extremities/ trunk: Lesion-specific clearance rate: 73%-100%. Patient-specific clearance rate: 22%- 54.4%	+(increased incidence of skin tumours in treatment fields)	++	80	€	+++	+++	↓↓↓ 2	↓↓↓ 2	↓↓↓ 2	↓↓↓ 2
Imiquimod 3.75% cream (Zyclara®)	F	Toll-like receptor 7 agonist 1x daily for 2 weeks, 2 weeks treatment-free interval, 1x daily for 2 weeks (interval therapy), apply in the evening before going to bed. per application up to 2 sachets of 250 mg imiquimod cream per	None The treatment area is the entire face or the entire hairless scalp.	Face and scalp	+++ Lesion-specific clearance rate: 34.0%-81.8%	+++	+++	80	€€	+++	+++	↑ 2	↑ 2		

Intervention	TA	Mechanism of action Application	Recommended max. area of the treatment field	Approval for anatomical location	Efficacy ¹	Side-effects and tolerability ²	Cosmesis ³	Duration of treatment ⁴	Immediate treatment costs per cycle ⁵	Practicability ⁶		Strength of recommendation and evidence base by subgroups ⁷			
										Doctor	Patient	Single AK (1-5)	Multiple AK (≥6)	Field cancerisation	Immuno-suppression
		sachet													
Imiquimod 5% cream (Aldara®)	F	Toll-like receptor 7 agonist 3 times a week for 4 weeks, in case of residual lesions for additional 4 weeks (max. 8 weeks), apply in the evening before going to bed (leave for at least 8 h).	Maximum dose is the contents of one sachet (250 mg)	Face and scalp	+++ Lesion-specific clearance rate: 45.1%-93.6% Patient-specific clearance rate: 24%-85%	+++	+++	☒☒☒☒☒☒	€€	+++	+++	↑ 1	↑ 1	↑ 1	↔ 2 OLU
ALA red light PDT: ALA nanoemulsion (Ameluz®)	F	Precursor of protoporphyrin (photosensitizer) Pre-treatment, application of ALA, drying for 10 min, light-protective dressing, incubation for 3 h, illumination with suitable red light sources, second cycle after 12 weeks if necessary	Layer thickness approx. 1 mm Lesion or entire cancerized fields of up to 20 cm ²	Face and scalp Neck Trunk Extremities	+++/ Lesion-specific clearance rate: 58.0%-94.3% Patient-specific clearance rate: 50%-91%	++	+++/ ++++	☒	€€-€€€	++	++	↑ 1	↑ 1	↑ 1	

Intervention	TA	Mechanism of action Application	Recommended max. area of the treatment field	Approval for anatomical location	Efficacy ¹	Side-effects and tolerability ²	Cosmesis ³	Duration of treatment ⁴	Immediate treatment costs per cycle ⁵	Practicability ⁶		Strength of recommendation and evidence base by subgroups ⁷			
										Doctor	Patient	Single AK (1-5)	Multiple AK (≥6)	Field cancerisation	Immuno-suppression
ALA red light PDT: ALA patch (Alacare®)	L	Precursor of protoporphyrin (photosensitizer) Apply patch for 4 h, illuminate with red light (37 J/cm ²), no St. John's wort for at least 2 weeks, second cycle if no clearance after 12 weeks	1 patch 4 cm ² (with 8 mg ALA) Lesion max. 1.8 cm diameter (max. 6 patches per treatment session)	Face and scalp	+++/ Lesion-specific clearance rate: 63%-89% Patient-specific clearance rate: 62%-67%	++	++/ +++	2-3	€€-€€€	+++		↑ 1	↑ 1	↑ 1	
MAL red light PDT (Metvix®)	F	Precursor of protoporphyrin (photosensitizer) Pre-treatment, application of MAL, occlusive dressing for 3 h, illumination with suitable red light sources, second cycle after 12 weeks if necessary	Layer thickness approx. 1 mm Lesion, for field cancerization up to approximately 20 cm ²	Face and scalp	+++/ Lesion-specific clearance rate: 67.1%-90.3 Patient-specific clearance rate: 31.4%-78%	++	+++/ ++++	2-3	€€-€€€	++/ +++	++	↑ 1	↑ 1	↑ 1	↑ 3
ALA daylight PDT (Ameluz®)	F	Precursor of protoporphyrin (photosensitizer) Application of chemical light protection filter, after 15 min pre-treatment, application of ALA without occlusion, within 30 min exposure to natural daylight for 2 h, second cycle after 12	None (apply thin layer) Lesion or entire cancerized fields	Face and scalp	+++ Patient-specific clearance rate: 27.5%-42.9% Lesion-specific clearance rate: 79.7%-79.8%	+++/ ++++	+++	2-3	€€	++	++++	↑ 1	↑ 1	↑ 1	

Intervention	TA	Mechanism of action Application	Recommended max. area of the treatment field	Approval for anatomical location	Efficacy ¹	Side-effects and tolerability ²	Cosmesis ³	Duration of treatment ⁴	Immediate treatment costs per cycle ⁵	Practicability ⁶		Strength of recommendation and evidence base by subgroups ⁷			
										Doctor	Patient	Single AK (1-5)	Multiple AK (≥6)	Field cancerisation	Immuno-suppression
		weeks if necessary													
MAL daylight PDT (Metvix®) (Luxerm®)	F	Precursor of protoporphyrin (photosensitizer) Application of chemical light protection filter, after pre-treatment drying, application of MAL without occlusion, within 30 min exposure to natural or simulated daylight (Metvix® only) for 2 h, second cycle after 12 weeks if necessary	None (apply thin layer) Lesion and/or field cancerization	Face and scalp	+++ Patient-specific clearance rate: 27.5%-38.8% Lesion-specific clearance rate: 77.2%-89.2%	+++/ ++++	+++	∞	€€	++	++++	↑ 1	↑ 1	↑ 1	
Tirbanibulin (Klisyri®)	F	Topical microtubule inhibitor 1x/d over 5 consecutive days	25 cm ²	Face and scalp	++/ +++ Patient-specific clearance rate: 44%-54% Lesion-specific clearance rate: 76%-82%	+++/ ++++	+++	∞	€€	+++	+++	↑ 2	↑ 2	↑ 2	

Intervention	TA	Mechanism of action Application	Recommended max. area of the treatment field	Approval for anatomical location	Efficacy ¹	Side-effects and tolerability ²	Cosmesis ³	Duration of treatment ⁴	Immediate treatment costs per cycle ⁵	Practicability ⁶		Strength of recommendation and evidence base by subgroups ⁷			
										Doctor	Patient	Single AK (1-5)	Multiple AK (≥6)	Field cancerisation	Immuno-suppression
<p>¹ Semiquantitative assessment taking into account lesion- and patient-related response rates: + little effective, ++ moderately effective, +++ effective, ++++ very effective</p> <p>² Semiquantitative assessment taking into account frequency and severity of therapy-mediated side effects: + poorly tolerated/ many side effects, ++ moderately tolerated, +++ well tolerated, ++++ very well tolerated</p> <p>³ Semiquantitative assessment considering investigator- and patient-assessed endpoints such as dyspigmentation, improvement of hyperkeratosis, global assessment: + poor, ++ moderate, +++ good, ++++ excellent</p> <p>⁴ ☐ short (<1 week), ☐☐ medium (1-6 weeks), ☐☐☐ long (>6 weeks)</p> <p>⁵ € <100 Euro, €€ 100-500 Euros, €€€ >500 Euros; only direct treatment costs per cycle performed were considered; topical drugs were based on the public pharmacy dispensing prices in Germany (as of August 2021); procedural procedures were based on the assessments of the Gebührenordnung für Ärzte (GOÄ, as of August 2021).</p> <p>⁶ Taking into account expert opinions</p> <p>⁷ Strengths of recommendation: May ⇌, Should ↑, Shall ↑↑; indication of evidence levels according to Oxford 2011</p> <p>Abbreviations: L=lesion-directed, F=field-directed, AK = actinic keratosis(s), OLU = off-label use, TA =therapy approach.</p>															

6 Therapy of cheilitis actinica

R.-M. Szeimies, C. Berking, T. Dirschka, A. Hauschild, K. Wermker, U. Leiter, L. Schmitz

6.1 Literature search and study selection

For the evidence-based recommendations and statements, a Medline literature search was conducted in September 2020 that included only comparative randomized or nonrandomized, observational or cross-sectional studies. Study design included RCTs, systematic reviews or meta-analyses of RCTs, with a minimum study population of $n \geq 10$.

Casuistics (single and collective), descriptive reviews, papers with a study population less than 10, qualitative reports without quantifiable measurement precision and experimental studies were excluded.

Thirty-five papers were identified after appropriate abstract searches, and 33 full texts were analyzed, including 5 systematic reviews and meta-analyses and 25 individual studies.

6.2 Indication and natural history of the disease

6.1	Consensus-based recommendation	new 2022
EC	The indication for therapy of cheilitis actinica should be made in synopsis of the clinical presentation, risk factors (e.g. immunosuppression, cumulative UV exposure, involvement of the entire lower lip, involvement also of the upper lip), comorbidities, life expectancy and the patient's wishes.	
	Strong consensus	

6.2	Consensus-based recommendation	new 2022
EC	Before choosing a treatment procedure, a biopsy should be obtained for diagnostic confirmation and to exclude invasive squamous cell carcinoma.	
	Consensus	

6.3	Consensus-based recommendation	new 2022
EC	Histological control shall be carried out if there is clinical evidence of a lack of response or incomplete response to therapy.	
	Strong consensus	

Actinic cheilitis is divided into an acute and a chronic form. While the former corresponds to dermatitis solaris, the chronic form (cheilosis actinica or cheilitis actinica chronica, CA for short) is a variant of AK in the lip red area. In more than 90% of cases it is localized in the area of the lower lip. Frequently, the entire surface of the red lip is affected, and there is a picture of an extensive, partially atrophic, partially erosive or even scaly skin surface, in the sense of a field cancerization as in other body regions. The erosive-crustose form is also called cheilitis abrasiva praecancerosa (manganotti) and, like all other forms, may progress to invasive SCC if prolonged. Analogous to the progression or regression of AK on other body skin, the course of CA is difficult to predict. However, the occurrence of chronic photodamage in the transitional epithelium with lack of protective functions such as keratinization and melanocyte activity is accompanied by a higher risk of transition into invasive SCC. Although clear figures on this are lacking, a recent review reported this risk to be 10-30% [286], [287]. Since 95% of SCC of the lip arise on a CA [287] the indication for treatment of a CA should be made generously, taking into account any other risk factors such as immunosuppression, but also weighing factors such as comorbidities, life expectancy and patient wishes.

6.3 Therapy basics

For the treatment of CA, almost all therapeutic options mentioned for AK are available. However, due to frequent infestation of the entire lip in the sense of a field cancerization, a field-directed therapy is required; i.e., the objective should be treatment of the entire lip region. In this respect, the use of treatment procedures that lead to impairments such as ulceration and crust formation over a longer period of time is often difficult for patients to tolerate because speech and food intake may be restricted along with cosmetic disturbance.

The treatment options evaluated in the literature review predominantly include topical, drug-based procedures, as corresponding studies of higher quality exist for these.

Table 33: Therapy methods for cheilitis actinica

Ablative procedures	Drug-based procedures
Surgical procedures <ul style="list-style-type: none"> • Vermilionectomy (surgical) • Lip shave 	Topical drug-based procedures <ul style="list-style-type: none"> • Diclofenac sodium 3% • 5-fluorouracil 5% cream • Imiquimod 5% and 3.75% cream
Laser procedures (ablative) <ul style="list-style-type: none"> • CO₂ laser • Er:YAG laser 	Photodynamic therapy <ul style="list-style-type: none"> • Red light PDT (ALA, MAL) • Patch PDT (patch application) (ALA) • Daylight PDT (MAL)
Cryosurgery	
Chemical peeling	

Some systematic reviews also compare physical methods (surgery, laser), so these are listed as well, especially since the results may well hold up against topical therapies [287], [288]. Post-therapeutic assessment most commonly includes clinical response. In a meta-analysis of 49 studies, dermatoscopy outcome is used in only one study and post-therapeutic biopsies for histopathological assessment are carried out in 34 studies [288].

6.4 Ablative procedures

Ablative procedures include vermilionectomy, i.e., strip surgical removal of affected lip skin followed by mobilization of lip mucosa as a substitute, laser treatment using ablative laser systems (CO₂, Er:YAG laser), and electrodesiccation using radiofrequency currents, chemical peeling and cryosurgery [289].

6.4.1 Surgical procedures

6.4	Evidence-based recommendation	new 2022
GoR A	Surgical removal of cheilitis actinica (e.g., by vermilionectomy or lip-shave with histological workup and information on the status of resection margins) shall be offered in cases of extensive involvement.	
LoE 1	[286], [287], [288], [289], [290], [291] 1: De novo research	
	Consensus	

Surgical procedures (mucosal advancement flap, high energy electrodesiccation, lip shave, dermabrasion) were evaluated in 3 systematic reviews [287], [288], [289]. In the systematic review and meta-analysis by Carvalho et al. [288] a total of 283 cases of CA were treated in such a way in 10 studies. Malignant transformation occurred in 2.5% of surgically treated cases. The weighted remission rate was higher for surgical procedures (92.8%) than for nonsurgical procedures (65.9%). The recurrence rate was lower for surgical procedures (8.4%) than for nonsurgical therapies (19.2%) [288].

In the work by Salgueiro et al. [289], 6 studies with a total of 104 patients were evaluated under the term "surgery". The procedures studied were vermilionectomy, chemical peeling, cryosurgery and electrodesiccation. Clinical improvement for vermilionectomy was 100% and side effects were described in 10% to 100% of cases, including paresthesia (10-33.3%), infection (10%) and necrosis (10%) [289].

Also, in the prospective, comparative work by Robinson [286], which is also partially included in the systematic reviews, topical 5-fluorouracil 5% solution or chemical peel with 50% trichloroacetic acid showed no recurrences during the median follow-up of 49-51 months for vermilionectomy and CO₂ laser treatment, whereas 5-fluorouracil had 5 and chemoexfoliation had 7 clinically suspicious recurrences (10 patients per group each) [286].

In an intraindividual case review between electrodesiccation and CO₂ laser in 14 patients, one half of each lower lip with CA was ablated with laser or electrodesiccation. Complete re-epithelialization in the laser area was seen after 14.4 days, whereas the electrodesiccation area healed only after 23.1 days. A clear statement regarding recurrence rates in the respective treatment areas was not made [290]. In a systematic review, vermilionectomy was listed as the most operator-dependent therapeutic procedure because scalpel incisions and suture closure affect optimal lesion clearance and wound healing [292].

In summary, surgical therapeutic procedures are highly effective in the treatment of CA and are particularly useful in cases of extensive spread. Vermilionectomy with scalpel has the additional advantage that the entire excidate is available for histopathologic evaluation and a statement can be made regarding the status of resection.

6.4.2 Laser therapy

6.4.2.1 Ablative laser procedures

6.5	Evidence-based recommendation	new 2022
GoR 0	Treatment of cheilitis actinica with ablative laser procedures (CO ₂ , Er:YAG) may be offered.	
LoE 1	[286], [287], [288], [289], [290], [292], [293], [294], [295], [296] 1: De novo research	
	Strong consensus	

Numerous studies have investigated the use of ablative laser procedures in CA [290], [286], [293], [294], [295], [296]. Using CO₂ or Er:YAG lasers, the diseased tissue was ablated layer by layer. Due to the high energy absorption of the laser light in water, this occurs with both laser systems under vaporization, so that a precise destruction of the CA is possible. Due to a thermally induced coagulation zone, which is somewhat more pronounced with the CO₂ laser, intraoperative bleeding can be avoided by sealing the vessel. However, if the tissue is completely vaporized, histopathological examination is not possible. The procedure is highly operator-dependent; if ablation is too shallow, recurrences are common. Aggressive, overly deep ablation can result in wound healing problems and scarring. Herpes recurrence prophylaxis with aciclovir or its derivatives is indicated.

A prospective comparative study [286] compared the use of CO₂ laser with 5-FU, peeling, and vermilionectomy. With equal effectiveness of the laser and the surgical procedure, laser ablation resulted in fewer postoperative complications [286]. In a comparison of electrodesiccation with CO₂ laser in a hemisphere comparison for histologically confirmed CA in 14 patients in a randomized trial, the CO₂ laser performed significantly better in terms of time to re-epithelialization at the same healing rate (see Chapter 6.4.1) [290]. In a prospective study of 19 patients, CO₂ laser vermilionectomy was used to ablate CA from the side with a sharply focused laser beam so that the removed piece of tissue could be submitted for histological evaluation. Complete re-epithelialization occurred after 4-7 weeks. Recurrences were not reported in [293]. In another prospective uncontrolled study of 13 patients, CO₂ laser vaporization proved to be a successful treatment modality. No recurrence occurred during the median follow-up period of eleven months. However, three patients showed scarring and one patient experienced hyperesthesia [294]. In a collective case series of 43 patients with CA, after a median follow-up of 29.4 months, recurrence occurred in three cases after CO₂ laser vaporization, but invasive SCC also occurred in two cases [295]. An uncontrolled prospective study of twelve patients evaluated the use of an Er:YAG laser in the treatment of CA. The mean healing time to re-epithelialization was 22.33 days, and the mean follow-up time of 23.16 months showed no recurrence [296].

6.4.2.2 Non-ablative laser procedures

6.6	Consensus-based statement	new 2022
EC	Insufficient data currently does not allow recommendations for the therapy of cheilitis actinica with non-ablative laser procedures.	
	Strong consensus	

There are no relevant studies or case reports in the literature on the use of non-ablative laser procedures in CA.

6.4.3 Cryosurgery

6.7	Consensus-based statement	new 2022
EC	The data available on cryosurgery do not allow a conclusive recommendation for the therapy of cheilitis actinica.	
	Strong consensus	

Only one systematic review mentions an uncontrolled experimental study describing the combined use of imiquimod and cryosurgery for CA [289]. In addition, there are numerous uncontrolled studies from the past century that favor the use of cryosurgery. These include a paper by Lubritz and Smolewski, who treated 53 CA lesions on the lower lip in 37 patients using cryosurgery and observed only one recurrence and one SCC after a follow-up period of at least one year (healing rate of 96.2%) [291]. However, a review of treatment options for CA also found reference to the lack of standardization of cryosurgical treatment, the lack of histological control, and potential side effects such as postoperative edema, pain during and after treatment, scarring, permanent pigmentation changes and local neuropathies [292].

6.4.4 Chemoexfoliation

6.8	Consensus-based recommendation	new 2022
EC	Chemical peeling shall not be used for cheilitis actinica because of a lack of evidence of benefit.	
	Strong consensus	

The systematic review by Salgueiro et al. [289] cites the original work by Robinson from 1989 [286] in which of four comparison groups of ten patients each, one group was treated with trichloroacetic acid 50%. In this one, recurrence occurred in seven cases after a median follow-up time of 49 months. The first recurrence occurred after a median time of nine months [286]. The systematic review by Shah et al. also cited this work, criticized the lack of further controlled studies and therefore did not recommend chemical peeling as a treatment procedure for CA [292].

6.5 Topical drug-based procedures

Drug procedures include classic topical drug applications of pharmaceuticals as well as PDT as a combination of a drug procedure with a procedural approach. These include the pharmaceuticals diclofenac sodium 3% gel, 5-fluorouracil 5% cream, imiquimod 5% cream and 3.75% cream, IMB 0.015% gel (although this not discussed because it is no longer approved in the EMA zone) and for PDT ALA as a 20% preparation or as a patch and MAL 16% as a cream.

6.5.1 Diclofenac

6.9	Evidence-based recommendation	new 2022
GoR 0	Treatment with diclofenac sodium 3% gel may be offered for cheilitis actinica.	
LoE 2	[287] , [288] , [289] , [291] , [297] , [298] , [299]	
	Strong consensus	

In the three systematic reviews cited [\[287\]](#), [\[288\]](#), [\[289\]](#) the three prospective studies [\[297\]](#), [\[298\]](#), [\[299\]](#) on the use of diclofenac sodium 3% gel were listed. In the summary review by Lai et al., a complete clinical response was described in 45.2% of cases (28 of 62), with a complete histopathological response observed in 4 of 6 cases studied. Clinical recurrences occurred in 6.5% of cases (3 of 46) and cosmetic outcome was judged to be excellent in 6 of 6 cases. Treatment discontinuation due to adverse events occurred in 15.2% of cases [\[287\]](#).

In the prospective, uncontrolled study of 31 patients with a clinical diagnosis of CA, diclofenac sodium 3% gel was applied three times daily for 90 days. 19 patients completed the study and were included in the analysis. Ten cases experienced complete remission, three patients experienced partial remission, one patient showed worsening of symptoms and four patients discontinued treatment due to side effects. Follow-up was six months, during which time there were no clinical signs of relapse or disease progression. There was no association between remission, side effects and severity of CA, although an unreviewed score was used to assess severity [\[297\]](#).

In another randomized trial of 30 patients with CA, treatment was given in three groups with either imiquimod 5% cream once daily three days a week for four weeks or a single treatment with 150 µg/g IMB gel for three consecutive days or diclofenac sodium 3% gel twice daily for six weeks [\[298\]](#). Complete remission occurred in five of the ten patients (50%) for imiquimod, four of ten patients (40%) for IMB, and two of ten patients (20%) for diclofenac sodium. Despite the low response rate, the authors considered diclofenac sodium 3% gel suitable for therapy in certain cases (exfoliative areas and erosions and atrophic areas), also in view of the low inflammatory response and in patients with low pain threshold [\[298\]](#).

In the prospective uncontrolled study of 34 patients with CA, Lima et al. investigated the effect of diclofenac sodium 3% gel over the period of 30-180 days twice daily [\[299\]](#). Of the 27 patients who completed the study, 12 (44%) showed complete remission clinically and 15 (56%) had partial remission. Due to the good tolerability, few side effects and good aesthetic results, the authors considered the treatment promising [\[299\]](#).

6.5.2 5-fluorouracil

6.10	Consensus-based statement	new 2022
EC	Insufficient data currently does not allow an evidence-based recommendation for topical therapy of cheilitis actinica with 5-fluorouracil.	
	Strong consensus	

Two systematic reviews described the use of 5-fluorouracil 5% for the treatment of CA [287], [289]. Both papers also mentioned Robinson's prospective comparative study in which a five percent 5-fluorouracil solution was applied to the lower lip of affected patients three times daily for 14 days in one treatment arm [286]. After a median follow-up of 50 months, clinical recurrence was seen in five cases (50%), with a median of twelve months. In the review by Lai et al., 5-fluorouracil 5% resulted in clinical healing in 68.2% (total of 22 patients), but no histological healing (6 cases studied). In 10% of cases, therapy was discontinued due to side effects [287].

6.5.3 Imiquimod

6.11	Consensus-based statement	2022
EC	Insufficient data does currently not allow recommendations for the therapy of cheilitis actinica with imiquimod 5% or 3.75% cream.	
	Strong consensus	

A systematic review described the use of imiquimod 5% for the treatment of CA [287]. Thirty patients received imiquimod 5% for varying periods of time. A complete clinical response was reported in 73.3% of cases (22 of 30), but complete histological healing occurred in only 2 of the 5 cases studied [287]. In the only retrospective study of 15 patients with histologically confirmed CA that could be evaluated for this purpose, topical treatment with imiquimod 5% was given 3 times weekly for 4 to 6 weeks [300]. Patients with a history of labial herpes were treated prophylactically with valaciclovir 1g/daily during imiquimod application. In all 15 patients, CA healed 4 weeks after completion of imiquimod treatment. Nine of the patients were followed up for at least another 3 months and showed no recurrence. 60% of patients experienced moderate to more severe local side effects such as erythema, induration, erosions, or ulceration, some of which persisted throughout the duration of therapy [300]. For 3.75% imiquimod, only one collective case report exists with 11 patients, including only one patient with CA who reported improvement [301]. With the currently (as of 08/2021) available preparations, contact with the lips should be avoided.

6.5.4 Photodynamic therapy

6.12	Evidence-based recommendation	new 2022
GoR B	Photodynamic therapy with red light illumination and 5-aminolevulinic acid (ALA) or its methyl ester (MAL) should be offered for therapy of cheilitis actinica.	
LoE 1	[287] , [288] , [289] , [291] , [302] , [303] , [304] , [305] , [306] , [307] , [308] , [309]	
	Strong consensus	

6.13	Evidence-based recommendation	new 2022
GoR B	Methyl aminolevulinate (MAL) in combination with natural or simulated daylight (MAL-dIPDT) should be offered for therapy of cheilitis actinica.	
LoE 3	[309] , [310] , [311]	
	Strong consensus	

There are numerous well-documented studies and systematic reviews on the use of PDT in CA. A systematic review from 2015 compared the two sensitizers ALA and MAL [\[309\]](#). The median histological cure rate, if examined, was 47.4% (observation time between 1.5-18 months) for the studies with more than 10 patients. The median complete remission rate was reported to be 58% for 5-ALA and 62.5% for MAL [\[309\]](#). After a single 5-ALA application (20% cream) followed by illumination with incoherent red light (40 J/cm²), Sotiriou et al. achieved a complete remission of 80% in 10 patients in a prospective, uncontrolled study, considering histological confirmation of the clinical outcome [\[302\]](#). In another prospective, uncontrolled study of 40 patients with histologically confirmed CA by the same group, 26 patients showed a complete clinical response after 5-ALA-PDT twice. After six months, three patients had clinical and histological recurrence, and after another six months, one patient had recurrence. After 18 months, the overall clinical recurrence rate was 15.38%, and the histological recurrence rate was 34.61% [\[303\]](#). Histological outcome was considered excellent in more than 80% of cases.

In a prospective, uncontrolled study of 15 patients with histologically confirmed CA, Berking and coworkers achieved complete clinical healing in 47% (7/15) and partial healing also in 47% (7/15) of patients after two sessions of MAL-PDT at the time of follow-up at three months [\[304\]](#). However, histopathological workup found residual disease in 62% (8/13). Five patients (38%) showed histological healing, and no recurrence occurred in further follow-up to 22 months of three completely healed patients [\[304\]](#). In another prospective, uncontrolled study of 23 patients, MAL-PDT

was also carried out twice, two weeks apart [305]. Three months after treatment, 16 patients could be evaluated. These showed a complete clinical response in 62.5%, and 37.5% still had clinical signs of CA. However, all patients still showed histopathological changes consistent with CA [305]. In another prospective, uncontrolled study of 19 patients, MAL-PDT was performed only once. After 60 days, patient satisfaction was determined and a biopsy was performed [306]. In 84% of the cases, dysplastic changes could still be detected histologically. A correlation between the final satisfaction of the patients, the subjective impression of clinical improvement and the degree of determined dysplasia was not shown [306].

In a retrospective analysis of eleven cases with CA, conventional PDT with a 5-ALA-containing patch was studied [307]. After four hours of incubation, patients received illumination with narrow-spectrum red light (37 J/cm²). A complete clinical response at three months was observed in eight of eleven patients (72.7%), with recurrences in two lesions at twelve months. Thus, complete clinical healing one year after patch PDT was 66.6% (10/15 lesions). The cosmetic outcome was judged to be excellent in all cases [307]. In another prospective, uncontrolled study by the same research group in 21 patients with the same treatment protocol, 19 patients completed the study [308]. Three months after PDT, 17 patients (89.5%) had complete remission. Complete clinical cure one year after single 5-ALA patch PDT was 84.2% [308].

There are also two well-documented, prospective clinical trials for daylight PDT [310], [311]. In the study by Levi et al., 11 patients were treated repeatedly (every 2-4 weeks) with daylight PDT after prior application of MAL. The mean number of treatments was 2.7, and the mean follow-up time was 30 months (6-60 months). The healing rate achieved was 91% (10/11). Patients reported only mild erythema and little to no pain during treatment [310]. Another prospective study using MAL daylight PDT included 22 patients with histologically confirmed CA [311]. 20 patients completed the study. After three months, 18 of 20 patients (90%) achieved complete remission. Twelve months after daylight PDT, complete clinical remission was 80% (16/20). Mild CA, histologically designated as grade I, seemed to heal better (100%) than more pronounced lesions (grade II, 50%) [311].

6.6 Combination therapies

Combination procedures found via the search strategy included a study in which CA was first pretreated with ablative fractional Er:YAG laser followed by PDT with MAL [312]. In a randomized trial of 33 patients with histologically confirmed CA, one half received pretreatment with Er:YAG laser followed immediately by a single session of red light PDT with MAL (3-h incubation, illumination with LED system, 37 J/cm²). The other half received two cycles of MAL-PDT without prior laser treatment, 7 days apart. Evaluation of clinical and histopathological outcome took place 3 and 12 months after therapy. At 3 months, the population pretreated with laser showed significantly more effective healing (92% complete response) than the group treated twice with MAL-PDT alone (59%, p=0.040). At 12 months, the healing rate for laser-assisted PDT remained at 85%, while it decreased to 29% for conventional PDT [312]. The authors stated a significant advantage of pretreatment using ablative fractional Er:YAG laser over conventional MAL-PDT for CA.

In another prospective, uncontrolled study, Sotiriou et al. combined two conventional MAL-PDT sessions in 43 patients with histologically confirmed CA with subsequent application of 5% imiquimod cream 3 times weekly for 4 weeks [313]. After 3 months, 30 patients were evaluated and a complete clinical response was observed in 27

patients. At 12 months, the clinical healing rate was 80% and histological healing was 73%. Treatment was well tolerated and side effects were as expected and temporary [313].

In summary, the presented combination forms show good potential for increasing effectiveness; however, the data are currently still too minimal to make a therapy recommendation.

6.7 Summary and balancing presentation of approved therapy options (balance sheet)

Table 34: Balance sheet interventions for cheilitis actinica

Intervention	TA	Mechanism of action & application	Efficacy ¹	Side effects and tolerability ²	Cosmesis ³	Duration of the treatment ⁴	Direct treatment costs per cycle ⁵	Practicability ⁶		Strength of recommendations and evidence base ⁷
								Physician	Patient	
Ablative procedures										
Cryosurgery	L	One to two freeze-thaw cycles with liquid nitrogen (-196°C) Cold exposure of the target lesions for 15-60 seconds ("whitening") Open spray method Contact method (cryo stamp, cryo probe)	++/+++ (No data available from RCT) ⁸	++	+	∞	€	++++	+++	~ EC
Surgical procedures with histological assessment ⁹	F	Complete excision, vermilionectomy, lip shave	++++ (No data available from RCT) ⁸	++	++	∞	€-€€	+++	++	↑↑ 1-3
Surgical procedures without histological assessment ⁹	F	Electrodesiccation, dermabrasion	+ (No data available from RCT) ⁸	+	+ / ++	∞	€-€€	+ / ++	+	~ EC
Chemoexfoliation	F	Ablation of superficial skin layers using chemical agents (e.g. 50% trichloroacetic acid)	+ Clearance rate: 30%	+ / ++	++	∞	€-€€	++	++	~ 1-4
Laser treatment ⁶	F	Ablative laser treatment (e.g. CO ₂ -, erbium YAG laser)	+++ Clearance rate: 93.4%	++	++ / +++	∞	€€€	+++	++	↔ 2-3
		Non-ablative laser treatments ⁶ (e.g. Nd:YAG laser, fractional 1540 nm laser)	+ (No data available from RCT) ⁸	++	++	∞	€€€	+++	+++	~ EC

Intervention	TA	Mechanism of action & application	Efficacy ¹	Side effects and tolerability ²	Cosmesis ³	Duration of the treatment ⁴	Direct treatment costs per cycle ⁵	Practicability ⁶		Strength of recommendations and evidence base ⁷
								Physician	Patient	
		Conditions: >10°C outdoor temperature, cloudless to overcast sky, no rain								
<p>¹ Semiquantitative assessment taking into account lesion- and patient-related response rates (+ = little effective, ++ = moderately effective, +++ = effective, ++++ = very effective)</p> <p>² Semiquantitative assessment taking into account frequency and severity of treatment-mediated side effects (+ = poorly tolerated/many side effects, ++ = moderately tolerated, +++ = well tolerated, ++++ = very well tolerated)</p> <p>³ Semiquantitative assessment considering investigator- and patient-assessed outcomes such as dyspigmentation, improvement of hyperkeratosis, global assessment (+ = predominantly poor, ++ = predominantly moderate, +++ = predominantly good, ++++ = predominantly excellent).</p> <p>⁴ ☺ = short (<1 week), ☺☺ = medium (1-6 weeks), ☺☺☺ = long (>6 weeks)</p> <p>⁵ € = <100 Euro, €€ = 100-500 Euro, €€€ = >500 Euro; only direct treatment costs per cycle performed were considered; public pharmacy dispensing prices in Germany (as of August 2021) were used as the basis for topical drug procedures; procedural procedures were based on the valuations of the Gebührenordnung für Ärzte (GOÄ, as of August 2021)</p> <p>⁶ Taking into account expert opinions</p> <p>⁷ Strengths of recommendation: May = ⇔, Should = ↑, Shall = ↑↑; ~ no recommendation if data / evidence base is unclear; indication of evidence levels according to Oxford 2011</p> <p>⁸ When applying the mentioned search strategy and inclusion and exclusion criteria</p> <p>Abbreviations: L=lesion-directed, F=field-directed, AK = actinic keratosis(s), EC = expert consensus, RCT = randomised controlled trial, TA = therapeutic approach.</p>										

7 Therapy of squamous cell carcinoma in situ (Bowen's disease)

L. Schmitz, M. Flaig, M. Heppt

7.1 Literature search and study selection

Only prospective randomized controlled trials (RCTs) or systematic reviews and meta-analyses of RCTs that reported at least one of the predefined critical effectiveness endpoints were included as the basis for the evidence-based recommendations and statements. These included:

- Response rate = "lesion clearance rate" (defined as clearance of all treated lesions),
- Patient-related response rate = "participant clearance rate" (defined as healing of all treated lesions per patient),
- Recurrence rate = "lesion recurrence rate" (defined as recurred lesions after successful treatment),
- Patient-related recurrence rate = "participant recurrence rate" (defined as recurred lesions after successful treatment per patient).

Optional effectiveness endpoints such as lesional area reduction, local adverse events, pain assessment using a VAS in PDT studies, cosmetic outcome and patient satisfaction were considered in the survey.

Prospective and retrospective observational studies, nonrandomized studies, case series and/or case reports were not included. The minimum study population was n=10 regardless of study design (interindividual, intraindividual, cross-over design).

The literature search is described in the Methods Report of the guideline. In the following, the included interventions were ordered and qualitatively compared.

7.2 Clinical characterization and natural course of the disease

Bowen's disease was first described in 1912 by John Templeton Bowen [\[314\]](#) and refers to in situ SCC of the skin. Clinically, Bowen's disease usually presents as a well-demarcated, non-pigmented, erythematous, sometimes scaly or hyperkeratotic plaque. The lesions show slow growth and are usually asymptomatic. For larger lesions, pruritus has been described as a possible symptom. The size of the lesions varies and correlates with the duration of the population. It ranges from a few millimeters to a few centimeters in horizontal diameter. In most cases, the lesions are single; in 10-20%, multiple lesions are found in one patient. Data regarding possible progression to invasive growth is poor and largely based on older studies [\[315\]](#), [\[316\]](#).

7.3 Treatment indication and therapy modalities

7.1	Consensus-based recommendation	new 2022
EC	<p>Prior to treatment of Bowen's disease, a biopsy shall be obtained to exclude invasive squamous cell carcinoma, other neoplasia, or inflammatory conditions.</p> <p>If there is clinical evidence of a lack of response or incomplete response to therapy, histological control shall be carried out.</p>	
	Strong consensus	

Background

Due to the slow growth, good clinical demarcation of the lesions to healthy skin as well as mostly low numbers on lesions of a patient, there are good conditions for the therapy of Bowen's disease. Since the transition to invasive growth is possible in principle, therapy of Bowen's disease should be pursued. However, there are few studies addressing exact progression numbers and a characterization of which lesions are at increased risk. Therefore, risk stratification is not possible.

Unlike for therapy of AK, Bowen's disease is often surrounded by healthy skin, so that almost without exception lesion-directed therapies are used. Various factors must be considered for the indication, just as in the therapy of AK:

- Patient-related: age, desire for therapy, comorbidities, individual risk (immunosuppression, organ transplantation), adherence/compliance, social environment, and resources
- Lesion-related: number of lesions, size of each lesion, location (capillitium, face, trunk, extremities, genitoanal)
- Therapy-related: therapy modality (interventional, surgical, topical-drug), therapy duration, efficacy, side effects and tolerability, self- or third-party application, therapy costs, cosmetics
- Treatment-related: experience, technical and instrumental requirements

Surgical, interventional as well as topical-medicinal options are available for the therapy of Bowen's disease. A direct comparison regarding efficacy or recurrence rates of the respective interventions is mostly not possible in the absence of "head-to-head" studies. In addition, the poor comparability of studies is based on factors such as the inclusion of lesions of different localization and size, different study endpoints (healing determined clinically or histologically), different timing of follow-up examination and follow-up period, different treatment protocols (including in the context of PDT), the combination of different therapeutic modalities.

The following therapeutic options are described in the literature:

- Surgical procedures
- Excision (curettage, shallow ablation ["Shave"], complete excision) +/- micrographically controlled
- Destructive procedures
- Cryosurgery
- Electrocautery, electrodesiccation

- Ablative laser procedures
- Interventional procedures
- Photodynamic therapy in a conventional way (+/- pretreatment to improve the penetration of the photosensitizer by e.g. "micro-needling" or laser-assisted)
- Topical drug-based therapies
- 5-fluorouracil
- Imiquimod
- Radiotherapy

The literature search conducted in accordance with that described in 7.1 above yielded a total of 12 studies that met the criteria. These studies exclusively investigate drug-related therapy modalities and report surgical or other procedures such as cryosurgery if exclusively as a control group. In clinical practice, surgery or ablative laser therapy represent a majority of the therapies. However, there are no data based on randomized controlled trials for these in the literature. Therefore, consensus-based recommendations have been established at this point. A consensus-based approach was developed to classify the procedures, which do not have good comparability despite available study data, and to consider them in context with surgical and destructive procedures. This follows the discussion of the therapies.

7.4 Surgical procedures

7.2	Consensus-based recommendation	new 2022
EC	Surgical excision of Bowen's disease (e.g., by shave excision or complete excision) shall be offered for single lesions.	
	Strong consensus	

Background

Surgical excision of Bowen's disease is a commonly performed treatment option in clinical practice, but evidence from RCTs is lacking. Our literature search did not identify any randomized, adequately controlled trials that investigated surgical procedures, so an intervention-based presentation is not possible. Other systematic reviews or meta-analyses with different search strategies and databases examined also did not identify RCTs on surgical procedures. This is in contrast to the long-standing use and broad clinical experience of surgical excision. Due to clinically well delineated, mostly single lesions, different procedures such as shallow ablation ("shave excision") or complete excision are suitable, the use of which depends on the clinical context and can be considered equivalent. The major advantage of surgical procedures is the possibility of subsequent histological examination, especially to exclude invasive SCC in case of an unclear clinical picture.

Some case series reported lower recurrence rates when combined with electrocautery. Experience has shown that side effect rates are low with superficial ablation and healing rates are close to 100%. The technique in which surgical removal should be done depends on anatomical location, clinical picture and the individual expertise of the practitioner. If removal is too superficial, histological examination is limited.

Therefore, complete excision should be considered in high-risk patients or for lesions with potentially invasive growth. Disadvantages of surgical procedures include the need for local anesthesia and general surgical risks such as bleeding, scarring and wound healing problems.

Few studies are available on surgical therapy of Bowen's disease followed by micrographic control. However, these do not meet the listed literature search criteria. A retrospective study with an observation period of 10 years investigated micrographic-controlled excision (after Moh) in 270 patients [317]. The listed reasons for choosing the procedure were poorly demarcated tumor margins, recurrent or subtotally excised lesions, or localization of Bowen's disease. This gives a good indication for the use of this adjunctive procedure; therapy of Bowen's disease by micrographic-controlled surgery should be reserved for special localizations (e.g., finger end phalanx, mouth, or near the eye) in which a clinical safety margin cannot be guaranteed or in recurrent situations that cannot be clinically delineated.

Other surgical destructive procedures such as curettage, electrocautery, and electrodesiccation are available for rapid and simple ablation of lesions. However, the intensity and depth of ablation in these procedures is not standardized. This complicates a definitive histopathologic diagnosis, especially the differentiation of Bowen's disease from invasive SCC of the skin and Bowen's carcinoma. This problem also exists for shallow ablation if it is carried out too superficially. In addition, in curetted specimens, excision margins are poorly assessable due to fragmentation. Here, the flat excision offers advantages. Curettage, electrocautery and electrodesiccation are important for edematous legs with a high risk of postoperative wound healing disorders or elderly patients with limited adherence to therapy or limited ability to apply topical agents.

7.5 Destructive methods

7.5.1 Cryosurgery

7.3	Consensus-based recommendation	new 2022
EC	Cryosurgery may be offered for the treatment of Bowen's disease.	
	Consensus	

Background

The use of cryosurgery in the treatment of Bowen's disease is predominantly based on clinical experience. Our literature search identified two individual studies that investigated cryosurgery in a treatment arm [249], [318]. Cryosurgery was investigated as a traditional, established, and widely used therapeutic modality in a comparison group to ALA or MAL-PDT. Studies comparing cryosurgery versus placebo as the primary study objective were not found. A systematic review also considered the above studies [319]. No RCT was found that investigated cryosurgery in immunosuppressed individuals.

Cryosurgery vs. MAL-red light PDT vs. placebo vs. 5-fluorouracil 5% cream

Population and study design: In 225 patients (87 men, 138 women aged 39-99), MAL-PDT was compared with placebo-PDT or with standard therapy (cryosurgery or 5-fluorouracil 5% cream) in a randomized, double-blind, placebo-controlled multicenter study [249]. Bowen's disease had to be previously histologically confirmed and with a lesion size of 6-40 mm. Randomization was into 4 groups: MAL-PDT (n=96 [124 lesions, of which 29 were localized to the head, 15 to the neck or trunk, and 80 to the extremities], mean age of 71.9 years [43-89], 36 men, 60 women), placebo-PDT (n=17 [24 lesions, of which 6 were localized to the head, 2 to the neck or trunk, and 16 to the extremities], mean age of 73.4 years [53-88], 6 men, 11 women), cryosurgery (n=82 [91 lesions, of which 26 were localized to the head, 13 to the neck or trunk and 52 to the extremities], mean age of 74 years [45-99], 34 men, 48 women) and 5-fluorouracil 5% (n=30 [36 lesions, of which 7 were localized to the head, 4 to the neck or trunk and 25 to the extremities], mean age of 72.5 years [39-86], 11 men, 19 women).

Intervention: Following superficial curettage of the lesions, MAL or placebo cream was applied 3 hours before exposure to a broadband red light source (570-670 nm, 75 J/cm²). One week after the first treatment, another PDT cycle was carried out. Cryosurgery was carried out with an open spray method as part of a spray/thaw cycle. Icing was carried out with a 2-mm margin beyond the lesion for at least 20 seconds. Cryosurgery was carried out only once. 5-Fluorouracil 5% cream was applied daily for the first week of treatment and twice daily for the following 3 weeks. Follow-up was carried out 12 weeks after therapy in all treatment groups. Lesions with a partial response (defined as reduction in lesion size \geq 25% and $<$ 100%) at this time point were treated again.

Results: Complete healing of lesions was seen in 93% (103/111) in the MAL-PDT group vs. 21% (4/19) in the placebo-PDT group vs. 86% (73/85) in the cryosurgery group vs. 83% (24/29) in the 5-FU group 3 months after the end of therapy. The lesion-related recurrence rate at 12 months was 15% (15/103) in the MAL-PDT group vs. 50% (2/4) in the placebo-PDT group vs. 21% (15/73) in the cryosurgery-PDT group vs. 17% (4/24) in the 5-FU group. A good or excellent cosmetic outcome at 3 or 12 months was observed in 94% for MAL-PDT, in 66% for cryosurgery, and in 76% for 5-FU. The frequency of the most commonly described adverse events can be seen in the table:

Table 35: Adverse events of the comparison cryosurgery vs. MAL red light PDT vs. placebo vs. 5-fluorouracil 5% cream for the treatment of Bowen's disease

Adverse event*	MAL-PDT	Cryosurgery	5-FU 5% cream	Placebo
Pain	20%	24%	33%	24%
Erythema	8%	10%	33%	13%
Burning sensation	17%	7%	7%	18%
Crustings	8%	4%	13%	6%
Stinging sensation	9%	1%	7%	6%
*after [249]				

Assessment: In this study, patient- and lesion-related group characteristics were comparable at baseline. However, the risks for possible detection/performance and selection bias cannot be assessed with certainty.

Comparing the treatment modalities, MAL-PDT emerged as the most effective procedure in terms of complete healing of lesions (93%), with the lowest lesion-related recurrence rate (15%) at 12 months [249]. Thus, a significantly higher healing rate occurred under MAL-PDT compared with cryosurgery (relative risk 1.17; 95% CI 1.01-1.37) [319], [319]; the differences in recurrence rates between the two procedures were not significantly different at 12 months (relative risk 0.71; 95% CI 0.37-1.36) [319]. The two comparators cryosurgery and 5-FU show comparable results, which should be negligible in practical application. In addition to the efficacy, the different profiles of adverse events as well as the cosmetic outcome are of particular importance; this latter was rated worst for cryosurgery with 66% in comparison.

Cryosurgery vs. ALA Red Light PDT

Population and study design: This randomized, 2-arm comparative study evaluated the treatment of 19 patients (3 men and 16 women) with a total of 40 lesions of Bowen's disease by ALA-PDT or cryosurgery at one study site [318]. The mean age of the patients was 76 [62-88] years. The 40 lesions were randomized 1:1 (n=20) into the two therapy arms with comparable locations (ALA-PDT group: legs [n=17], face [n=2] and hands [n=1] and cryosurgery group: legs [n=16], face [n=3] and hands [n=1]). Lesions were histologically confirmed by 4-mm punch biopsy before therapy and were therapy-naive. Only lesions with a diameter of ≤ 21 mm were included.

Interventions: ALA-PDT was carried out with a 20% ALA oil-in-water emulsion. For this, approximately 50 mg/cm² was applied to a lesion including a narrow margin of clinically healthy tissue and incubated for 4 hours under film occlusion. This was followed by exposure for 30 minutes at a flux rate of 70 mW/cm², resulting in a total

dose per lesion of approximately 125 J/cm². A 300W xenon lamp was used as the light source, which emitted a broadband spectrum (30nm) in the 630nm range with appropriate filters.

Cryosurgery was carried out using an open spray method as part of a spray/thaw cycle. Icing was performed with a 2-3 mm margin beyond the lesion for at least 20 seconds.

Results: Complete healing of lesions was observed in 75% (15/20) after one session of ALA-PDT and in 100% (5/5) after another PDT session. In the cryosurgery group, complete healing of lesions was seen in 50% (10/20) after the first therapy, 80% (6/10) after the second therapy, and 100% (4/4) after a third cryosurgery. In each case, the differences after one or after a second cycle of therapy were not statistically significant (relative risk 1.50; 95% CI 0.90-2.49 and relative risk 1.24; 95% CI 0.98-1.57, respectively). The lesion-related recurrence rate showed one recurrence in each of the cryosurgery groups at 6 and 8 months, which healed after repeat cryosurgery. The authors reported complete healing at 12 months in 100% for ALA-PDT and in 90% (18/20) for cryosurgery. This is not statistically significant (Fisher's Exact Test: $p=0.49$). Pain was observed during therapy in the ALA-PDT group for 11 lesions (6 mild, 5 moderate) and in 19 lesions (12 mild, 7 moderate) in the cryosurgery group. For the cryosurgery group, in contrast to the ALA-PDT group (no other adverse events), ulcerations were still described in 5 lesions and infections in 2 lesions.

Assessment: In this study, ALA-PDT showed a significantly higher response after fewer cycles of therapy and no recurrences during the 12-month follow-up period compared with cryosurgery. It should be noted that lesions in the ALA-PDT group were significantly larger on average (150mm² [25-441mm²]) than lesions in the cryosurgery group (82mm² [30-360mm²]). The study showed that both therapeutic procedures required more cycles of therapy depending on increasing lesion size. ALA-PDT was also superior to cryosurgery in adverse events and painfulness. Critically, no statement can be made about possible influencing factors due to lack of data.

7.5.2 Ablative laser procedures

7.4	Evidence-based recommendation	new 2022
GoR 0	Ablative laser procedures may be offered to treat Bowen's disease.	
LoE 2	[320] 2: De novo research	
	Consensus	

Background

One randomized trial was identified that compared CO₂ laser ablation with ALA red light PDT combined with CO₂ laser ablation [\[320\]](#).

Population and study design: The present randomized, controlled, double-blinded study examined the efficacy of ALA red light PDT after CO₂ laser therapy (PDT+ laser) and CO₂ laser ablation (laser) alone for Bowen's disease in an interindividual comparison at a study site [\[320\]](#). 22 lesions in 18 patients (8 men and 10 women) with a mean age of 52 (35 - 72) years were randomized 1:1 (n=11 lesions each) into the two therapy groups. Histologically confirmed lesions had a mean diameter of 2.6±0.9 cm.

Interventions: All lesions were treated with 2-3 watts of power using a CO₂ laser under local anesthesia. The level of tissue vaporization was chosen at the level of the stratum papillare in hairless skin and at the level of the mid stratum reticulare in haired skin. The vaporized tissue was removed with a tissue. In the laser group, no further intervention was followed. In the PDT+ laser group, ALA red light PDT was performed immediately afterwards. This was carried out with a 20% ALA emulsion. ALA was applied beyond the lesion with a margin of clinically healthy skin of 0-4 mm and incubated for 5 hours under foil occlusion. Subsequently, exposure was at a flux rate of 100 mW/cm², resulting in a total dose per lesion of approximately 180 J/cm². The light source used was a laser emitting a wavelength of 630nm.

Lesions were evaluated clinically at 1 and 4 weeks after therapy. If healing was not complete, therapy was repeated no later than 4 weeks after the previous therapy. If healing was not achieved after 3 cycles, the lesion was surgically removed. Histological controls of therapy were carried out 1 month and 6 months after the last cycle.

Results: There was better complete lesion healing in the PDT+ laser group with 72.7% (8/11) compared to the laser group with 63.3% (7/11). Overall, more healings (overall clearance) were observed in the PDT+ laser group with 90.9% (10/11) compared to 54.6% (6/11) in the laser group. The recurrence rate at 6 months was significantly better in the PDT+ laser group at 9% (1/11) compared to 45.5% (5/11) in the laser group. Patient satisfaction was higher in the PDT+ laser group at 80% (8/10) compared with 62.5% [5/8] in the laser group. Adverse events reported for the PDT+ laser group were redness, swelling, and stinging and burning sensations. In the laser

group, in addition to mild to moderate swelling and erosion, delayed healing occurred in 2 patients, prolonged pain in 2 patients, ulceration in 3 patients and scarring in 2 patients.

Evaluation: A combination of CO₂ laser ablation followed by ALA-PDT with red light is superior to CO₂ laser ablation alone in both healing rate and recurrence frequency. However, this is a small study population, so the results should be evaluated with caution. The extent to which this combination is actually useful after the entire epidermis has been vaporized with the laser is questionable for several reasons. Among others, with laser ablation at the described penetration depth, Bowen's disease should already have been removed and no vital keratinocytes needed for PDT should still be present. Therefore, laser ablation alone is suitable as an optional procedure.

7.6 Topical drug-based procedures

7.6.1 5-fluorouracil

7.5	Evidence-based recommendation	new 2022
GoR B	5-Fluorouracil 5% cream should be offered for the treatment of Bowen's disease.	
LoE 2	[249], [319], [321], [322] 2: De novo research	
	Consensus	

Background

5-Fluorouracil (5-FU) is a cytostatic drug. The pharmacologically active component of 5-FU, 5-fluorodeoxyuridine monophosphate, is an antimetabolite that prevents the methylation of deoxyuridine monophosphate to deoxythymidine monophosphate by inhibiting thymidylate synthase. This leads to thymidine deficiency, which impairs DNA synthesis and RNA transcription. Although this affects proliferatively active cells more than normal keratinocytes, the mechanism of action of 5-FU is thus non-specific. It is metabolized predominantly by the enzyme dihydropyrimidine dehydrogenase (DPD). Patients with reduced activity of this enzyme may experience decreased degradation with the risk of severe local or even systemic side effects. In addition, DPD activity is impaired by viral nucleoside analogues such as brivudine. Severe side effects have also been observed with concomitant, systemic administration of methotrexate. In Germany, 5-FU is approved as a 5% cream for the treatment of Bowen's disease. It is applied twice daily for a maximum of 4 weeks. After 1-2 weeks, initial treatment effects such as redness or erosion are usually observed. The systematic literature search revealed 3 single studies [321], [322], [249] and 1 systematic review [319] that investigated 5-FU in the concentration 5%.

5-Fluorouracil 5% cream vs. MAL red light PDT vs. cryosurgery vs. placebo

For more detailed information comparing these interventions, see [Chapter 7.5.1](#).

Assessment: There was no significant difference in lesion-related healing comparing 5-FU and MAL-PDT (relative risk 1.16; 95% CI 0.93-1.44) or 5-FU and cryosurgery (relative risk 0.99; 95% CI 0.78-1.26) [249], [319]. There was also no significant difference in recurrence rate at 12 months comparing both 5-FU and MAL-PDT (relative risk 0.59; 95% CI 0.31-1.13) and 5-FU and cryosurgery (relative risk 1.48; 95% CI 0.53-4.17) [319]. In the adverse event comparison, significantly more events were seen in the 5-FU group compared with both the cryosurgery group (relative risk 0.64; 95% CI 0.47-0.86) and the MAL-PDT group (relative risk 0.26; 95% CI 0.08-0.80) [319].

5-fluorouracil 5% cream vs. ALA-red light-PDT

Population and study design: This randomized, 2-arm comparative study evaluated the treatment of 40 patients (8 men and 32 women) with a total of 66 lesions of Bowen's disease by ALA-PDT or 5-fluorouracil cream 5% at one study site [322]. The mean age of the patients was 76 [65-88] years. The 66 lesions were randomly assigned in a 1:1 ratio (n=33) and were localized exclusively to the legs (n=33) in the ALA-PDT group and to the majority of the legs (n=22) and to the arms (n=4) and face (n=4) in the 5-FU group. The lesions were histologically confirmed before therapy, had existed for at least 6 months, and were therapy-naïve. Per patient, 1-3 lesions were treated, ranging in size from 0.5-4.0 cm in diameter.

Interventions: ALA-PDT was carried out with a 20% ALA oil-in-water emulsion. ALA was applied beyond the lesion with a margin of clinically healthy skin of at least 5 mm and incubated for 4 hours under film occlusion. Then, depending on lesion size, exposure was between 12-40 minutes at a flux rate of 50-90 mW/cm², resulting in a total dose per lesion of approximately 100 J/cm². A 300W xenon lamp was used as the light source, which emitted a broadband spectrum (\pm 15nm) in the 630nm range with appropriate filters. The 5-fluorouracil cream 5% was applied thinly to the lesion once daily during the first week of treatment. In weeks 2-4, application was twice per day.

Results: Significantly more (relative risk 1.83; 95% CI 1.10-3.06) lesion-related healings were observed in the ALA-PDT group at 88% (29/33) than in the 5-FU group at 67% (22/33) [319], [322]. The recurrence rate was not significantly different with 2 lesions in the ALA-PDT group and 6 lesions in the 5-FU group (relative risk 0.33; 95% CI 0.07-1.53) [319], [322]. Thus, the authors report a significantly better complete cure rate at 12 months of 82% (27/33) for ALA-PDT compared to 48% (16/33) for 5-FU ($p=0.006$, OR 4.78; 95% CI 1.56-14.62) [322].

Significantly fewer (0/33) adverse events (including eczema reactions and ulcerations) were observed in the ALA-PDT group than in the 5-FU group (12/33) (Fisher's Exact Test: $p < 0.001$) [319], [322]. Compared with ALA-PDT, scarring occurred in 3 reported ulcerations in the 5-FU group. Differences in terms of treatment-related pain were not reported.

Assessment: In immunocompetent patients, ALA-PDT is superior to 5-FU in terms of complete healing after 12 months and side effect profile. Due to the lack of data, no conclusive assessment of possible influencing factors is possible. Women were clearly overrepresented in the study population (32 to 8).

5-Fluorouracil 5% cream vs. MAL red light PDT (immunosuppressed)

Population and study design: In 8 organ transplant recipients (kidney transplant [n=7] and combined liver/kidney transplant [n=1]) with immunosuppression (6 men, 2 women, mean age 59 [46-71] years), the efficacy of 5% 5-FU cream vs MAL red-light PDT was compared intra-individually at one study site as part of an "open-label" study. Transplants had taken place on average 20 (11-30) years ago. A total of 8 AK and 10 lesions of Bowen's disease were treated in the intervention study. The evaluation was done after 1, 3 and 6 months. No other therapy was allowed in these areas for 8 weeks prior to therapy and the diagnosis of the lesions were confirmed histologically. Lesion sizes ranged from 39-5010 mm² [321].

Interventions: For PDT, MAL cream (160mg/g) was applied approximately 1 mm thick and incubated for 3 hours under foil occlusion. Encrusted lesions were carefully curetted beforehand. Subsequently, exposure to red light (633 ± 15 nm) was carried out at a flux rate of 80 mW/cm², resulting in a total dose per lesion of 75 J/cm². The procedure was repeated after 1 week regardless of the findings.

5-FU cream 5% was applied to the lesions twice daily for 3 weeks. Again, crusted lesions were carefully curetted at baseline.

Results: At all 3 observation time points, MAL-PDT showed significantly better complete treatment response with 89% (8/9) compared to 11% (1/9) with 5-FU (p=0.02) [321]. The mean reduction in lesion area was also greater for MAL-PDT compared to 5-FU (100% vs. 79%). The cosmetic outcome was better after MAL-PDT and was rated excellent in 100%. The difference was not statistically significant (Fisher's Exact Test: p=0.08) [321]. Patient preference was also in favor of MAL-PDT. Adverse events reported were crusts, itching and hyperpigmentation for MAL-PDT and superficial erosions, crusts and itching for 5-FU. Pain during therapy was higher with MAL-PDT than with 5-FU use.

Assessment: In immunosuppressed individuals, MAL-PDT is significantly superior to topical 5-FU application in terms of complete healing rate at all observation time points. None of the patients experienced a deterioration of renal function during the study period. Overall, however, the present study population is quite small. Due to the lack of data, it is not possible to make a conclusive assessment of possible influencing factors.

7.6.2 Imiquimod

7.6	Evidence-based recommendation	new 2022
GoR 0	Imiquimod 5% cream may be offered for the treatment of Bowen's disease in immunocompetent patients. In this case, the lack of approval should be noted.	
LoE 2	[319], [323] 2: De novo research	
	Consensus	

Background

The specific toll-like receptor (TLR) 7 agonist imiquimod 5% has been approved since 2006 for the topical treatment of clinically typical, non-hyperkeratotic, non-hypertrophic AK (Olsen grade I to II) on the face or scalp and for the treatment of small superficial basal cell carcinoma in immunocompetent adults. It is available as a cream portioned in individual sachets (12.5 mg), which is the maximum dose per treatment day. Imiquimod 5% cream should be applied to a maximum treatment area of 25 cm² three times weekly for 4 weeks each time for therapy of AK and left on the skin for approximately 8 hours. After a four-week treatment-free period, the healing of the AK should be checked and, if necessary, a second treatment cycle over 4 weeks should follow. In the treatment of superficial basal cell carcinoma, the cream is applied to the corresponding lesion 5 times/week (Mon-Fri) for 6 weeks and left for 8 hours. 12 weeks after the end of therapy, the result should be assessed. In case of therapy failure, no further cycle should be carried out and another therapy procedure should be chosen.

Treatment of Bowen's disease using imiquimod 5% is equivalent to off-label use.

Imiquimod 5% cream vs. placebo

Population and study design: In this randomized, double-blinded study, imiquimod 5% cream vs. placebo was evaluated in the treatment of histologically confirmed Bowen's disease at one center. For this purpose, out of a total of 31 patients (11 men and 20 women), 16 patients (2 men and 14 women) with a mean age of 74 (60-86) years were randomized to the placebo group and 15 patients (9 men and 6 women) with a mean age of 74 (54-83) years were randomized to the imiquimod 5% group. In the placebo group, the mean lesion size was 248 (84-555) mm² and in the imiquimod 5% group it was 429 (23-1776) mm² [323].

Interventions: Both imiquimod 5% cream and placebo cream were applied to the lesions by patients 1x daily for 16 weeks. Patients were allowed to discontinue therapy a maximum of twice during the study for a maximum of 5 consecutive days if the inflammatory response was subjectively too severe. Evaluation was done at week 28 (12 weeks after end of therapy).

Results: In the imiquimod 5% group, 75% of patients (9/15) showed complete healing of lesions compared to 0% in the placebo group (Fisher's Exact Test: p < 0.001). The

mean decrease in lesion size between week 0 and week 28 was statistically significantly greater ($p=.041$) in the imiquimod 5% group at -322 mm^2 ($\pm 519 \text{ mm}^2$) than in the placebo group at -37 mm^2 ($\pm 114 \text{ mm}^2$). It should be mentioned that a total of 3 patients (all in the imiquimod 5% group) did not complete the study. No recurrences were reported in a follow-up at 9 months. In the imiquimod 5% group, almost all patients showed a localized inflammatory reaction. Overall, 19 of the 31 patients had transient itching, swelling, as well as oozing of the lesion.

Assessment: Due to the small number of patients, a reliable statement on the efficacy of imiquimod 5% for the treatment of Bowen's disease is difficult, especially in comparison to other therapies. Imiquimod 5% was superior to placebo. However, it must be noted that the application regimen (1x daily for 16 weeks) in this study did not correspond to any approved application (neither for AK nor for superficial basal cell carcinoma). The application duration was longer and more frequent. In addition, the characteristics of the two study groups at baseline were significantly different, particularly with regard to lesion sizes.

7.7 Photodynamic therapy

7.7	Evidence-based recommendation	new 2022
GoR B	Photodynamic therapy with red light illumination should be offered for the treatment of Bowen's disease in two therapy cycles within 4 weeks.	
LoE 1	[324], [325], [326], [327], [328], [249], [318], [319], [321], [322], [320], [137]	
	1: De novo research	
	Strong consensus	

7.8	Evidence-based recommendation	new 2022
GoR 0	Pretreatment (e.g., ablative fractional laser procedures, microneedling) may be offered before photodynamic therapy with red light illumination to enhance penetration.	
LoE 2	[324], [325], [326], [178], [320]	
	2: De novo research	
	Strong consensus	

Background

The principle of PDT is based on the application of light-sensitizing substances. These photosensitizers selectively accumulate in atypical keratinocytes in the diseased epidermis and are activated by illumination with light of suitable

wavelength. In this process, photochemical and photophysical processes generate reactive oxygen species that lead to cell damage and cell death of precancerous changes. In the therapy of Bowen's disease, the external application of ALA or its methyl ester MAL has become established. ALA is a precursor (prodrug) of endogenous heme synthesis, which is converted in the skin to the actually effective photoactive porphyrins such as protoporphyrin IX.

7.7.1 ALA-PDT

Classic formulations of ALA in creams, gels, solutions or ointments are not very stable and are rapidly degraded in the skin microenvironment. In addition, ALA is somewhat more hydrophilic than MAL and therefore has relatively poorer penetration properties, especially in thicker, hyperkeratotic lesions. In Germany, conventional ALA mixtures are available only as individual prescriptions or extemporaneous preparations (R007). The nanoemulsion approved since 2012 for the therapy of AK, which corresponds to a 10% ALA preparation (BF-200 ALA), has no explicit approval for the therapy of Bowen's disease.

The studies identified in the literature search [318], [322], [322], [320], [327], [322], [328] investigating ALA-PDT for the treatment of Bowen's disease include small collectives (median lesion number treated with ALA-cPDT: $n=33$ [11-61]). In particular, the studies are heterogeneous in terms of treatment protocols (timing and frequency of PDT cycles), light sources used, ALA formulations, and endpoints reported. Therefore, comparison of results is not possible. The range of complete lesion healings achieved also varies widely, with results ranging from 40% to 94% [327], [328]. In principle, with regard to the analyzed studies on MAL-PDT, it would be reasonable to follow the established procedure of 2 therapy cycles at an interval of 1 week with an incubation period of 3 hours and exposure to a narrow spectrum red light.

ALA-PDT with red light vs. green light

Population and study design: The randomized comparative study by Morton et al. evaluated the efficacy of ALA-PDT with red (rPDT) versus green (gPDT) light in 16 patients with a mean age of 73 (50-87) years and a total of 61 histologically confirmed lesions at one study site [327]. Patients had a median of 3 (1-6) lesions, all of which were localized to the legs. 29 lesions with a median treatment area of 125 (16-441) mm² were randomized to the gPDT group and 32 lesions with a median treatment area of 100 (25-400) mm² to the rPDT group. Lesions were all treatment-naïve and had a diameter of ≤ 21 mm.

Interventions: ALA-PDT was carried out with a 20% ALA oil in water emulsion. Prior to this, crusts were gently curetted. Approximately 50 mg/cm² ALA was applied beyond the lesion with a margin of clinically healthy skin of at least 4 mm and incubated for 4 hours under film occlusion. This was followed by exposure to either green (gPDT group) or red (rPDT group) light. A 300W xenon lamp was used as the light source, emitting an adapted spectrum of 540±15 nm (green) or, with appropriate filters, a spectrum of 630 nm±15 nm (red). With a flux rate of 86 mW/cm², lesions in the rPDT arm received a total dose of 125 J/cm² and lesions in the gPDT arm received a total dose of 62.5 J/cm². The different total dose was chosen under the notion that approximately twice as much protoporphyrin IX is formed with green light exposure (540 nm) as with red light exposure (630 nm). Clinical follow-up was carried out 2 months after therapy. If healing was not complete, the therapy was repeated once.

Subsequently, monthly clinical controls were carried out for 12 months. In case of clinical doubt, a biopsy was taken for histological examination.

Results: The lesion-related healing rate was 94% (30/32) in the rPDT group and 72% (21/29) in the gPDT group ($p=0.002$). At 12 months, 74% fewer recurrences (88% [2/32]) were observed in the rPDT group than in the gPDT group (48% [7/29]) (relative risk 0.26; 95% CI 0.06-1.15) [319], [327]. The occurrence and severity of pain during therapy was comparable in both groups (relative risk 1.09; 95% CI 0.79-1.49) [327], [319].

Assessment: ALA-PDT with red light is superior to ALA-PDT with green light in terms of lesion-related healing rate and recurrence rate at 12 months. It should be noted that the risk of influence on the results is not comprehensible due to, among other factors, lack of blinding and that the study population was comparatively small.

ALA-PDT vs. cryosurgery

See [Chapter 7.5.1](#)

ALA-PDT vs. 5-fluorouracil 5% cream

See [Chapter 7.6.1](#)

ALA-PDT combined with microneedling vs. ALA-PDT alone

Population and study design: The prospective, controlled-randomized study by Wu et al. compared the efficacy of conventional ALA-PDT with pretreatment needling (PDT+) and ALA-PDT alone (PDT) for Bowen's disease at one study site [328]. For this purpose, of 43 lesions in 24 Asian-origin patients (12 men and 12 women) with a mean age of 55.5 ± 10 years, 21 lesions were randomized to the PDT+ group and 22 lesions to the PDT group. In the PDT+ group, the mean lesion diameter was 2.5 ± 1.0 cm and in the PDT group, 2.6 ± 1.2 cm. Three lesions were excluded in the PDT+ group and 2 lesions were excluded in the PDT group, resulting in 18 lesions for the PDT+ and 20 lesions for the PDT group in the final evaluation.

Interventions: In the PDT+ group, lesions were pretreated with a "plum-blossom needling tool". This is a small, hammer-like tool with 7 needles that are 4 mm long, 0.5 mm thick, and placed 4 mm apart on the surface. This is the reason for its name (plum blossom). For pretreatment of the lesions, the lesions were tapped vertically from a distance of approximately 5 cm until bleeding occurred. Before carrying out PDT, the resulting encrustations were removed.

Subsequently, a 10% ALA cream was applied beyond the lesion with a margin of clinically healthy skin and incubated for 3 hours under film occlusion. This was followed by exposure to a narrow spectrum LED (633 ± 10 nm) at a flux rate of 60-150 mW/cm², resulting in a total dose per lesion of 100 to 200 J/cm². The same exposure protocol was carried out in the PDT group but without pretherapy.

If healing was not complete, therapy was repeated up to 6 times. If complete healing of a lesion was not achieved even after 6 cycles, it was excised. After complete healing, monthly clinical controls were carried out for 12 months.

Results: Six weeks after therapy, a significantly higher ($p < 0.05$) complete lesion healing of 77.8% (14/18) was observed in the PDT+ group compared to 40% (7/20) in

the PDT group. After further cycles of therapy, 11.1% (2/18) in the PDT+ group and 50% (10/20) in the PDT group still showed complete lesion-related healing. In the PDT+ group an average of 2.9 ± 0.8 therapy cycles and in the PDT group 3.4 ± 0.7 cycles were required to achieve complete lesion-related healing. The recurrence rate at 12 months was 0% in the PDT+ group and 11.8% in the PDT group (2/17). The two procedures did not differ with regard to the painfulness of the treatments (pain score in both groups of 4.5) and the observed PDT-typical adverse events.

Assessment: Pretreatment with a "plum blossom needling tool" in combination with red light ALA-cPDT compared to red light ALA-cPDT alone showed higher efficacy and lower recurrence rates with comparable adverse event profiles. Overall, however, the results are based on a small sample size and the results are explicitly assumed to be only for people of Asian descent. Sources of error may be possible, for example, due to unreported blinding or non-selective reporting of adverse events for each study arm.

ALA-PDT combined with CO₂ laser ablation vs. CO₂ laser ablation alone

See [Chapter 7.5.2](#)

7.7.2

MAL-PDT

MAL is approved in combination with red light for topical PDT of Bowen's disease in immunocompetent adults. It is available as a cream (1 g cream contains 160 mg methyl (5-amino-4-oxopentanoate) as hydrochloride) and, in the case of red light PDT, is applied to the lesion site and surrounding area (5-10 mm border) with a layer thickness of 1 mm after lesion pretreatment (removal of scales and crusts and roughening of the surface). After an exposure time of 3 hours under a light-tight occlusive dressing and wiping off excess ointment residues, illumination with red light (continuous wavelength spectrum between 570 and 670 nm and a total light dose of 75 J/cm²; alternatively, narrow-spectrum light (e.g., by means of LED lights around 630 nm) can be used, with adjustment of the light dose (usually 37 J/cm²). Due to selective porphyrin synthesis in the abnormal keratinocytes of Bowen's disease, illumination causes a localized phototoxic reaction resulting in necrosis and apoptosis. This is a twice-daily treatment that should be given 1 week apart. According to the regulatory text "there is no experience treating Bowen's disease lesions larger than 40 mm. As with the treatment of Bowen's disease by cryotherapy or with 5-FU, the response rate of large lesions (> 20 mm in diameter) is lower than for small lesions." There is no approval in combination with natural daylight or daylight-emitting lamps (simulated daylight).

The studies identified in the literature search [249], [324], [325], [326] investigating MAL-PDT in immunocompetent individuals for the treatment of Bowen's disease include small collectives (median number of lesions treated with MAL-PDT: n=71 [6-96]). These studies use the same PDT protocol for conventional red-light PDT, with 3 of the studies using a narrow-spectrum light source [324], [325], [326] and only one study [249] (closest based on study timing) using a broad-spectrum light source. The range of complete lesion healings achieved varied from 73% to 93% [249], [326] and could be improved by pre-therapy with a fractional Er:YAG laser [325], [326].

MAL-PDT vs 5-fluorouracil 5% cream vs cryosurgery vs placebo

For more detailed information comparing these interventions, see [Chapter 7.5.1](#).

MAL-PDT vs. 5-fluorouracil 5% cream (immunosuppressed)

For more detailed information comparing these interventions, see [Chapter 7.6.1](#).

MAL-PDT combined with fractional Er:YAG laser vs. MAL-PDT alone.

Population and study design: The two studies by Ko et al. [326], and Kim et al. [325] investigate the efficacy of MAL-red light-PDT combined with fractionated Er:YAG-laser pre-therapy versus MAL-red light-PDT without pre-therapy for Bowen's disease at the lower extremities in Asian-descended collectives at one study center each. For this, Ko chooses an intra-individual comparison with double blinding and Kim chooses an inter-individual comparison approach with single blinding of the assessing subject.

In the study by Ko et al. [326] the patient population consisted of 21 patients (10 men and 11 women) with a mean age of 68.9 (35-88) years and at least 2 (n=58) histologically confirmed Bowen's disease lesions. Of the lesions, 32 were randomized to the fractionated laser pre-therapy (AFL-PDT) group and 26 lesions to the MAL-PDT alone group.

In the study by Kim et al. [325] 60 patients (30 each male and female) with a total of 84 Bowen's disease lesions were randomized 1:1 to the AFL-PDT and MAL-PDT groups. The AFL-PDT group consisted of 13 men and 17 women with a mean age of 71.8 ±12.6 years and 46 lesions with a mean lesion diameter of 11.6 ±7.0 mm. The Mal-PDT group was composed of 11 men and 19 women with a mean age of 69.9 ±13.1 years and 38 lesions with a mean lesion diameter of 13.2 ±6.4 mm.

Interventions: In both studies, pretherapy (AFL) was performed after gentle, bleed-free curettage of possible crusts and analgesia using a 30-minute application of 5% lidocaine-priolocaine cream with a fractional Er:YAG laser (2940 nm) at a penetration depth of 550-600 nm, level 1 coagulation, 22% therapy density, and single pulses. Immediately following, MAL cream (160mg/g) was applied approximately 1 mm thick beyond the lesion with a margin of clinically healthy skin of 5 mm and incubated for 3 hours under foil occlusion. Exposure was then to a narrow spectrum LED red light (632 nm) with a total of 37 J/cm². In the MAL-PDT study arm, PDT was carried out exactly the same after successful hemorrhage-free curettage. The procedures were repeated after 1 week regardless of the findings. Follow-up was carried out at 3 and 12 months after therapy. In the study by Kim et al., even 5-year data were collected [325].

Results: In the work of Ko et al. [326] the AFL-PDT group showed lesion-related complete healing of 93.8% (30/32) vs. 73.1% (19/26) at 3 months (p=0.031) and 87.5% (28/32) vs. 50% (13/26) at 12 months (p=0.002) compared to the MAL-PDT group alone. The study by Kim et al. [325] showed comparable rates for the two groups of 93.5% (43/46) vs. 76.3% (29/38) at 3 months (p=0.034), 87.0% (40/46) vs. 55.3% (21/38) at 12 months (p=0.002) and 84.8% (39/46) vs. 44.7% (17/38) at 5 years (p< 0.001). The recurrence rate at 12 months for the two groups (AFL-PDT vs. MAL-PDT) also showed comparable results in the two studies with 6.7% vs. 31.6% (p=0.022) in the work of Ko et al. [326] and 7.0% vs. 27.6% (P=0.033) and 9.3% vs. 41.4% (p=0.003), respectively, at 5 years in the work of Kim et al. [325]. In addition, the study by Kim et al. identified lesion diameter > 20 mm and previous other

therapies of the respective lesion as two independent factors of treatment failure [325].

Both studies showed the following adverse events in the AFL-cPDT group compared to the MAL-PDT alone group.

Ko et al. [326]: erythema (94.4% vs. 88.9%), crusts (100% vs. 100%), hyperpigmentation (66.7% vs. 55.6%), itching (27.8% vs. 22.2%), burning sensations (83.3% vs. 72.2%), and pain on a VAS (4.9 ± 2.0 vs. 4.3 ± 1.8). Comparable good or excellent cosmetic outcome of both treatment arms is reported in this study.

Kim et al. [325]: erythema (93% vs. 90%), crusts (80% vs. 80%), hyperpigmentation (76% vs. 70%), itching (70% vs. 67%), burning sensations (73% vs. 67%), and pain on a VAS (6.1 ± 1.0 vs. 5.6 ± 1.3).

Assessment: In both studies, complete lesion-related healing with fractionated Er:YAG laser pre-therapy was statistically significantly superior to MAL-PDT alone across all time points. This was especially true for the long-term data of 5 years (85% vs. 45%). The recurrence rate is also shown to be comparable in both studies and statistically significantly lower for the pretreated lesions, although again, the values at 5 years (9.3% vs. 41.4% recurrences) should be noted in particular.

Even though these two studies represent the largest comparative collectives for PDT in Bowen's disease, they must be considered rather small in relation to the frequency of the disease. Furthermore, the subject collectives are formed by predominantly Asian-origin (Korean) patients with a skin type mean of III-IV according to Fitzpatrick and are limited to the lower extremity. Therefore, a transfer of the results to other localizations or a Caucasian patient collective should be considered at least with caution.

MAL-PDT combined with continuous vs. fractional CO₂ laser

Population and study design: The randomized, controlled, intra-individual comparative study by Genouw et al. investigated the efficacy of continuous versus fractionated CO₂ laser therapy for MAL-cPDT in 15 patients (7 men and 8 women) with a median age of 73 (46-87) years and a total of 6 inoperable, histologically confirmed Bowen's disease lesions at a study site [324]. Lesions were either > 5 cm², which were then divided into 2 equal-sized study areas, or patients had 2 comparable-sized lesions. Because superficial basal cell carcinomas were investigated in addition to Bowen's disease in this study, the locations of each Bowen's disease lesion were not reported separately.

Interventions: The lesions were either pretreated in half or the 2 comparable lesions were each pretreated differently. One group received continuous CO₂ laser therapy (CL) with a pulse duration of 8 ms at a power of 12 W, so that ablation to the level of the papillary dermis was achieved. The other study arm received fractional CO₂ laser therapy (FL) at a power of 30 W (15% density, 18µm spot size, 240mJ energy, and a flow rate of 943 J/cm²). In case of hemorrhage, 20% ferric chloride was used to stop bleeding. For subsequent PDT, MAL cream (160mg/g) was applied approximately 1 mm thick and incubated for 3 hours under foil occlusion. Exposure was with a narrow spectrum LED red light with a total of 37 J/cm². The procedure was repeated after 2 weeks regardless of the findings. Assessments were made for complete healing (100%), partial healing (25-99%), and nonresponse (0-24%). Clinical assessments were

also confirmed histologically (punch biopsy). Corresponding follow-up examinations were carried out at 3, 6 and 12 months after the second cycle of therapy.

Results: At 12 months, both study arms (FL and CL) showed the same complete lesion-related healing rate of 80% (4/5). PDT-typical adverse events as well as cosmetic outcome was also the same in both groups. Regarding painfulness (including basal cell carcinomas), the second therapy was shown to be more painful ($p=0.026$) in the CL group compared to the FL group.

Conclusion: There are no differences in efficacy (80% CR at 12 months) and side effect profile between continuous and fractional CO₂ laser therapy before MAL-PDT. Only painfulness appeared to be less with fractionated laser pre-therapy at a second cycle than with continuous. Overall, however, the study population is very small (n=5 at 12-month follow-up), so the robustness of the results obtained is highly questionable. Furthermore, except for complete lesion healing, no results were reported separately by study arm and entity (basal cell carcinoma vs. Bowen's disease).

8 Therapy of invasive squamous cell carcinoma of the skin

M. Felcht, H. Breuninger, F. Bechara, S. Dengler, R. Gutzmer, A. Hauschild, L. Kofler, O. Kölbl, U. Leiter, D. Nashan, D. Vordermark, K. Wermker

8.1 Surgical therapy of the primary tumor

8.1	Consensus-based recommendation	new 2022
EC	The following risk factors of SCC shall be reported to the examining pathologist/dermatopathologist if present: recurrence, tumor diameter >2 cm, localization ear, lip or temple, immunosuppression and evidence of perineural invasion, no displaceability from the subsurface.	
	Strong consensus	

8.2	Consensus-based recommendation	new 2022
EC	Surgical therapy of the primary tumor shall be carried out according to the following algorithm (Figure 4):	
	Strong consensus	

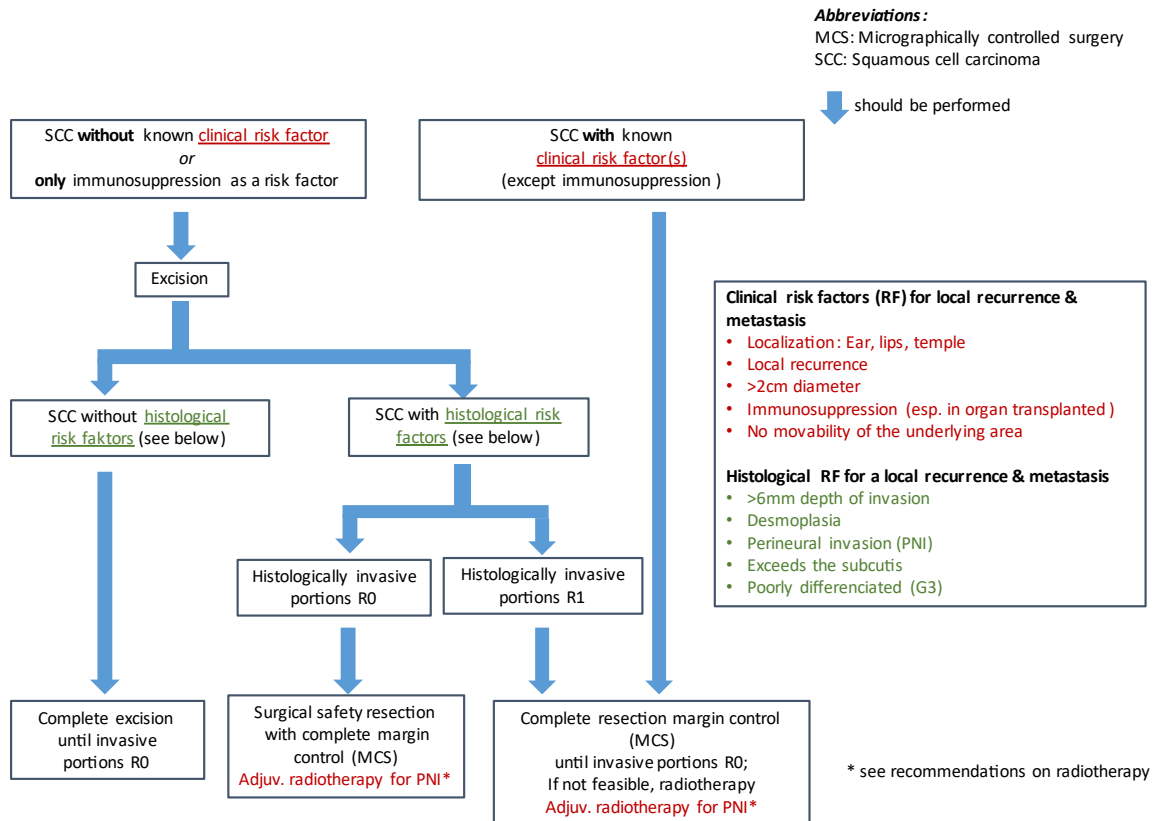


Figure 4: Algorithm for surgical therapy

Although there is no doubt in the literature that surgical excision of SCC of the skin is the method of choice [329] there is little consensus for the exact design of the excision and subsequent histological examination.

In reviewing the existing guidelines regarding local therapy of SCC of the skin, it is noticeable that discrepancies continue to exist regarding the assessment of risk factors that influence the locoregional behavior of SCC and also regarding the modalities of local therapy. This is due to the fact that the existing literature on these topics consists almost entirely of retrospective and also partly small studies, which often result in heterogeneous results.

8.1.1 Risk factors for loco-regional progression and tumor-specific survival

Knowledge of the factors leading to local recurrence and regional metastasis is important for surgical planning. A tumor with high potential for local infiltration should be treated differently than one with low potential.

Both retrospective and few prospective studies have been carried out to analyze risk factors. However, for the latter, there is still a lack of studies with sufficiently large patient numbers. To date, 7 prospective studies have been published [20], [330], [19], [331], [52], [332]; three of them with patient numbers ranging from 502 to 1,434 of different time periods from one institution [20], [330], [19]. A recently published study of 745 tumors was multicenter but included mostly rather low-risk SCC (95% were well differentiated, 85% smaller than 2 cm in diameter) [332]. Two other prospective studies examined 210 and 224 patients [331], [52]. Another

prospective study with 1,010 patients analyzed the risk factor immunosuppression [29]. All other studies are retrospective with patient numbers ranging from 69 to 1468 patients [333], [334], [335], [54], [336], [337], [338], [339], [340], [47], [341], [342], [53], [343], [53], [344], [345], [346]. In 7 reviews the existing literature is assessed [347], [348], [349], [32], [350], [351], [352]. From these, it can be seen that the collectives have different compositions. Thus, the rates of local recurrence and metastasis are very difficult to evaluate by these large differences, also with regard to risk factors.

Several papers point to an insufficiency AJCC classification to predict local recurrence or metastasis [339], [350], [353], [332]. This has led to alternative classification systems being proposed [354].

Overall, as detailed by Rowe in 1992, the following important risk factors can be noted:

- Tumor diameter >20 mm
- Depth of infiltration >Level 3
- De-differentiation
- Perineural invasion
- Localization ear and lower lip
- Immunosuppression
- Histological tumor thickness >6 mm
- Desmoplasia

It is currently unclear how to weight the individual factors. According to the publications available to date, tumor thickness > 6 mm, desmoplasia and perineural invasion are the strongest prognostic factors, especially for local recurrence, but also for metastasis [32], [346].

8.1.1.1 Tumor diameter

Clinical tumor diameter of 2 cm is a prognostic factor for rough guidance in all publications except one [331]. In most publications, tumor diameter was presented as a risk factor. In a few, the rate of local recurrence and metastasis are calculated for this limit. For tumors ≥ 2 cm in diameter, local recurrence occurred between 2-7% [19], [338], [53], [347] regional metastasis at 9-16% [19], [53] or at Rowe 30% [347]. For this reason, a standard indication of clinical diameter is recommended in the European recommendations on SCC.

However, tumor diameter alone does not provide enough information about actual "high-risk" tumors. Therefore, as the publications show, additional histological information (differentiation, perineural invasion, depth of invasion or tumor thickness) as well as information about patient-related factors is needed [355].

8.1.1.2 Tumor thickness

According to AJCC, tumor thickness is measured from the stratum granulosum or the base of an ulceration to the deepest infiltration [349]. Measurement at the deepest point of the ulceration is critical because severely ulcerated tumors then have a smaller tumor thickness and are thus rated at lower risk, although the opposite may be true. To the authors' knowledge, a study on the value of ulceration has not yet been published. Tumor thickness in the above studies is always measured from the

highest elevation (stratum granulosum there) to the deepest infiltration regardless of ulceration [19], [53], [347].

Tumor thickness measured on histological section is dependent on tumor diameter but is a stronger prognostic factor than tumor diameter in multivariate analyses. In 7 other studies, tumor thickness is also analyzed (from 3-7 mm) [331], [52], [341], [348], [349], [350], [32]. In the old 7th edition of the AJCC classification, tumor thickness greater than 2 mm is cited as a high-risk factor [342], [32]. The tumor thickness >2 mm had been introduced in the literature in 1990 [334] as a limit of a possibility of metastasis starting at 2 mm and confirmed in further publications. This limit is critical because it would mean that the majority of SCC would be considered a high-risk tumor. The 8th edition of the AJCC classification has been amended to include a tumor thickness ≥ 6 mm for head and neck tumors. This is also consensus in virtually all classification systems [354].

8.1.1.3 Infiltration depth

The infiltration depth is generally dependent on the tumor thickness. The thicker a tumor, the greater its infiltration depth, unless it grows purely exophytic, which rarely occurs. The depth of infiltration is considered a prognostic factor, especially in relation to the anatomical stratification (especially from Clark level V, corresponding to infiltration and exceeding the subcutis) [331], [54], [342], [53], [347], [348], [349], [32], [350].

However, tumor thickness is superior to infiltration depth as a prognostic factor. In the staging system according to Breuninger [353] which was shown to be superior to the other classification systems as a predictive value of metastasis in an independent analysis of a Norwegian group, infiltration depth is not considered .

8.1.1.4 De-differentiation and desmoplasia

De-differentiation is described as a prognostic factor in almost all publications. In the EDF-EADO-EORTC recommendations, both dedifferentiation and desmoplasia are mentioned as independent risk factors [354]. Nevertheless, desmoplasia is not mentioned in the majority of publications. Thereby, the frequency of desmoplasia differs depending on the studied patient collective. Desmoplasia was introduced as an independent risk factor for the occurrence of local recurrence and regional metastasis in a large prospective study in 1997 [330]. In those publications investigating desmoplasia as a risk factor, again, dedifferentiation is not a significant factor [330], [19], [20]. It is likely that desmoplasia was evaluated as a de-differentiated type with the other forms of de-differentiation in most studies [54], [48]. Desmoplasia is also analyzed in another study [350] and is mentioned as a prognostic factor in some guidelines [356], [99], [356], [356], [357]. In the Norwegian study described above, in which the different classification systems were compared, the classification systems that did not take desmoplasia into account were inferior in their predictive value with regard to metastasis. The high local recurrence rate is also due to the fact that desmoplasia in particular often eludes histological detection in the periphery remote from the tumor due to single cell infiltration [358]. Therefore, evaluation of the margins by immunohistochemical staining facilitates a higher rate of detection of tumor extensions [359].

8.1.1.5 Perineural infiltration

Perineural infiltration (PNI) is consistently recognized as a high-risk factor. Importantly, it may be detectable microscopically, clinically as well as radiologically [354].

The frequencies of occurrence are reported very differently. They range from 1% to 100% [337], [360]. A high PNI (55-64%) is found in highly selected collectives [342], [58], [361] of which in 64% in a collective of immunosuppressed patients. In most publications PNI is detected in 2% and 10% of tumors [48], [54], [331], [362], [363], [339], [52], [340], [364]. Some publications show an increased incidence of PNI in desmoplastic SCC [330], [54], [365]. One paper found PNI exclusively in desmoplastic tumors [366]. In addition, a major factor here seems to be tumor diameter. Karia et al. showed a significantly higher risk for local recurrence in perineural growth around nerves with a diameter > 0.1 mm compared to smaller nerve diameters [18]. Of the established classification systems for cutaneous SCC, only the Brigham and Women's Hospital classification lists the cut-off of 0.1 mm nerve diameter as a separate risk factor.

8.1.1.6 Localization

Localization as a prognostic factor has been evaluated differently. The ear (region) and lower lip red have been analyzed as prognostic factors in numerous studies [19], [52], [336], [337], [339], [341], [342], [53], [347], [348], [349], [32]. In the meta-analysis by Thompson et al. which included over 23,000 SCC, the highest risk for local recurrence was shown at the temple, lip and ear [32]. Furthermore, in addition to temple, scalp, nose and also cheek are identified as high-risk localizations in numerous publications [337], [342], [53], [349], [32], [346], [32]. Only three papers consider the trunk as a separate risk factor [335], [349], [346]. In a large prospective work with 1434 patients, 40 died due to SCC [20]. 35/40 patients who died had SCC in the head and neck region. Accordingly, in the old European guideline the entire head and neck region was classified as high risk or intermediate risk and only trunk and extremities were low risk [355]. In the new recommendations, only the temple, ear and lip regions are included [354]. Two studies do not consider localization as a prognostic factor [54], [340].

8.1.1.7 Immunosuppression

Immunosuppression as a tumor independent high-risk factor is undisputed [19], [20], [29], [58], [53], [354].

8.1.1.8 Other factors

If a previously treated SCC is present, this is evaluated as a risk factor in some publications [355]. This may be due to insufficient initial treatment or to the high local malignancy of the tumor, which per se leads more frequently to local recurrence, regardless of the treatment modality [330], [19], [20]. This phenomenon malignancy of the tumor vs. insufficient local treatment often cannot be separated in the literature [331], [54], [338], [367]. Also, the type of treatment is thought to influence the course.

8.1.2 Surgical therapy and histological incision margin control

8.1.2.1 Excision for tumors with diameter smaller than 10 mm

For small tumors <10 mm, curettage with the sharp 7-mm ring curette or deep horizontal ablation ("shave" excision) is suitable. Both methods ensure sharp ablation, providing a clear specimen for histopathological examination. There are no studies for this in the literature. However, the diameter of the excised tissue should not be less than 5 mm. The lower corium or just under the subcutis should be reached for depth. If the tumor was removed in toto in this way, the subsequent secondary healing, if it is possible at the corresponding localization, leads to very good aesthetic results [368], [369]. In addition, inflammatory processes can lead to regression of remaining tumor parts after horizontal ablation or curettage for example [370].

For larger and thicker tumors, the depth should reach at least deep into the subcutis, whenever possible at least 6 mm deep. This allows assessment of tumor thickness and differentiation and thus a more accurate prognostic assessment by histopathologists. However, it should be noted that this may not always detect desmoplasia, as it may occur in subareas. The same applies to PNI, which can often be detected only in the tumor periphery.

8.1.2.2 Histological backup before major excision

Often, the diagnosis of SCC or at least an epithelial malignant tumor can already be made clinically with a high degree of certainty and thus a surgical indication is given. In these cases, the sample biopsy would be an unnecessary burden for the patient. If a trial biopsy is nevertheless necessary, a 6-mm-diameter punch, set at the highest point of the tumor, is most suitable. A spindle-shaped excision is the alternative. Since even a specimen biopsy is often difficult to classify histopathologically or not all necessary histological parameters can be collected (see [Chapter 8.1.2.1](#)) an incision through the entire tumor is more informative. This is best achieved by a clinically complete tumor excision. A marker (for example, at 12 o'clock relative to the body axis) is useful for later orientation in case of R1 resection. In case of a complete excision, a reprocessing of the cut edges should follow in order to ensure an R0 or R1 resection.

8.1.2.3 Histological section margin control: gapless vs. non-gapless workup of excised tumor material

Histological specimens can be evaluated either on frozen section or on paraffin-embedded material. Kerosene sections are the gold standard in terms of sensitivity and specificity, especially for SCC of the skin, as the cells of the stratum spinosum do not stain as intensively as the cells of the stratum basale. Other methods such as confocal laser microscopy or "Rapid Lump Examination" have not been reviewed for SCC of the skin [371], [372].

The embedded preparation can be processed in different ways. In particular conventional slicing is distinguished from 3D histology. In contrast to conventional slicing of the excised material by parallel, lamellar, serial cuts (bread loaf technique), which have diagnostic gaps, in 3D histology the outer edges of the entire excised material are cut off into embeddable strips or re-excised as such and pressed flat on the outer side according to the rules of the clock. In this way, a transformation of the three-dimensional cut surfaces of the material into two-dimensional histological

preparations with a gap-free view of the cut edges of the excised sample is achieved [373]. The larger the specimen, the less time is required for sectioning and examination for edge sectioning compared to bread loaf technique [374].

One paper prospectively investigated whether the different reprocessing techniques lead to differences in recurrence frequencies in basal cell carcinoma [375]. Recurrence frequency was significantly lower when gapless reprocessing was used. With limitations, this may be transferable to SCC. However, it should be critically noted that this difference was significant only in nodular basal cell carcinoma, since overall the number of recurrences was very low and nodular basal cell carcinoma constituted the largest subgroup. Furthermore, the spacing between the lamellae in the bread loaf technique can certainly be set even tighter than 5 mm (as applied in the study).

8.1.2.4 Local excision with wide resection margins and subsequent lamellar serial reprocessing

In the procedure of wide resection ("wide local excision", WLE), the primary tumor is excised with a certain safety margin. The size of the safety margin is not standardly defined for this form of resection and a wide variance is described in the literature (4 to 10 mm, maximum 50 mm) [376], [377], [378], [379], [355]. The current European Guideline recommends removal of a clinical safety margin of 5 mm for low-risk SCC and 6-10 mm for high-risk SCC for the WLE technique [379]. A larger resection margin compensates for the uncertainty of histological examination described below and also increases the rate of complete excisions even at the first procedure.

Workup using bread loaf histology (serial sectioning technique/bread loaf sections) is carried out using the kerosene sectioning technique with lamellar, serial sectioning of the tumor specimen. In conventional histological examination via the aforementioned bread loaf histology, the width of the lamellae is not specified in the existing literature except in two cases, although the quality of the histological examination depends significantly on it [362], [377]. Since examination with bread loaf sections is technically incomplete ("diagnostic gaps"), surgeons usually choose rather generous resection margins for the initial excision of a tumor, hence the term (WLE). This results in larger defects [380]. For this reason, the current European Guideline points out that, for example, in the head and neck region, the use of the tissue-saving MKC technique with gapless three-dimensional incision margin control can be useful [379].

The data in the literature on resection distances for WLE is relatively meagre. The most important and most cited study on this is that of Brodland 1992, which states that tumors with <20 mm diameter can be excised with 4 mm resection distance from the clinically visible tumor borders in 96% R0 [381]. For tumors with ≥ 20 mm, this is always achieved with a resection margin of 6 mm. If the resection margin is increased to 9 mm, 100% R0 resection is achieved. A limitation of this study is that predominantly low-risk tumors were investigated. A more recent prospective study confirms this assumption, as up to 49% of SCC with PNI required a resection margin of 6 mm or more [48]. On average, resection margins of 6.5 mm are reported [52], [377], [382], [383]. The benefit of a larger resection margin is clearly demonstrated by a recently published retrospective work showing that taking a safety margin of more than 5 mm in high-risk SCC, improves tumor-specific survival [384]. However, Philipps et al. state that clinical resection margin data were not available, so the available data are based on histological resection margins (indicated by the

pathologist) [384]. In the other publications on WLE cited above, no data on resection margins are provided.

Some papers also address the question of how frequently R1 resection occurred at initial excision. Rates of 1-16% are mentioned. On average, it is approximately 6% [382], [385], [386], [387]. Further studies investigated whether initial R1 excision influences the number of recurrences. The data on this are very inconsistent with 8-68% recurrences [385], [383]. One retrospective work on a very large collective (n=1468) of patients investigated whether there are subgroups in which the simpler technique of WLE has more frequent positive excision margins. This was significantly more common in SCC that occurred in older patients or in the head and neck region, were pretreated, had a larger diameter or high tumor thickness [344]. From this, it can be concluded that the relatively simple method of WLE can be a useful method in SCC that do not have the above factors.

The advantage of the method is that the tumor can be seen on almost all sections in its expression. The disadvantage is incomplete work-up of the margins with resulting false negative findings. It is regrettable that it is not precisely defined how wide the distance between the lamellae may be. This is especially problematic in large, multifocally growing tumors. Keeping the distance between the lamellae small in very large tumors quickly results in a large number of sections to be found. The definition of how large the histological distance of the tumor from the edge of the incision should be to still be considered an R0 resection varies from 1 to 4 mm in WLE studies [340], [47], [385]. Less than 1 mm has been defined as R0 in very few papers [382].

8.1.2.5 Micrographically controlled surgery

In the development of the gapless cut edge method, different procedures are given in the literature. F. Mohs was the first to introduce chlorine zinc etching in 1941 [388]. As early as 1963, Drepper was the first to systematically examine flat excisions from the wound bed histologically on their outer surface using the kerosene section method, in order to detect tumor extensions [389]. Mohs named this procedure "Microscopic Controlled Surgery" [390], [391]. In Germany, the term subsequently became established (MKC) [392], [393].

In the current AWMF guideline on MKC, this is defined as a technique the goal of which is to achieve histologically proven complete removal of malignant tumor components (R0 resection) while sparing the healthy environment as much as possible [393]. The AWMF guideline lists different techniques, all of which are subsumed as MKC. Techniques that can be safely described as MKC are those in which there is a gapless evaluation of the cut edges. In addition, in Germany, non-gapless techniques with closely set lamellae are sometimes also referred to as MKC, although this contradicts the original idea of a gapless assessment of the outer margin of the excised tissue.

The majority of published gapless MKC studies in SCC originate from countries where findings are mainly made on frozen sections. This includes original papers [333], [53], [347], [348], [332] and reviews [394], [395], [351]. In Germany, MKC is mostly carried out on paraffin-embedded material [393]. For the gapless MKC on paraffin-embedded specimens, the term 3D histology [396] or in the US "complete circumferential peripheral and deep margin assessment (CCPDMA)" has also been proposed [397]. There are also several studies on this technique with findings on

kerosene sections [330], [19], [20], [364], [398] ("slow Mohs-surgery"). One study investigated whether findings in basal cell carcinoma initially carried out on a frozen section were identical to findings on paraffin-embedded specimens [362]. This was the case in 158/160 (98.8%) of the cases. Nevertheless, it must be stated that the diagnosis of SCC on frozen section is not easy and also presents more difficulties than in basal cell carcinoma due to the different staining behavior in an HE stain. Therefore, in the current European guideline, after initial diagnosis on a frozen section, control on paraffin-embedded sections is recommended [379].

The question of how often R1 resection is present in primary tumor excision is mentioned in only one of the publications and amounts here to 43% [48]. This seems quite high compared to WLE, but this is not surprising given the small initial excision distances in the concept of a skin-sparing surgical technique. It was not tested whether this influences the recurrence rate.

The advantage of the methods is the high sensitivity for detecting tumor extensions. However, it should be borne in mind that desmoplastic tumors, for example, are characterized by single-cell infiltration, which may elude histological detection in the periphery remote from the tumor. Nevertheless, it can be stated that with this method, the primary safety distance is usually kept small (1-5 mm, depending on tumor diameter and location), as overall the sensitivity to detect tumor extensions is high. This allows significantly smaller defects, which can be advantageous in certain localizations such as the facial region [380]. In addition, from a purely practical point of view, it may make sense to use gapless MKC for very large tumors, as a bread loaf technique (with narrow lamellae) necessitates the reporting of very many sections. However, this is of course dependent on the individual site conditions, as only temporary application of gapless MKC can also be time-consuming. The disadvantage is that only the plane of the incision margin is visualized and the tumor center must be examined separately, either after curettage as in Mohs surgery or from the remaining remnant after separation of the outer sides. And with the MKC method, increased re-operations may be required to achieve an R0 situation.

8.1.2.6 **When should micrographically controlled surgery with gapless reprocessing of the incision margins be aimed for?**

In all following considerations regarding surgical R0 resection with/without safety resection, it is important to compare tumor-specific survival with overall survival. It has been shown that only about 2% of patients with cutaneous SCC actually die from SCC and about 40% die from other causes [20], [399], [398]. One may hope that this will become even rarer in the future, as there are promising therapeutic options with immunotherapy. However, these will not be readily applicable in some patients, so that it is necessary to prevent inoperable complications in these groups as far as possible (e.g. immunosuppressed patients).

Local recurrence rates after WLE, vary widely between 0-53% [347], [399]. Within the same publications, rates of local recurrence can also vary many times over for the same treatment modality, depending on the subcollective studied [338], [347], [385], [400]. The majority of publications report rates of 2-13% [331], [335], [347], [364], [364], [362], [364], [401], [364], [383], [364], [402], [364], [403], [343], [343], [404], [345], [345], [405].

In a prospective study in which 277 SCC were treated with WLE followed by bread loaf histology, the regional metastasis rate was 23% [331]. Similar regional metastasis

rates of 5-47% are found in retrospective studies [336], [338], [340], [341], [342], [347], [363], [399], [401]. Other studies show lower metastasis rates of 2-4% [52], [335], [340], [362]. Overall, it should be noted that this method was more commonly used by oral and maxillofacial surgeons who treated the larger tumors and thus patients were per se at greater risk of developing metastases. Thus, there is obviously a bias to the disadvantage of WLE. A comparison of the mentioned studies is virtually impossible, because often the risk factors of the tumors are not mentioned [347], [58], [394], [395], [406] or the information about the metastasis rate is missing [367], [385], [386], [403].

Local recurrence rates of MKC vary between 0-33% [347], [332]. Most publications report recurrence rates between 2-8% [395], [19], [347], [407], [398], [403], [286], [408], [409], [410], [411], [345]. Looking specifically at the local recurrence rate between non-desmoplastic and desmoplastic SCC, it differs significantly with 4 vs. 26% [412].

Overall, the recurrence rate after MKC appears to be lower than after WLE with an average recurrence rate of 2-13% (see above), but there are risk constellations (such as desmoplasia) in which recurrences may occur frequently despite gapless MKC. The assumption of an overall lower recurrence rate after MKC is supported by two recently published retrospective comparative papers showing that both the local recurrence rate and the metastasis rate are lower with MKC than with WLE [345], [413]. However, both papers lack details on the exact workup of the WLE-treated specimens, in particular the magnitude of the distance between the individual lamellae. In addition, data on the distribution of differentiation [345] or desmoplasia [345], [413] are missing. However, it is noteworthy that in both studies, the MKC-treated collectives had a significantly worse risk profile and contained, for example, larger tumors that infiltrated deeper structures [345] or were more frequently immunosuppressed [413]. Other studies could not demonstrate a significant superiority of MKC in terms of recurrence rate [403], [400]. This may be due to the fact that, depending on the subpopulation studied, the rates of local recurrence can vary many times over for the same treatment method [330], [19].

Low metastasis rates of 0-7% have been described after Mohs surgery [333], [53], [408], [409], [410], [19], [52], [364], [364], [402], [364], [409], [411], [411], [413], [332]. However, in much of the available data, Mohs surgery has tended to treat smaller tumors [395]. This is particularly evident in a much-cited prospective study in which locoregional metastasis did not occur in any case of the 1263 SCC studied [407]. It is important to note that even recent studies with mostly smaller tumors show that MKC cannot 100% reliably prevent either locoregional recurrence or metastasis [345], [332], [413]. Moreover, the proportion of patients who die due to SCC is lower after MKC than after WLE but death is not excluded [400]. If desmoplasia is present (despite MKC) the risk of dying from SCC is increased 8-fold [20]. All this implies that even after gapless MKC, removal of an additional safety resectate after R0 excision might well be reasonable for certain high-risk patients, especially since recurrence of SCC [329] or metastasis is associated with a poor prognosis.

As early as 1992, Friedman [376] published a commentary on the review by Rowe et al. [347] in which he called for prospective randomized trials for the different therapeutic modalities. There is still no such study [395]. For Germany it is aggravating that different centers use different techniques of MKC or some techniques are called MKC that are accompanied by incomplete visualization of the incision margins [414]. Often the surgeon is not aware of the distance between the

individual lamellae in bread loaf technique processed specimens and therefore cannot really judge how reliable an R0 finding is, if this was based on bread loaf technique processed histology.

In conclusion, for the reasons mentioned above (lack of good randomised, multicenter studies with similar cohorts; different techniques of MKC; gapless vs. non-gapless workup and formaldehyde-fixed vs. frozen section), it is difficult to say when MKC should definitely be sought. At the same time, this question is very important due to the fact that even the new immunotherapies are not helpful or might not be able to be used in everyone (e.g., organ transplant patients), are expensive and have numerous side effects. Overall, it must be stated that a general recommendation to treat all SCC with gapless MKC does not seem justified at present. At the same time, the targeted use of this technique for certain high-risk patients seems to be a reasonable option.

8.2 Operative procedure after R0 resection

8.2.1 Safety resection after R0 resection

The course of SCC of the skin can be complicated by local recurrence (local recurrence rate), local metastasis to the skin, metastasis to the regional lymph nodes or distant metastases. Optimally, taking a safety resectate should reduce the risk of developing any of these complications.

However, interpretation and comparison of the studies described above is difficult due to the application of the different excision techniques and histological cut margin controls in Germany and also due to the differently applied techniques of MKC. At the same time, however, the vast majority of the studies show that after both methods (WLE and MKC), in principle, the risk of both local recurrence and metastasis for high-risk SCC is not 0%. Recurrence of SCC is associated with a poor prognosis, especially if this finding is unresectable [20], [329]. If multiple risk factors occur simultaneously, this additionally worsens overall survival [20].

According to WLE, the current European guideline recommends removal of a clinical safety margin of 5 mm for low-risk SCC and 6-10 mm for high-risk SCC to the sides [379]. For depth, excision of the subcutaneous adipose tissue and, if localization is appropriate, entrainment of the galea aponeurotica is recommended [379]. Data for this are practically not available [355]. According to WLE, the Scottish guideline recommends excision of at least 4 mm for low-risk SCC and at least 6 mm for high-risk SCC [356]. Neither the European nor the Scottish guidelines comment on whether the additional collection of a safety resection specimen after gapless MKC is useful in certain high-risk patients.

Given the importance of the question regarding safety resectate intervals after excision of a SCC, an attempt was made to formulate recommendations based on the limited data available. It was also considered that i.) a distinction must be made between gapless vs. non-gapless resection and ii.) even gapless resection of the incision margins does not protect against the possibility that tumor cells have detached from the primarius and may be located in the immediate periphery of the tumor.

8.2.2 Wound closure after confirmation of R0 resection

8.3	Consensus-based recommendation	checked 2022
EC	As long as an R0 resection has not been histologically confirmed, wound closure shall only be performed if the resection margins can be clearly assigned postoperatively (e.g., no displacement flaps).	
	Strong consensus	

The histological findings in the paraffin section are available at the earliest on the day after the excision. The areas of subtotal excision are also reported. The probability of subtotal excision increases proportionally with tumor size and inversely proportionally with excision distance. For WLE, it was stated above that rates of R1 resection after initial excision range from 1-16%, with a median of 6% [382], [385], [386], [387]. After MKC, the rate is higher (up to 43% [48]) because of the rather small resection distances. For the latter procedure, the cryostat incision procedure is mostly used internationally. Re-excision can then be performed promptly.

In the case of unfavorable localization or very large tumors, it is advisable not to close the defect plastically until tumor-free incision margins have been demonstrated. This is especially true if local flap plastic surgery is planned, since it can sometimes displace the margins of the defect, making it difficult to assign a subsequent excision later.

8.3 Sentinel lymph node biopsy

8.4	Evidence-based statement	checked 2022
LoE 3	There are no valid data on the prognostic and therapeutic value of sentinel lymph node biopsy available.	
	[415], [416], [417], [418] 3: De novo research	
	Strong consensus	

One option for minimally invasive lymph node diagnostics is the removal of one or more sentinel lymph nodes (SLN). By means of a radioactive tracer or a dye, which is infiltrated peritumorally, lymph drainage and SLN are visualized, which are then surgically removed and examined histopathologically (sentinel lymph node biopsy, SLNB). The quality criteria (sensitivity, specificity, negative predictive value, false negative rate) of SLNB in SCC of the skin show a sensitivity of 79%, a specificity of 100% and a negative predictive value of 96%, so that the procedure can purely technically be classified as reliable [418], [415], [419], [420]. The possibility of imaging even atypical lymphatic drainage pathways can be advantageous especially in the head and neck area and also in recurrent tumors or after previous operations [421], [422], [423].

It must be taken into account that in the primary therapeutic excision of large tumors (>20 mm in diameter, referred to in the literature as high-risk tumors), if necessary with safety resectate, naturally relatively large defects arise. This generally alters the lymphatic drainage in the head and neck region with its complicated lymphatic vessel supply. This makes a possibly indicated SLNB possibly insufficient, because the site of injection then no longer corresponds closely to the tumor center. Thus, if lymphatic scintigraphy is planned as part of SLNB, an adequate trial biopsy should be performed before tumor excision to determine the risk of metastasis as best as possible by histological parameters. The size of >20 mm in diameter is relatively imprecise without additional information and still includes many low-risk tumors. One would then risk overdiagnosis by SLNB using only this single parameter in often elderly patients.

Nevertheless, a general recommendation for SLNB cannot be given at present because sufficient and sufficiently valid data on the prognostic and therapeutic value of SLNB are lacking [424], [425], [426], [427], [428], [99]. Studies to date have not yet been able to prove any advantages with SLNB in terms of disease-specific and overall survival as well as metastasis-free survival with statistical significance [429].

Most of the available data address the use of SLNB in high-risk profiles (see [Chapter 8.1.1](#)). Numerous studies cite a potential benefit (detection of clinically occult micrometastases, avoidance of unnecessarily extensive lymphadenectomies with higher morbidity compared with SLNB) in high-risk SCC, which is expected to have a metastatic risk >10%. A recent paper studied 720 patients with high-risk SCC, 150 of whom received SLNB [430]. It was shown that patients who received sentinel lymph node biopsy showed no benefit in terms of further metastasis or tumor-specific death. Thus, SLN removal for SCC of the skin continues to show no benefit, although of course complications of SLNB (see studies in breast cancer and melanoma) are rare (3-5%) and primarily include lymphedema, infection, hematoma, seroma, cutaneous lymphatic fistula, and suture dehiscence [431], [423], [424], [99], [432], [433], [434], [435].

8.4 Prophylactic and therapeutic lymphadenectomy

8.5	Evidence-based recommendation	checked 2022
GoR A	Prophylactic lymphadenectomy shall not be performed.	
LoE 3	[428] , [436] , [437] , [438] , [439]	
	Strong consensus	

8.6	Evidence-based statement	checked 2022
LoE 3	Data on the value of regional lymphadenectomy in the setting of a positive sentinel lymph node biopsy are insufficient.	
	[428] , [436] , [437] , [438] , [439]	
	Strong consensus	

8.7	Evidence-based recommendation	checked 2022
GoR B	Regional (therapeutic) lymphadenectomy should be performed when lymph node metastasis is clinically manifest.	
LoE 3	[428] , [436] , [437] , [438] , [439]	
	Strong consensus	

8.8	Evidence-based statement	checked 2022
LoE 3	Improvement in locoregional tumor control has been described for regional therapeutic lymphadenectomy for nodal metastasis.	
	[428] , [436] , [437] , [438] , [439]	
	Strong consensus	

For cutaneous SCC a (prospective) benefit of prophylactic (elective) lymph node dissection in terms of disease-specific and overall survival has not been proven so far [438], [440]. A benefit can only be expected from a metastasis frequency of more than 20%, for the head and neck area a study could work out an expected benefit here [439] ("utility" for each treatment is a weighting scheme for the expected value of each member of the decision tree. Utilities are numeric values that represent a person's preference for different health outcomes after treatment. Each utility state has a numerical value between 0 and 1; death is traditionally assigned a value of 0, whereas a disease-free state with no significant effects of treatment is assigned a value of 1). Only in very advanced stages (such as skull base proximity or nodal metastasis in the parotid area) do individual studies (retrospective case series) report a benefit from elective neck dissection in the head and neck region [441], [442].

European consensus-based guidelines recommend therapeutic lymph node dissection for clinically (cN+ in staging, macrometastasis) or histologically confirmed metastasis (pN+, micro- or macrometastasis in SLN, metastasis confirmed by fine needle biopsy or lymph node removal) [99]. As a rule and according to the recommendation of most authors, it includes not only the region or level of the confirmed metastasis but also the directly adjacent levels in each case (adaptation from the S3 guideline "Oral cavity carcinoma" [440]. Sufficient data for an evidence-based decision on the extent (level, radicality) of the necessary therapeutic lymphadenectomy in cN+ / pN+ situation do not exist [443], [444]. Data justify therapeutic lymphadenectomy in cN+ / pN+ by expected better locoregional tumor control and – depending on the extent of nodal metastasis – partial also of disease-specific survival, whereas adjuvant radiotherapy in pN+ was additionally performed [445], [446], [443], [423], [437], [442], [447], [448], [449].

Therapeutic lymph node dissection should only be performed if a surgical procedure seems possible and reasonable with regard to the general condition (operability) and in the context of the overall concept. This requires the intention of R0 resectability of the metastasis(es) (local operability). If general and local operability are not given, non-operative therapy modalities should be given preference in the context of an interdisciplinary tumor board decision.

8.5 Lymphadenectomy in the head and neck region

8.9	Evidence-based statement	checked 2022
LoE 3	There is no general consensus on the level of dissection required in the head and neck region.	
	[428] , [436] , [437] , [438] , [439]	
	Strong consensus	

There is no consensus in the literature on the extent of lymph node clearance in the head and neck region. The decisive factor in particular is the localization of the primary tumor.

For a few localizations, a rather constant lymphatic drainage area is described, e.g., for the area of the lower lip, lymphatic drainage into the submental and submandibular lymph nodes as well as high-cervical lymph nodes (level Ia, Ib and II according to Robbins et al.) [\[450\]](#), [\[451\]](#), [\[452\]](#), [\[453\]](#).

Most localizations exhibit highly variable lymphatic drainage. For example, a wide variety of lymphatic drainage pathways are described for the ear region alone: to retroauricular and occipital, to infraauricular, to cervical levels II, III and IV, and to parotid lymph nodes [\[454\]](#), [\[455\]](#), [\[456\]](#). This variable lymphatic drainage, which may include the contralateral lymphatic drainage areas if the tumor is located close to the midline, also applies to other regions of the head and neck [\[436\]](#), [\[457\]](#), [\[438\]](#), [\[458\]](#), [\[459\]](#). Thus, it has been shown that in skin tumors of the head and neck region, a contralateral sentinel lymph node is present in 7% [\[460\]](#). In particular, the lymphatic drainage into the parotid area is also important from a clinical-surgical point of view due to its proximity to the facial nerve, which should be preserved and spared if at all possible in the course of a lymphadenectomy/parotidectomy [\[461\]](#), [\[462\]](#), [\[461\]](#), [\[462\]](#).

If possible, a gentle, so-called selective-functional excision should be performed while preserving the functionally significant structures (especially nerves, muscles and vessels). Only in cases of extensive metastasis are radical dissections recommended with then increased morbidity. In analogy to oral cavity carcinoma, the results of a selective neck dissection are not inferior to those of a modified-radical or radical neck dissection with regard to tumor control, disease-specific and overall survival (adaptation from the S3 guideline "Oral cavity carcinoma") [\[463\]](#), [\[464\]](#), [\[465\]](#), [\[466\]](#), [\[467\]](#).

8.6 Radiotherapy and postoperative radiotherapy

8.10	Evidence-based recommendation	checked 2022
GoR B	For tumors that are not locally resectable in sano or inoperable patients, radiotherapy should be performed.	
LoE 3	[468] , [400] , [469] , [470] , [471] , [472] 3: De novo research	
Strong consensus		

Prospective randomized studies comparing the effectiveness of primary radiotherapy in terms of local tumor control and patient survival compared to other local therapy modalities are not available. However, retrospective studies show high local tumor control after primary radiotherapy. Mendenhall reported a local recurrence rate of 6.0%/10.5%/12.8% at 5/10/15 years for a 245 patient collective. The local recurrence rate was dependent on the initial tumor size. For T1 tumors it was 1.7% after 15 years, for T2 tumors 7.4%/14.2%/19.0% after 5/10/15 years and for T3 tumors 25% after 5/10 years. Mendenhall therefore recommends a radiation dose of 70 Gy for larger tumors and 60-70 Gy for smaller ones [\[473\]](#). Lansbury comes to similar conclusions in a meta-analysis comprising 14 mostly retrospective studies on 1018 primary irradiated patients with cutaneous SCC [\[400\]](#). For studies with a median observation time of 2 to 5 years, he reports a median recurrence rate of 6.1%.

The extent to which simultaneous chemotherapy can increase the efficacy of primary radiotherapy in large or initially lymphogenically metastatic tumors has not been clarified in large patient collectives with cutaneous SCC.

An approach analogous to the treatment of advanced mucosal SCC has been described in the literature [\[470\]](#), [\[471\]](#). For example, Nottage reports 21 patients who received primary irradiation (total dose 70 Gy, single dose 2 Gy) and simultaneous chemotherapy (cisplatin 40 mg/m² or carboplatin AUC2 weekly) in a prospective phase II study. Of 19 evaluable patients, 10 developed complete remission and 2 tumors were operable after radiochemotherapy and could be completely resected [\[472\]](#). Tanvetyanon et al. reported in 67 patients that adjuvant radiochemotherapy with cisplatin significantly reduced the risk of recurrence in a multivariable analysis: Hazard ratio (HR) 0.31. However, no difference in overall survival was observed [\[474\]](#). For a very small patient population with recurrent tumors, Sharon reports the possibility of alternative therapy with antibodies (cetuximab) concurrent with radiotherapy in addition to platinum-based chemotherapy [\[468\]](#). Radiotherapy with either concurrent platinum or cetuximab appears to offer similar clinical outcomes in patients with locally advanced cutaneous SCC of the head and neck.

8.11	Evidence-based recommendation	checked 2022
GoR B	Postoperative radiotherapy should be performed for: <ul style="list-style-type: none"> • R1 or R2 resection (if further resection is not possible). • Extensive lymph node involvement (>1 affected lymph node, lymph node metastasis >3 cm, capsule rupture) • Intraparotid lymph node involvement 	
LoE 2	[475], [476], [99], [361], [363], [469], [474], [477], [478], [479], [480] 2: De novo research	
	Strong consensus	

8.12	Evidence-based recommendation	modified 2022
GoR B	Adjuvant radiotherapy should be performed in the presence of extensive perineural sheath infiltration.	
LoE 2	[475], [476], [99], [361], [363], [469], [474], [477], [478], [479], [480] 2: De novo research	
	Strong consensus	

8.13	Evidence-based recommendation	modified 2022
GoR 0	Adjuvant radiotherapy may be considered if the resection margin is close.	
LoE 2	[475], [476], [99], [361], [363], [469], [474], [477], [478], [479], [480] 2: De novo research	
	Strong consensus	

8.14	Evidence-based statement	new 2022
LoE 2	Current data do not support a recommendation for combining adjuvant radiotherapy with systemic therapy.	
	[481] , [482] , [483] 2: De novo research	
	Strong consensus	

For the following revision as part of the 2020/2021 guideline update, a systematic update search was performed for the period of January 2017 to May 2021. Systematic reviews, randomized trials, and case series > 200 patients were included.

General postoperative radiotherapy for cutaneous SCC is not indicated but should be offered only in the presence of risk factors for local or locoregional recurrence. Risk factors, some of which are discussed in contradictory fashion in the literature, include R1 or R2 resection, narrow resection margin (<2 mm in the absence of the option of resection), recurrent tumor, maximum tumor size (>2 cm), maximum penetration depth (>4 mm), infiltration of adipose tissue, PNI, and extensive lymphogenic involvement (>1 affected lymph node, capsular rupture) [\[360\]](#), [\[478\]](#), [\[363\]](#), [\[484\]](#), [\[356\]](#), [\[474\]](#), [\[477\]](#), [\[361\]](#), [\[485\]](#).

A recent systematic review with meta-analysis considered the impact of postoperative radiotherapy in patients with cutaneous SCC (n=2605 patients, n=20 studies) [\[475\]](#). Adjuvant radiotherapy achieved significant improvements in overall survival (OR 2.94; 95% CI, 1.75-4.91; p<0.0001), disease-free survival (OR 2.17; 95% CI, 1.23-3.83; p=0.008), and recurrence rate (OR 0.56; 95% CI, 0.36-0.85; p=0.006). In the subgroup of patients with free incision margins, postoperative radiotherapy resulted in improved disease-free survival (OR 2.53; 95% CI 1.24-5.14; p=0.01); overall survival was not analyzed. In the overall population, multivariate analysis of risk factors for overall survival identified the following significant factors: Use of radiotherapy (improvement with HR 0.47; 95% CI, 0.34-0.65; p<0.00001) as well as PNI (HR 1.61; 95% CI, 1.24-2.09; p=0.0004), positive incision margins (HR 2.34; 95% CI 0.34-0.65; p=0.0008) and immunosuppression (HR 3.02; 95% CI 2.14-4.25; p<0.00001) [\[475\]](#).

Another systematic review with meta-analysis evaluated the value of postoperative radiotherapy in patients with cutaneous SCC of the head and neck region and regional lymph node metastasis (n=3534 patients from 20 observational studies and one randomized trial) [\[476\]](#). Adjuvant radiotherapy was significantly associated with improved overall survival in the meta-analysis (HR 0.45, 95% CI 0.26-0.78; p=0.005), while immunosuppression (HR 2.66, 95% CI 2.26-3.13; p<0.0001), capsular rupture (HR 1.90, 95% CI 1.12-3.22; p=0.02), the proportion of affected lymph nodes (HR 1.91, 95% CI 1.09-3.35; p=0.02) and age (HR 1.03, 95% CI 1.00-1.07; p=0.05) were determined. The use of postoperative radiotherapy was also associated with improved disease-specific survival (HR 0.52, 95% CI 0.33-0.84; p=0.008).

Postoperative radiotherapy after R1 or R2 resection and after close resection (<2 mm) without the possibility of resection is considered mandatory [\[363\]](#), [\[356\]](#), [\[99\]](#), [\[474\]](#), [\[477\]](#). A meta-analysis did not find different local recurrence rates between surgery

alone and surgery and postoperative radiotherapy for close or unclear resection margins. However, the authors inferred the effectiveness of postoperative radiotherapy based on the fact that recurrence rates were the same for both treatment modalities, although the irradiated patients had larger tumors [363]. Therefore, Veness recommends radiotherapy with a total dose of 50-60 Gy in this situation [477]. There is no literature indicating maximum tumor size or infiltration depth as mandatory indications for postoperative radiotherapy. Therefore, both risk factors must be considered optional and may be used in terms of an individual decision if necessary. Although no prospective studies on PNI as an indication for postoperative radiotherapy are available, 2 reviews and 3 other publications indicate that the local recurrence risk in PNI can be reduced by postoperative radiotherapy [360], [478], [363], [99], [361], [485]. The extent of infiltration and the size of the infiltrated nerve are important. Han reports local control rates of 78-87% for microscopic PNI, 50-55% for macroscopic PNI, while after postoperative radiotherapy local control was 100% in selected patients [478]. In the presence of extensive involvement of the cervical lymph nodes (>1 affected lymph node, lymph node metastasis >3cm, capsular rupture), postoperative radiotherapy is mandatory [486], [487], [437], [488], [480], [449], [479]. This not only improves the local recurrence rate [487], [437], [488], [480], [449], [479] and disease-free survival [480], [449] but also improves overall survival [437], [488], [480], [449], [479]. In a 122-patient retrospective study, the local recurrence rate, 5-year disease-free survival, and overall survival were 55%, 34%, and 27% for patients operated on alone and 23%, 74%, and 66% for those additionally irradiated postoperatively [479]. The irradiation dose ranged from 50 to 60 Gy [437]. A special situation exists in intraparotid lymph node metastases, as postoperative radiotherapy is always recommended here [489], [490]. Literature references on the procedure for lymph node metastases of the axilla and inguinal region are sparse and are essentially based on the indication for postoperative radiotherapy in the neck region [489].

On the question of the role of postoperative radiochemotherapy in the presence of risk factors, the randomized phase III trial TROG 05.01, which included n=310 patients with macroscopically completely resected (R0 or R1) high-risk cutaneous SCC of the head and neck region according to the following criteria: Presence of intraparotid lymph node metastasis or lymph node metastasis with at least one of the criteria (≥ 2 lymph nodes or capsule rupture or largest lymph node > 3cm) or advanced primary tumor (> 5cm or T4 or in-transit metastasis) [481]. Postoperative radiotherapy 60-66 Gy was compared with radiochemotherapy 60-66 Gy with carboplatin weekly AUC 2 (maximum 6 doses). The primary endpoint of freedom from locoregional recurrence showed no advantage of radiochemotherapy, being 83% for radiotherapy alone and 87% for radiochemotherapy at 5 years (HR 0.84, 95% CI 0.46-1.55; p=0.58). The 5-year overall survival was also comparable, being 76% for radiotherapy and 79% for radiochemotherapy (HR 0.95, 95% CI 0.58-1.57) [481].

A 2019 review also showed no benefit in adding carboplatin as part of adjuvant radiotherapy to preoperated patients compared with single radiotherapy. A retrospective analysis of 104 patients with locally advanced cutaneous SCC who had already undergone surgery including parotidectomy and neck dissection found no significant difference in recurrence-free survival between radiochemotherapy vs. radiotherapy with a 2-year disease-free survival of 65% vs. 58% (p=0.43) [482].

In a propensity score-matched analysis, the effect of combining postoperative radiotherapy with cetuximab for high-risk cutaneous SCC (poorly differentiated, PNI, lymphovascular invasion, positive incision margin, lymph node involvement,

recurrence, immunosuppression, or ear/cheek/lip localization) of the head and neck region was considered (n=68) [483]. Both 5-year overall survival (80% vs. 61%) and 5-year progression-free survival (66% vs. 29%) were favorable for the cetuximab group, but the differences were not significant.

In summary, multiple studies with heterogeneous and sometimes very small patient populations show no or no statistically significant benefit for platinum-based chemotherapies in combination with radiotherapy in terms of overall survival, disease-specific survival, and relapse-free survival compared with radiotherapy alone. The use of EGFR receptor antagonists in combination with radiotherapy should be discussed especially in patients who have contraindications to the use of checkpoint inhibitors and an increased risk of local recurrence and metastasis such as organ transplanted patients.

The combination of checkpoint inhibitors and radiotherapy has been poorly studied in cutaneous SCC. Several clinical trials are currently evaluating the use of this therapeutic option in adjuvant setting using different checkpoint inhibitors. Results of these studies must await future therapeutic recommendations.

In local or locoregional recurrence, the same criteria for indication for postoperative radiotherapy apply as in the primary situation [491].

8.7 Therapy of local or locoregional recurrence

8.15	Consensus-based recommendation	checked 2022
EC	Locoregional recurrences shall be surgically removed if clinically possible.	
	Strong consensus	

8.16	Evidence-based recommendation	checked 2022
GoR A	Micrographically controlled surgery (MCS) shall be applied.	
LoE 2	[99] , [350] , [361] , [363] , [469] , [474] , [478] , [479] , [480] , [488] , [490] , [491] , [359] 2: De novo research	
	Strong consensus	

8.17	Evidence-based recommendation	checked 2022
GoR B	If a R1 or R2 situation that cannot be further resected arises during the course of resection, postoperative radiotherapy should be performed at the R1 or R2 localization (see Chapter 8.6).	
LoE 2	[350] , [488] , [490] , [491] , [359] 2: De novo research	
	Strong consensus	

8.18	Evidence-based recommendation	checked 2022
GoR B	In case of interdisciplinary determined inoperability, radiotherapy should be performed (see Chapter 8.6).	
LoE 3	[350] , [488] , [490] , [491] , [359] 3: De novo research	
	Strong consensus	

8.19	Consensus-based recommendation	checked 2022
EC	For therapy of local or locoregional recurrence, the indication for electrochemotherapy or systemic therapy should be considered if surgical or radiotherapeutic options are not available.	
	Consensus	

Local recurrences often have more extensive, irregular subclinical infiltration than primary tumors, which is inadequately detected by bread loafing histology. Desmoplastic SCC recur more frequently despite use of a gapless MCS [359], [350]. Death from local infiltration is not uncommon in this type [20]. Thus, in case of recurrence after MCS after surgical therapy, postoperative irradiation is recommended. Overall, according to the literature, postirradiation reduces the recurrence rate and achieves longer recurrence-free survival compared with surgical therapy alone [478], [363], [469], [99], [474], [477], [480], [479], [361].

If inoperability is present and radiatio is not possible, electrochemotherapy can be given to improve local tumor control; the response rate has been reported to be 46% [492], [493], [494]. Furthermore, it can be evaluated whether systemic therapy is possible (see [Chapter 8.8](#)).

8.8 Therapy in the advanced (locally advanced or metastasized) stage

8.8.1 Indication for systemic therapy

8.20	Consensus-based recommendation	new 2022
EC	In case of (distant) metastasis or locally advanced disease that cannot be controlled by surgical or radiotherapeutic interventions or only with major limitations of functionality, the indication for systemic therapy shall be considered.	
	Strong consensus	

8.21	Consensus-based recommendation	new 2022
EC	The indication for systemic therapy should be made in an interdisciplinary tumor board.	
	Consensus	

There is an international consensus that metastatic skin tumor diseases in general and advanced cutaneous SCC in particular should be discussed in an interdisciplinary tumor board.

The possibility of inclusion in clinical trials should be considered in all cases.

While distant metastasis is clearly defined by radiological criteria (RECIST) on imaging, the definition of "locally advanced SCC" disease is more difficult. In the clinical trials for approval of the PD-1 antibodies cemiplimab (REGN-1540) or pembrolizumab (KEYNOTE-630), study inclusion was only possible if an interdisciplinary tumor board had discussed potential patients. Only if no curative option (surgery or radiotherapy) was seen in the tumor board or if this could only be performed with major limitations in functionality, study inclusion was possible. Most importantly, the usefulness of surgery versus the prospects of systemic therapy should be carefully weighed.

However, an internationally accepted definition of locally advanced SCC disease does not exist to date. Recently, the European Association of Dermato-Oncology presented a subdivision of advanced basal cell carcinoma, which distinguishes 5 subgroups. The German guideline for basal cell carcinoma contains a term definition for the "locally advanced disease" as well. In the context of a SCC data collection the EADO is currently working on a similar international expert consensus for advanced SCC.

In summary, every patient with distant metastatic or locally advanced SCC should present to an interdisciplinary skin tumor board and the local and systemic therapy options should be carefully weighed in terms of benefits and risks. Inclusion in a clinical trial should always be considered.

8.8.2 Implementation of systemic therapy

8.22	Consensus-based recommendation	new 2022
EC	Patients with locally advanced or metastatic SCC shall be offered first-line immunotherapy with a PD-1-inhibitor approved for this indication.	
	Strong consensus	

8.23	Consensus-based recommendation	new 2022
EC	In case of progression under PD-1-blockade or contraindications to this type of immunotherapy, EGFR-directed therapy or chemotherapy shall be offered.	
	Strong consensus	

If there is an indication for systemic therapy, then the best data is available for PD1 inhibitors from, however, only uncontrolled studies (see [Table 36](#)). SCC have a very high mutation burden [\[495\]](#), which are associated with a response to PD1 inhibitors in other tumor entities. Data with the PD1 antibody cemiplimab and pembrolizumab (see [Table 36](#)) show response rates of 41-50%, median duration of response was not reached after a median follow-up of 8.1-22.4 months (see [Table 36](#)).

A retrospective monocentric case series from the University Dermatology Clinic in Tübingen, Germany, included 57 patients with advanced SCC who had received systemic therapy [496]. When overall survival of 20 patients who had received immunotherapy at any time point was compared with 37 patients who had not received immunotherapy but had received chemotherapy and/or EGFR inhibitor, there was a significant advantage for the patients with immunotherapy. This suggests that immunotherapy may be beneficial in terms of overall survival.

Another retrospective case series of 6 German skin tumor centers reported 46 patients with advanced SCC who had received a PD1 inhibitor [497]. The response rate was 58.7% and was independent of whether there was a locally advanced or metastatic stage. Median PFS and OS were not reached, and PFS at 12 months was 58.8%. Unfavorable factors for benefit from checkpoint blockade included elevated LDH and localization of the primary tumor to the legs.

In summary, the response rate of PD1 inhibitors appears to be higher in patients with advanced SCC on chronically light-damaged skin (with high mutation burden) without pretreatment, whereas pretreatment and primary tumors on non-light-exposed skin (with lower mutation burden) show lower response rates.

Table 36: Ongoing therapeutic trials with the use of PD1 blockers in cutaneous SCC (FUI = follow-up interval)

Therapy	Line	Study phase	Number of evaluable patients	Median re-sponse duration (months)	Response rates	Reference
Cemiplimab	Any	1	26	Not reached (median FUI 11.1 months)	50%	Migden et al., 2018 [498]
Cemiplimab (cohort 1, weight-adjusted dose every 2 weeks)	Any	2	59 (with metastases)	Not reached (median FUI 16.5 months).	49.2%	Migden et al., 2018 [498] Rischin et al., 2020 [499]
Cemiplimab (Cohort 2, weight-adjusted dose every 2 weeks)	Any	2	78 (locally advanced)	Not reached (median FUI 9.3 months)	44%	Migden et al., 2020 [500]

Therapy	Line	Study phase	Number of evaluable patients	Median re-sponse duration (months)	Response rates	Reference
Cemiplimab (Cohort 3, fixed dose every 3 weeks)	Any	2	56 (with metastases)	Not reached (median FUI 8.1 months)	41.1%	Rischin et al., 2020 [499]
Pembrolizumab (CARSKIN)	1.	2	39	Not reached (median FUI 22.4 months)	41%	Maubec et al., 2020 [501]
Pembrolizumab	Any	2	29			NCT02964559
Pembrolizumab + radiotherapy	Postoperative adjuvant	2	37			NCT03057613
Pembrolizumab (Keynote 629)	Any	2	105	Not reached (median FUI 11.4 months)	34%	Grob et al., 2020 [502]

In addition to studies on PD-1 inhibitors, there are mostly older data for various chemotherapies and EGFR inhibitors.

A systematic review published in 2011 on systems therapy for locally advanced cutaneous SCC summarized 28 studies with 119 patients published from 1970-2011 [\[503\]](#). It became clear as an important limitation that there are only uncontrolled studies with few patients on this question, the „level of evidence“ was rated 2-3 (2=randomized trial or (exceptionally) observational study; 3=non-randomized controlled cohort/follow-up study, Non-randomized controlled cohort/follow-up study) and corresponds to a recommendation B (corresponding level 2 or 3 studies) or C (level 4 studies or extrapolation of level 2 or 3 studies). Therefore, the efficiency data are subject to (strong) uncertainties. Across therapies, a median time to response of 9 weeks was seen with an overall response rate of 72% and a median duration of response of 42 weeks.

In a retrospective case series published in 2018, a total of 190 patients with advanced SCC from 2010 and 2011 were documented in 24 German and Austrian centers [\[504\]](#). 78 patients had locally advanced SCC, and 114 patients had metastatic SCC. 32

patients received systemic therapy, using various chemotherapeutic agents and EGFR inhibitors alone or in combination. The response rate was 26%, and the median duration of response was 5 months.

Table 37: Therapeutic studies on the use of chemotherapeutic agents, interferon alpha, and 13-cis retinoic acid in cutaneous SCC

Therapy	Line	Study phase	Number of evaluable patients	Median response duration (months)	Response rates	Reference
Cisplatin + doxorubicin	Partly neoadjuvant	2	12	8.6	58%	Guthrie et al., 1990 [505]
cisplatin + 5-fluorouracil + bleomycin	pre-treated	2	13	11.7	84%	Sadek et al., 1990 [506]
Cisplatin + 5-fluorouracil	1.	2	7	11.8	86%	Khansur et al., 1991 [507]
Oral 5-fluorouracil	1.	2	15	30	14%	Cartei et al., 2000 [508]
Interferon alpha + 13-cis retinoic acid	1.	2	28	5	68%	Lippman et al., 1992 [509]
Interferon alpha+ 13-cis retinoic acid+ cisplatin	1.	2	35	9	34%	Shin et al., 2001 [510]
70 Gray radiotherapy +carboplatin	1, only locally advanced, incl. regional lymph node metastases	2	19	Not reported	100% (53% complete remission)	Nottage et al., 2017 [472]

With the above limitations, SCC is chemosensitive with response rates >50% to platinum-based chemotherapy. However, a possible bias regarding the publication of successful treatments should always be considered here. Response rates are higher with poly-chemotherapy or radiochemotherapy. However, the duration of response is often unclear and increased toxicity is to be expected especially with the mentioned poly-chemotherapy regimens.

A retrospective case series investigated isolated limb perfusion for unresectable SCC [511]. In 21 patients, the leg was perfused with melphalan, in 9 patients the arm, in 2 patients additionally with TNF α . Of 27 evaluable patients, 16 (59%) showed complete remission, 6 (22%) partial remission, and 5 (19%) progressive disease. 7 patients with response developed relapse or re-progression during the course after a median of 9 months. Thus, isolated limb perfusion could be a therapeutic option in appropriate tumor location.

Regarding monotherapy with EGFR inhibitors (see Table 36), response rates range from 25% to 45%, with a median response duration of a few months (progression-free survival: approximately 4 months, overall survival approximately 8 months). High response rates have been reported for the combination of cetuximab and radiotherapy. One publication summarized 8 patients of our own and 24 patients from the literature [512]. 29 of the 34 patients responded to therapy. However, this raises the question of the extent to which this result would not have been achieved with radiotherapy alone or whether the additional cetuximab administration was necessary. Another retrospective study compared the use of radiotherapy plus cetuximab vs. radiotherapy plus platinum-containing chemotherapy and showed similar therapeutic success in both arms [468].

Table 38: Therapeutic studies with the use of EGFR blockers in cutaneous SCC

Therapy	Line	Study phase	Number of evaluable patients	Median response duration (months)	Response rates	Reference
Cetuximab	1.	2	36	6.8	28%	Maubec et al., 2011 [513]
Panitumumab	1/2	2	16	6	31%	Foote et al., 2014 [514]
Gefitinib	Neo-adjuvant	2	22	Not reported	45%	Lewis et al., 2012 [515]
Erlotinib + radiotherapy	1	1	15	Not reported	Not reported	Heath et al., 2013 [516]
Lapatinib	Neo-adjuvant	1	8	Not reported	25%	Jenni et al., 2016 [517]
Dacomitinib	1./2.	2	42	10.3	28%	Cavalieri et al., Eur J Cancer 2018. [518]
Erlotinib	1./2.	2	29	5.3	10%	Gold et al., Cancer 2018 [519]

A special feature of patients with advanced or metastatic SCC is that they are often elderly patients with relevant comorbidities; for example, chronic lymphocytic leukemia is a risk factor for rapid progression of SCC. A retrospective study was able to show that PD1-targeted checkpoint blockade can also be promising in patients with hematologic neoplasms, although here the efficiency seems to be lower than in patients without secondary hematologic disease [\[520\]](#).

Irrespective of age, patients with post organ transplant condition with associated iatrogenic immunosuppression should be mentioned. While in renal transplant recipients conversion of immunosuppression to an mTOR-containing regimen had a positive effect in primary and secondary prevention of new epithelial skin tumors in several studies, the effect of conversion to mTOR inhibitors in manifest epithelial skin tumors is unclear [\[521\]](#), [\[522\]](#), [\[523\]](#), [\[524\]](#). In unresectable or metastatic SCC, PD1

checkpoint inhibition can also be discussed, but there is a risk of organ rejection [525].

In summary, currently in SCC with an indication for systemic therapy, immunotherapy with a PD1 inhibitor should be performed if inclusion in a clinical trial is not possible. A number of clinical trials are currently ongoing, e.g., with combinations of checkpoint blockade and EGFR blockade (avelumab + cetuximab, AliCe trial, EUDRACT number 2018-001708-12). In case of disease progression under immunotherapy or contraindications to immunotherapy, the indication of chemotherapy or EGFR-targeted therapy should be evaluated. Schemes following therapies for mucosal SCC (HNSCC) or oral cavity carcinoma may also apply [425], [526], [527] such as cetuximab plus platinum derivative [528].

8.9 Palliative care

For patients with advanced SCC, communication on palliation, presentation of possible treatment concepts, and agreement on realistic goals are essential. Care structures close and suitable to the patient are to be elicited.

Loss of function due to tumor growth, limited mobility and stigmatization must be taken into account. Malignant decaying tumors affect 5-14% of tumor patients. Tumor ulceration, necrosis and superinfection cause additional psychological distress [529]. Microbial colonization is favored by tumor decay. Exudate, bleeding, fetor become a burden [379]. Local measures can be used to flank antitumorally [530], [531].

Palliative care is defined as an approach to improve the quality of life of patients and their families facing problems associated with life-threatening disease. This is done by preventing and relieving suffering through early recognition, careful assessment, and treatment of pain and other problems of a physical, psychosocial, and spiritual nature. Regarding palliative care aspects, regardless of the underlying diagnosis, reference is made to the expanded S3 guideline on palliative care by the German Guideline Program in Oncology [532].

Patients with incurable SCC require palliative care; this includes pain therapy and often wound management. Nutrition and gastrointestinal symptoms including weight loss, sleep disturbances, fatigue, and physical weakness are other associated and common topics [379], [533], [532]. Depending on tumor location, tumor size, and the extent of the disease, other physical and psychological problems may be added. Psycho-oncology care addresses psychological, social, and spiritual conflicts. Fears and uncertainties about the course of the disease and dying can be addressed in a timely and worry-reducing manner in communication.

Physical limitations and problems as well as psychosocial concerns, prevention of complications and preservation of quality of life are the focus. Patient wishes are to be taken into account in consultation with their relatives. Multi-professional and interdisciplinary management should be initiated in a timely manner.

9 Follow-up and prevention

U. Leiter, S. El Gammal, K. Fritz, A. Hauschild, S.M. John, P. Mohr, Ch. Pfannenberger

9.1 Examinations within the framework of aftercare

9.1	Consensus-based recommendation			modified 2022
EC	Follow-up for patients with SCC of the skin should be offered at risk-adjusted intervals according to the following schedule:			
		Year 1-2	Year 3-5	Year 6-10
	Primary tumor stage			
	Low risk	6-monthly	Yearly	-
	High risk	3-monthly	6-monthly	annually
	Immunocompromised patients	3-monthly	3-6 monthly	3-6 monthly according to risk profile
	Advanced stages			
Locally advanced/ metastatic	3-monthly (up to and including year 3)	3-6 monthly (year 4-5)	6 monthly/annually	
Strong consensus				

The question of the intervals at which follow-up care should be performed must be considered in a differentiated manner with regard to the individual goals of regulated follow-up care.

- Early detection of local recurrences or metastases
- The early detection of further SCC and its precursors

Here, the conditions and results of a clinical or apparative metastasis diagnosis are most subject to temporal and stage-dependent influences. General boundary conditions can be formulated for the early detection of second tumors.

9.1.1 Examination intervals for early detection of metastasis

The question of whether targeted metastasis diagnostics can be used to improve lethality, morbidity, and quality of life of affected patients plays a significant role in the question of appropriate examination intervals. However, no data are available in

SCC on the extent to which outcomes can be influenced by different follow-up regimens.

What is significant here is how much risk of recurrence a patient is judged to be under at any given time. Based on their data on recurrence frequency, McCarthy et al. in 1988 created a general model calculation and calculation basis for examination intervals to be aimed for [534]. These are based on two assumptions:

- The relative rate of recurrence detected by follow-up is at least 50% (compared with events detected by the patient or symptoms or incidental findings).
- The theoretical probability of not detecting a metastatic event through missed follow-up should not exceed 1%.

These conditions lead to breaking down follow-up examinations to intervals in which the calculated probability of metastasis is no more than 2 percent. The consideration of what the minimum probability of metastasis should be for follow-up to still be considered reasonable is not addressed. The question of when the risk of metastasis can be considered significantly high for an intensified follow-up regimen would in principle also have to be based on cost-benefit evaluations, about which, however, no publications are available.

9.1.2 Risk-adapted intervals according to stages

The need to differentiate both the follow-up intervals and the type and extent of the recommended examinations by stage arises both from the cumulative recurrence risks for the individual stages and from their temporal progression.

To avoid "overindividualization" of follow-up, most recommendations [355], [440], [99], [535] target two risk groups, low and high metastatic risk, respectively.

Generally, the term follow-up is applied to patients with clinical tumor freedom. These are usually patients with completely surgically resected primary tumors and/or locoregional metastases. In principle, however, these could also be distant metastases that have been resected or are in complete remission due to other methods (radiation, drug therapy), although this is very rare in SCC. In the case of a recurrence of SCC as a second malignancy, follow-up care starts anew each time, so that it may be lifelong.

The aim of a classification into risk groups is a consistent and well discriminating grading on the basis of relevant prognostic parameters.

As with other solid tumors, SCC staging currently includes four clinical stages, I (early primary tumors), II (advanced primary tumors), III (locoregional metastasis), and IV (distant metastasis). The current AJCC 2010 classification [536] applies to SCC except those in the neck-head region. This classification does not map the risk of metastasis. Risk factors such as immunosuppression, which cause a significantly worse prognosis, are not mapped:

- Tumors with poor prognosis are predominantly classified into low tumor stages
- Stage T4 tumors rarely metastasize
- T3 and T4 tumors according to AJCC 2010 show similar survival rates [339]

- T2 tumors have the worst prognosis [\[339\]](#)

Thus, there is an overlap of stages that should be considered in the definition of the follow-up recommendation.

For SCC in the neck-head region, there is a classification according to AJCC 2017 that better reflects risk factors such as tumor thickness >6 mm and PNI. These tumors are classified as T3 and assigned to stage III.

9.1.3 Explanation of the recommendation

In order to detect recurrences and second tumors of SCC at an early stage, a risk-adapted follow-up is recommended.

The following factors are considered prognostic for metastasis or disease-specific survival in cutaneous SCC: vertical tumor thickness (>6 mm), horizontal tumor thickness (≥ 2 cm), histologic differentiation (> grade 3), desmoplasia, perineural growth, localization (lower lip, ear), and immunosuppression (iatrogenic or disease-related).

Because approximately 80% of recurrences occur within the first 2 years after primary diagnosis, intensified follow-up is advocated for this period. Most recurrences (69%) occurred within the first year after primary diagnosis, 84% within the first 2 years, and 91% in years 1-3. Local recurrences occurred 75% within 2 years and 83% within 3 years after primary diagnosis, but not after more than 6 years [\[19\]](#), [\[347\]](#). In cervical SCC, the vast majority of parotid metastases arise within the first 2 years after diagnosis. Close sonographic examination of parotid and cervical lymph nodes is required in high-risk patients, especially in the first 2 years after diagnosis of skin carcinoma, for timely diagnosis of locoregional metastases [\[355\]](#), [\[440\]](#), [\[99\]](#), [\[107\]](#).

Therefore, patients should be followed up closely in years 1-2 after primary diagnosis. This is especially true for patients at high risk of recurrence such as patients with immunosuppression, organ transplantation, and multiple tumors.

Intensified follow-up includes three-monthly screening intervals. The individual follow-up examinations can be performed with different diagnostic methods according to the risk. As risk decreases, follow-up intervals can be extended beyond a 6-month interval to 1-year intervals.

Low-risk patients may not require long-term follow-up.

Because the independent prognostic effect of high-risk factors has not been consistently reported, follow-up should be based on individual risk assessment and tumor- and patient-related characteristics, with particular attention to patients with more than one risk factor.

In patients with locally advanced or metastatic SCC and after surgery for locoregional metastases, follow-up examinations should be performed every 3 months for the first 5 years and every 6 months thereafter [\[379\]](#).

In patients at high risk for other primary tumors (immunosuppression, hematologic comorbidities, genetic predisposition, prior multiple SCC), close follow-up, every 3 months for the first 5 years and every six months thereafter for life, is recommended, depending on the total number and frequency of development of new tumors [\[379\]](#).

Follow-up of patients with occupational skin tumors (BK5103) is based on the prognostic factors of the leading SCC.

Education and detailed instructions for self-examination are basic components of follow-up. According to available data, the reassuring aspect of a negative examination result is also of particular importance in the psychosocial support of tumor-free patients. No specific intervals of a regulated aftercare are derived from this in the literature [537]. With regard to psychosocial support, it seems plausible to offer at least four appointments in the first two years after diagnosis, even in early stages, in order to meet the support needs of patients.

9.1.4 Examination intervals for the early detection of secondary squamous cell carcinoma of the skin

It is estimated that 30-50% of subsequent SCCs occur within 1 year of diagnosis of the primary tumor [535] the risk of which is highest within the first 4 years after primary diagnosis but is still significantly increased after 15 years of follow-up (SIR 3.0; 95% CI 2.5-3.6) [535]. A cohort study from the United States of 1,426 patients showed 5- and 10-year risks of developing another SCC of 42.1 and 69.1%, respectively [538]. The development of independent second tumors are common problems, especially in high-risk patients. These include patients with field cancerization on the face, hands, and capillitium, and with chronic immunosuppression after organ transplantation [539], [29].

This also speaks for a close-meshed control in the first years after primary diagnosis. The aim here is to detect and treat secondary SCC at an early stage. Secondary prevention of SCC also includes early treatment of precursor lesions such as AK.

9.1.5 Investigational methods in the follow-up of invasive squamous cell carcinoma

9.2	Consensus-based statement							new 2022		
EC	The following examination methods are recommended depending on risk factors of the primary tumor, immunosuppression or after locally advanced and metastatic squamous cell carcinoma of the skin according to the present scheme:									
	Stage	Physical examination			Lymph node sonography			Imaging examinations CT, MRI, PET-CT		
	Year	1-2	3-5	6-10	1-2	3-5	6-10	1-3	4-5	6-10
	Primary tumors Low risk	2x	1x	-	0-2x	-	-	-	-	-
	High risk	4x	2x	1x	1-4x***	0-2x***	-	0-2x**	-	-
	Immunosuppressed patients	4x	2-4x	2-4x	1-4x***	0-2x***	-	0-2x**	-	-
	Locally advanced / metastasized	4x	4x	2-4x	4x	2x	-	2x	-	-
<p>*for R0 resected stages, Low risk: TD ≤6mm, ≤4mm for desmoplasia, G1-2 differentiation, High risk, TD > 6mm, >4mm for desmoplasia, G3-4 differentiation, perineural tumor growth, immunosuppressed and patients with secondary tumors, see question I.3. ** in case of perineural tumor growth *** depending on risk factors</p>										
Consensus										

9.1.5.1 Clinical examination

9.3	Consensus-based recommendation	checked 2022
EC	Clinical examination shall be performed regularly in all patients after squamous cell carcinoma of the skin as part of follow-up and shall include inspection of the entire skin organ and inspection and palpation of the primary tumor site, in-transit area, and regional lymph nodes.	
Strong consensus		

If and as long as tumor follow-up in the closer sense is required, whole-body inspection for the detection of secondary SCC, local recurrence and metastases will

fulfill this task as an integral part of follow-up. This includes a focused history, inspection of the entire integument, and palpation of the primary scar, in-transit and lymphatic drainage areas, and lymph node stations. At the beginning of follow-up, this should be supplemented with guidance on self-examination and preventive measures [\[355\]](#), [\[356\]](#), [\[99\]](#).

Early detection of recurrences during follow-up benefits especially those patients in whom complete surgical removal of the filiae is possible. Local recurrences and secondary SCC are predominantly found on physical examination, but for the detection of lymph node metastases in the head and neck region, clinical examination is inferior to lymph node sonography [\[107\]](#).

9.1.5.2 Lymph node sonography

9.4	Consensus-based recommendation	modified 2022
EC	<p>Lymph node ultrasonography should be performed in patients at high risk of metastasis* or with unclear palpation findings and in cases of locally advanced and metastatic SCC of the skin.</p> <p>*High risk: TD >6mm, >4mm in desmoplasia, G3-4 differentiation, perineural tumor growth, immunosuppressed and patients with secondary tumors.</p>	
	Strong consensus	

Sonography includes sonography of the excisional scar of the primarius, the in-transit road, and the locoregional lymph node area and other stations as appropriate. Metastases of SCC occur locoregionally as satellite, in-transit, or locoregional lymph node metastases in approximately 80% of cases; locoregional filiae detected early have the option of R0 resection. Therefore, early detection of locoregional lymph node filiae is of particular importance.

For staging of parotidal and cervical lymph nodes in SCC in the neck-head region, sonography is considered the method of choice and is clearly superior to clinical examination by palpation for staging and timely diagnosis of lymph node metastases [\[107\]](#). Compared with MRI, LN sonography shows similar values for sensitivity and specificity (66% and 78%, respectively) [\[108\]](#). In cases of sonographic suspicion of the presence of parotidal and cervical metastases, staging should be supplemented by fine-needle cytology of the suspicious lymph nodes, CT scan of the neck and thorax, and MRI of the parotid gland.

In the case of tumors with an increased risk of metastasis (from tumor thickness >5 mm, grade 3 differentiation, in immunosuppressed patients), lymph node ultrasonography is recommended at 3- to 6-month intervals. In locally advanced tumors or locoregional metastases, LN ultrasonography is recommended at 3-month intervals on a regular basis, otherwise in case of unclear findings [\[355\]](#), [\[379\]](#), [\[107\]](#), [\[440\]](#).

In a meta-analysis of 74 studies, LN ultrasonography, which is cost-effective compared with cross-sectional imaging, was the procedure with the highest sensitivity and specificity for detecting locoregional lymph node filiae in melanoma [\[540\]](#). LN sonography is superior to palpation in this regard [\[541\]](#). LN

ultrasonography is also described in the diagnosis of HNSCC as the most effective procedure with the highest positive predictive value to detect locoregional lymph node metastases or shows a sensitivity of about 75% and specificity of 85% [105], [109].

In a meta-analysis comparing different imaging modalities (ultrasound, CT, MRI, PET) in lymph node diagnosis in clinically N0 HNSCC, the positive predictive value for lymph node ultrasonography was 25% to 56%, the negative predictive value was 95% to 84%, and lymph node ultrasonography was equivalent to the other modalities in accuracy [108]. An increase in diagnostic specificity can be achieved by sonographically guided fine needle aspiration of suspicious lymph nodes [105]. Lymph node ultrasonography also proved to be at least equivalent in detecting occult lymph node metastases from HNSCC tumors when compared with FDG-PET/CT and software-based fusion PET/MRI (plus DWI), although published PET data often refer to studies with inhomogeneous collectives (N-/N+) with varying levels of evidence [109], [542], [543].

Studies on sensitivity and specificity in the diagnosis of lymph node metastases from cutaneous SCC are not available.

9.1.5.3 Chest X-ray and abdominal sonography

9.5	Consensus-based recommendation	modified 2022
EC	Chest X-ray examinations and abdominal ultrasonography should not be routinely performed during follow-up.	
	Strong consensus	

Chest X-ray examinations are clearly inferior to chest CT in the detection of small pulmonary filiae [544], [111]. A problem with chest X-ray examinations is the high number of false positive and false negative findings. Chest X-ray examinations detect only 28-60% of pulmonary metastases diagnosed on chest CT.

Abdominal ultrasonography can detect parenchymal distant metastases and abdominal lymph node metastases, e.g., in perianal SCC or Bowen's carcinoma in the genital area, but the diagnostic accuracy is examiner- and patient-dependent and overall lower than that of MRI, CT, and PET/CT. Limitations arise particularly in the diagnosis of deep-seated structures (e.g., retroperitoneal lymph nodes) and in obese patients. An advantage of abdominal ultrasonography is its easy practicability, wide availability, and lack of radiation exposure.

9.1.5.4 Cross-sectional imaging

9.6	Consensus-based recommendation	modified 2022
EC	Cross-sectional imaging should be performed to investigate recurrences, e.g. with suspected involvement of functional structures, in cases of locally advanced or metastatic squamous cell carcinoma of the skin, or in cases of suspected perineural tumor growth or metastatic findings.	
	Strong consensus	

Studies on the regular use of cross-sectional imaging in the follow-up of cutaneous SCC do not exist, therefore its use is reserved for the clarification of metastatic findings. The type of cross-sectional imaging to be selected in the work-up of metastatic findings depends on practical and economic availability and the body region to be examined.

In addition to high diagnostic accuracy, CT offers the advantages of standardized whole-body examination (neck to pelvis), general availability, and patient and examiner independence compared with sonography. Especially in the diagnosis of small pulmonary metastases, CT examinations show the highest accuracy [545] and should be preferred for this purpose [544], [111]. The disadvantage of CT is the radiation exposure, as well as the limited soft tissue contrast.

Therefore, MRI is recommended by numerous authors as the method of choice for the evaluation of perineural tumor growth in cutaneous SCC and HNSCC [546], [547], [548], [549]. MRI is also superior to CT in the diagnosis of cerebral and hepatic metastases as well as in cases of suspicion of deep soft tissue infiltration due to the high soft tissue contrast. Another advantage is the lack of radiation exposure.

CT and MRI show comparable accuracies with regard to the diagnosis of cervical lymph node metastases. A meta-analysis comparing different imaging modalities (ultrasound, CT, MRI, PET) in lymph node diagnosis in clinically N0 HNSCC showed similar results in pooled sensitivity and specificity [108].

Table 39: Sensitivity and specificity of imaging techniques

	CT	MRI	PET	LN sonography
Sensitivity	52%	65%	66%	66%
Specificity	93%	81%	87%	78%

Functional imaging using FDG-PET/CT and PET/MRI can detect distant metastases of a SCC in particular with high sensitivity and specificity due to their significantly increased glucose metabolism [105], [117], [116]. Several studies in HNSCC have shown that PET/CT in addition to conventional work-up increases staging accuracy, improves specificity of LN diagnosis, and detects more distant metastases than CT alone [118], [115]. However, micrometastases in LN in patients with clinically unremarkable lymph nodes remain a diagnostic problem for all imaging modalities.

In an analysis by Fujiwara et al. in 26 patients with high-risk SCC, PET/CT showed high sensitivity (100%) and specificity (81%) in the detection of metastases, significantly higher than conventional CT with a sensitivity of 51% and specificity of 69% [119]. In 16% of patients, a false positive finding was seen, which was predominantly due to a strong inflammatory peritumoral infiltrate with mononuclear cells. However, this showed a significantly higher SUVmax of the LN metastases compared to FDG uptake of the surrounding inflammatory infiltrate [119]. These results were confirmed by another monocentric study of 23 patients, which showed a sensitivity of 100% a positive-predictive value of 77.5% and an accuracy of also 77.5% for 18F-FDG-PET in initial staging. This examination was considered to have an important role not only in the detection of small soft tissue and lymph node metastases, but also in primary staging [120]. Another recent study by the same group of authors investigated the value of FDG-PET/CT for recurrence staging in 100 patients with cutaneous SCC. The study confirmed the superior sensitivity of the method, particularly in detecting small cutaneous/subcutaneous foci and LN, and was able to demonstrate PET/CT induced management change in 28% of patients [121].

A retrospective study examining the impact of radiological staging on disease progression in cutaneous SCC in 108 patients showed that high-risk SCC (T2b, T3) who had received multiple staging examinations (79% CT, 21% PET/CT, 19% MRI) over a median follow-up of 43 months had improved disease-free survival ($p=0.028$). No difference was seen in terms of distant metastasis-free or disease-specific survival [113]. A review by Duncan et al. [550] also showed a possible benefit of PET/CT in the detection of locoregional or distant metastases in non-melanoma, but due to the high costs it is mainly limited to the clarification of metastatic findings. At present, there is no guarantee that the costs of regular follow-up care will be covered by the statutory health insurance funds.

On the whole, no general recommendation for the respective examination method can be made on the basis of the current data, since no reliable studies are available for cutaneous SCC.

9.1.6 In which patients can follow-up examinations be waived?

9.7	Consensus-based recommendation	new 2022
EC	All patients with squamous cell carcinoma of the skin (e.g., even with a tumor thickness of ≤ 2.0 mm without the presence of other risk factors) shall be followed up because of the possible development of secondary skin tumors. The frequency of follow-up should also take into account the number of actinic keratoses as well as squamous cell carcinomas of the skin in the history.	
	Strong consensus	

Patients with a low risk of recurrence and a tumor thickness of ≤ 2 mm or a tumor diameter of ≤ 2 cm have no risk of local recurrence or metastasis [18], [19]. Brantsch et al. showed that with a median follow-up time of 43 months (range 1-165), no metastasis occurred in patients without risk factors or a tumor thickness of ≤ 2.0 mm.

Local recurrence also did not occur with a tumor thickness of ≤ 2.0 mm unless desmoplastic growth was also present. This was an independent risk factor for local

recurrence. In the presence of unfavorable prognostic factors such as vertical tumor thickness (>6 mm), horizontal tumor thickness (≥ 2 cm), histologic differentiation (> grade 3), desmoplasia, perineural growth, localization (lower lip, ear), immunosuppression (iatrogenic or disease-related), follow-up cannot be omitted.

The risk of developing further cutaneous SCC should be considered in the discussion of whether follow-up can be omitted altogether in certain groups of patients. The development of independent second tumors are common problems, especially in high-risk patients, but also those with high cumulative UV exposure.

It is estimated that 30-50% of secondary SCCs occur within 1 year of diagnosis of the primary tumor [535] the risk of which is highest within the first 4 years after primary diagnosis but is still significantly increased after 15 years of follow-up (SIR 3.0; 95% CI 2.5-3.6) [535].

In a cohort of 1,426 patients with cutaneous SCC in the United States, the 5- and 10-year risk of further SCC was estimated to be 42.1% and 69.1%, respectively [538] and the standardized incidence rate was estimated to be 15.0% in a systematic review [2].

The risk is for further epithelial tumors is significantly higher for immunosuppressed individuals in whom SCC is often multiple [539], [29]. Therefore, patients with a history of SCC should also undergo follow-up to detect further secondary tumors early.

Melanoma may also occur more frequently after diagnosis of SCC. In a study by van der Lest et al. 64,054 patients with SCC of the skin were studied (national data NCR) [551]. The 21-year cumulative risk of subsequent melanoma after a first SCC or basal cell carcinoma was 1.7% and 1.3% in men and 1.3% and 1.2% in women, respectively. SIRs and AERs remained elevated for up to 21 years after the first SCC or basal cell carcinoma.

Therefore, the goal of follow-up in patients at low risk of recurrence is to detect second tumors early enough so that prognosis does not worsen compared with the initial tumor. Secondary prevention of SCC in follow-up also includes early therapy of precursor lesions such as AK. This argues for control in the first years after primary diagnosis. In the course of time, depending on the number and risk factors of the secondary tumors, it can be discussed to change the follow-up to a skin cancer screening.

9.2 Measures for the primary prevention of actinic keratosis and squamous cell carcinoma of the skin

On this topic, we refer to the detailed S3 guideline "Prevention of skin cancer" [65].

9.3 Preventive measures for special risk groups

On this topic, we refer to the detailed S3 guideline "Prevention of skin cancer" [65].

10 Occupational disease of squamous cell carcinoma of the skin or/and actinic keratosis

A. Bauer, S. Krohn, E. Breitbart, R. Greinert, S.M. John, S. Völter-Mahlknecht, C. Skudlik

10.1 Diagnosis and reporting of suspected occupation-related skin cancer

10.1.1 Skin cancer caused by natural UV radiation (BK No. 5103 BKV)

See: https://www.dguv.de/bk-info/icd-10-kapitel/kapitel_12/bk5103/index.jsp

On January 1st, 2015, with the amendment of the Occupational Diseases Ordinance (BKV), the occupational disease (BK) No. 5103 BKV: "Squamous cell carcinoma or multiple actinic keratoses of the skin caused by natural UV radiation" was included as a new occupational disease in the BKV list.

According to § 202 SGB VII, physicians are legally obligated to report an occupational disease if there is a reasonable suspicion that an occupational disease exists in the course of an insured occupational activity. This also applies to dentists and entrepreneurs. A report must be made even if the insured person objects. It can only be dispensed with if there is certainty that the illness has already been reported. A reasonable suspicion of an occupational disease can also (but does not have to) be reported by the insured person concerned, family, friends, etc.

The medical BK notification must be made if there is a reasonable suspicion that an occupational disease in the sense of the so-called „BK list“ (Annex 1 of the Occupational Diseases Ordinance (BKV)) exists. In the case of BK No. 5103 BKV, the suspicion is well-founded if the following have been diagnosed at work-related exposed body regions:

- an SCC or
- a Bowen carcinoma or
- their precursors, AK or Bowen's disease

The precancerous lesions must be multiple in the sense of BK No. 5103 BKV, i.e., with a number of more than 5 within 12 months or a field cancerization in a confluent area larger than 4 cm².

In addition, there must have been relevant work-related UV exposure from outdoor work. A rough estimate is sufficient for this at the time of reporting. The guideline value is a ratio of private and work-related UV exposure. Since the private dose increases with each year of life, the work-related UV exposure duration required for BK recognition also increases. Long-term exposure for the purposes of this occupational disease is considered to be, for example, for an age of

- 50 years - 15 years of outdoor work
- 60 years - 18 years of outdoor work
- 70 years - 21 years of outdoor work
- 80 years - 24 years of outdoor work

Histological confirmation of the diagnosis is required for the presence of SCC but not for multiple AK in which case clinical diagnosis is sufficient. Nevertheless, it is recommended that histology be performed for at least one of the present AKs and that this be enclosed with the BK report.

The SCC and/or AK/field cancerization must be localized on occupationally exposed areas such as face, ears, capillitium, neck, hands, and forearms. However, depending on the particular outdoor activities and the inadequate or lack of protective measures in many cases, other localizations may also be considered as occupational, e.g. the back if work was regularly performed without a shirt.

The following occupations/activities are listed in the scientific rationale as being at significantly higher risk than the rest of the population for developing multiple AK or SCC due to occupational natural UV exposure: Agriculture, forestry, nurseries, fishing and maritime, construction and trades (e.g., roofers, carpenters, builders, masons, steelworkers, etc.), road workers, lifeguards, mountain guides, and the like. But it is not so much the occupation that matters, but the actual activity performed outdoors. Bicycle couriers, sports instructors, educators in day-care centers, waiters in beer gardens etc. are also potentially at risk.

The medical report in the event of a suspected occupational disease is submitted using form F6000 „Medical report in the event of a suspected occupational disease“ to the responsible statutory accident insurance institution (Employer's Liability Insurance Association, Accident Insurance Fund) or to a state authority as the body responsible for medical occupational safety and health (http://www.dguv.de/medien/formtexte/aerzte/f_6000/f6000.pdf). It must be submitted without delay, i.e. without culpable hesitation. The report is remunerated separately by the AIF agency (UV-GOÄ No. 141). The insured persons must be informed of the contents and of the AIF institution to which the BK notification is sent. The responsible AIF institution depends on the last hazardous activity of the insured person and is:

- in the case of companies in the commercial sector, an employers' liability insurance association (broken down by industry),
- in the case of public-sector companies, one of the regionally subdivided accident insurance funds and
- for activities in agriculture and horticulture, the Social Insurance for Agriculture, Forestry and Horticulture (SVLFG).

Special regulations apply to civil servants (e.g. in the police service or the armed forces) and other persons who are not insured under the statutory accident insurance scheme, and the suspected BK must generally be reported to the employer by the person who has fallen ill. Further details are regulated in the respective civil service pension laws of the federal states/federal government.

As a follow-up to the BK report, the dermatologist usually receives the form Skin Cancer Report from the UVT. In this report, a detailed history of the disease is requested (F 6120-5103 0416 Skin cancer report,

http://www.dguv.de/medien/inhalt/versicherung/bk/hautkrankh/documents/f6120_5103.pdf, see appendix), so that the UVT can check whether there is or was a connection between the reported skin cancer and the occupational effects. The skin cancer report also asks about basal cell carcinomas (not relevant for BK 5103), as the report is also used for the skin cancer facts listed below (BK5102, BK1108, BK2402).

Work-related skin cancers can also be caused by work-related exposure to certain carcinogens. Currently, the BK numbers listed below may apply.

10.1.2 Diseases caused by arsenic or its compounds (BK No. 1108 BKV)

See: https://www.dguv.de/bk-info/icd-10-kapitel/kapitel_01/bk1108/index.jsp

After occupational exposure to arsenic or arsenic compounds, AK, SCC, as well as Bowen's disease, Bowen's carcinomas and basal cell carcinomas (predominantly superficial basal cell carcinomas) also occur on body parts covered by clothing. Pathognomonic manifestations include palmoplantar keratoses, but these may not always be present. SCC arise from precursors or on unchanged skin. Arsenic is absorbed into the body in the form of dust, vapor, or gas through the respiratory tract, gastrointestinal tract, and skin. A threshold for carcinogenic effects cannot be quantified at this time. Biological effects have been observed even at low concentrations [552]. Sources of occupational hazards are rarely found today, e.g., in semiconductor manufacturing. In addition, arsenic or arsenic compounds can be a component of alloys.

Latency periods between exposure and disease manifestation may take years to decades. For Bowen's disease and basal cell carcinoma, latency periods of an average of 17.8 years and for SCC of an average of 19.7 years after initial contact with arsenic have been published [553]. The BK-Nr. 1108 BKV plays almost no role in dermatological practice anymore, since contamination is extremely unlikely due to optimized occupational safety measures. Historical exposures, e.g. due to the application of arsenic in viticulture, are rarely of importance today, as the persons affected have often already died due to old age.

10.1.3 Diseases caused by ionizing radiation (BK No. 2402 BKV)

See: https://www.dguv.de/bk-info/icd-10-kapitel/kapitel_02/bk2402/index.jsp

Ionizing radiation can cause malignant diseases of the skin, depending on the dose (see scientific justification for BK No. 2402 BKV), such as SCC and basal cell carcinoma, rarely fibrosarcoma and angiosarcoma. Workers in the medical field, in material testing, in the X-ray apparatus or X-ray tube industry may be exposed to X-rays directly or indirectly via scattered radiation. Radioactive substances and elements in appropriate doses can be a source of danger to persons who come into contact with these substances or the radiation they emit during extraction, processing, use, or transport (medical diagnostics or therapy, scientific examinations, materials testing, measurement procedures, industrial processing and application of radionuclides, activities in uranium mining and in nuclear facilities). The latency period between radiation exposure and the development of basal cell carcinoma is estimated to be at least 20 years [554], [555]. The latency period for SCC is reported to be at least 20–30 years [556].

10.1.4 Skin cancer or skin changes tending to cancer formation due to soot, crude kerosene, tar, anthracene, pitch or similar substances (BK No. 5102 BKV)

See: https://www.dguv.de/bk-info/icd-10-kapitel/kapitel_02/bk5102/index.jsp

This is one of the oldest occupational diseases in Germany, having been included in the BKV as early as 1925. According to current knowledge, substances in the sense of BK No. 5102 BKV can cause SCC and carcinomata in situ as well as basal cell carcinomas. Direct skin contact plays an essential role in this context. The latency period from initial exposure to the appearance of the corresponding skin tumors can be years to decades. This development is also possible after cessation of exposure.

Often, when the skin cancer appears, there are other signs of a so-called „tar or pitch skin disease“ (e.g. folliculitis, acne, brownish diffuse pigmentation (melanosis), hyperkeratosis), but the tumors can also appear without these bridging symptoms. On such altered skin, but also without these changes, single or multiple so-called tar or pitch warts (carcinomata in situ) can develop. Tar or pitch warts occur mainly on the face (including the nose, periorbital region, ears) and on the back of the hand, but also on the forearm, lower abdomen, and scrotum.

There is no more precise information on how long/how intense chronic PAH-exposure must be in each activity to induce tumors. For a cumulative exposure of ≥ 2 years during the working life, a report should be made at the first manifestation of an epithelial tumor or precancerous lesion (see above). A detailed exposure determination is made by the UVT in the determination procedure.

The latency period from exposure to tumor manifestation may take years to decades. In an evaluation of data from tar refinery workers (1946–2002), SCC was found after an average latency period of 29.1 years and for basal cell carcinoma of 36.0 years after the onset of exposure [557].

For BKs B-No. K5102, 2402 and 1108 BKV no minimum number/area of precancerous lesions is required. A BK report is made at the occurrence of the first precancerous lesion or one of the above-mentioned tumors.

10.1.5 Summary

The following diseases can currently be recognized as occupational diseases (based on [558]):

Table 40: Overview of occupational skin cancer

BK/ Disease pattern	Carcinoma in situ	Squamous cell carcinoma	Basal cell carcinoma	Malignant melanomas	Angio-/ fibrosarcomas
Arsenic BK No. 1108	X	X	X	-	-
Ionizing radiation BK-No. 2402	X	X	X	-	X
Tar, pitch, etc. BK No. 5102	X	X	X	-	-
Natural UV radiation BK No. 5103	X	X	-	-	-
Scars	X	X	X	-	-

10.2 Occupational skin cancer prevention

For the prevention of occupational skin cancer, please refer to the S3 guideline "Prevention of skin cancer" [65].

10.3 Follow-up care for BK No. 5103 BKV

For the dermato-oncologically recommended follow-up intervals for the different stages of SCC, see [Chapter 9.1](#).

After recognition of BK No. 5103, the data on the disease, any existing employment relationships, and preventive measures taken are queried 1x/year by the UVT using the aftercare report form "Nachsorgebericht" (F6122-5103 0416 Nachsorgebericht BK 5103 Hautkrebs

http://www.dguv.de/medien/inhalt/versicherung/bk/hautkrankh/documents/f6122_5103.pdf, see appendix). In addition, the UVT must be notified in the event of the occurrence of a SCC, metastasis, or if an inpatient stay is required as a result of the occupational disease (form F 1100).

10.4 Occupational health care for outdoor activities with intensive exposure to natural UV radiation

For the occupational medical prevention of occupational skin cancer, we refer to the S3 guideline "Prevention of skin cancer" [\[65\]](#).

11 Care structures for actinic keratosis and squamous cell carcinoma

11.1 Skin Tumor Centers

C. Garbe, U. Leiter

Skin tumor centers have been established in Germany since early 2009, the first of which was in Heidelberg; 63 centers were certified by the end of 2018. Certification takes place in 2 phases:

- Review of the survey form skin tumor centers (downloadable at www.onkozert.de) by two expert auditors, return with information about deviations or suggestions for improvement (evaluation of the survey form) to the center.
- Specialist audit conducted by the 2 specialist auditors who also evaluated the survey questionnaire. Not only the center itself but also the cooperating departments are visited.

The heart of the skin tumor center is the interdisciplinary skin tumor conference. This is where as many therapeutic decisions as possible should be made. The establishment of a dedicated skin tumor conference/skin tumor board with the main participants from dermatology, internal oncology, surgery, radiology, and radiotherapy is an essential step for the establishment of the center. Written agreements with main treatment partners and additional treatment partners must be established. Minimum numbers in the treatment of skin tumor patients are required.

Another important point is tumor documentation. All skin tumors must be recorded and documented electronically. Patient pathways and SOPs (Standard Operating Procedures) for treatments (sentinel lymph node, chemotherapy, etc.) are presented. Good cooperation with referring physicians, with psycho-oncology and with social services must be ensured.

The aim is to coordinate the care and interdisciplinary treatment of skin tumor patients, especially with locally advanced or metastatic tumors, according to the current state of medical knowledge.

The implementation of the present S3 guideline plays an essential role in all care structures.

11.2 Quality indicators

S. Wesselmann, H. Adam

Quality indicators (QIs) are measures whose collection serves to assess the quality of the underlying structures, processes or outcomes [559], [560]. QI are an important instrument of quality management. The aim of their use is the continuous improvement of care by presenting the results of care, critically reflecting on them and improving them if necessary. The present selection of QIs was prepared according to the methodology of the German Guideline Program in Oncology. For the derivation process, a "Quality Indicators Working Group" was constituted. This group created the final set of QIs based on the strong recommendations of the guideline

(recommendation strength A, "shall") and the results of the search for existing national and international QIs. The exact procedure and composition of the WG are outlined in the guideline report.

After a face-to-face meeting and a telephone conference of this WG, 1 QI was included in the final indicator set.

Table 41: Quality Indicator

Quality Indicator	Reference Recommendation	Evidence base / further information
-------------------	--------------------------	-------------------------------------

QI 1: Pathology report

<p>Numerator: Number of patients with the following information in the histological report of findings:</p> <ul style="list-style-type: none"> • Histological tumor type • Histological depth extension (description u measurement) • Perineural spread • Vascular invasion • Degree of differentiation and • R classification invasive tumor proportion <p>Denominator: All patients with SCC and excision.</p>	<p>Recommendation 4.19 The histological report of a SCC shall include the following in addition to the diagnosis:</p> <ul style="list-style-type: none"> • Histological tumor type (for specific subtypes of SCC) • Description of the histological depth extension in relation to the anatomical stratification (especially from Clark level V, corresponding to infiltration of the subcutis) • Measurement of the depth extension from an invasion depth of 2 mm (corresponds approximately to the diameter of a 10x field of view) • In the positive case, indication of the presence of perineural spread, vascular invasion or low differentiation • Completeness of resection of the invasive tumor portion 	<p>EC</p> <p>Quality Objective: To provide complete information in pathology reports for excision of a SCC as frequently as possible. The numerator is always a subset of the denominator. The quality indicator is not to be documented with the basic oncology data set of the cancer registries (as of 10.2018).</p>
--	---	--

12 Attachments

12.1 Changes in Version 2.01

Table 42: Changes in Version 2.01

Version 1.1	Version 2.01	Change
3.1	3.1	modified 2022
The data situation for prognostic factors of the transition AK -> SCC is not sufficient. At the moment, no reliable values for the probability of the transition AK -> SCC can be given.	The data situation for reliable prognostic factors of the transition from AK to SCC is insufficient. At the moment, no reliable values for the probability of progression can be given. The following clinical factors are prognostically unfavorable: <ul style="list-style-type: none"> • Immunosuppression • Therapy resistance • Field cancerization 	
3.2	3.2	modified 2022
Because existing clinical and histological systems (e.g., classification according to Olsen or KIN 1-3) are not sufficiently prognostically validated, new classifications should be developed.	Existing clinical and histological systems (e.g., classification according to Olsen, graduation into KIN 1-3, counting of lesions) are not sufficiently validated prognostically and thus dispensable in clinical practice.	
	4.2	new 2022
	Multiple qualitative and quantitative factor integrating scores (e.g. AK-FAS, AKASI) improve standardized reporting of findings for actinic keratosis.	
	4.3	new 2022
	Cheilitis actinica is etiologically and morphologically the counterpart of actinic keratosis of the keratinizing squamous epithelium of the vermillion.	
4.14	4.15	modified 2022

Version 1.1	Version 2.01	Change
If SCC or Bowen's disease is clinically suspected, histology shall also be obtained to differentiate another benign or malignant neoplasm. Preoperatively, the maximum diameter of the neoplasm should be documented.	If squamous cell carcinoma of the skin, cheilitis actinica or Bowen's disease is clinically suspected, histology shall also be performed to differentiate other benign or malignant neoplasia. Preoperatively, the maximum diameter of the neoplasia should be documented for squamous cell carcinoma of the skin and Bowen's disease.	
5.2	5.2	modified 2022
A combination of a field-directed with a lesion-directed therapeutic modality may be offered.	Primary or sequential combination therapy of various field- or lesion-targeted procedures should be offered for actinic keratosis.	
5.3	5.3	modified 2022
Cryosurgery should be offered in a lesion-directed fashion for single or multiple Olsen grade I-III AK in immunocompetent individuals.	Cryosurgery should be offered for single or multiple actinic keratoses.	
5.4	5.4	modified 2022
Surgical removal of grade I-III AK according to Olsen (e.g., by curettage, shallow ablation, or complete excision) should be offered for single lesions in immunocompetent and immunosuppressed patients.	Surgical excision (e.g., by curettage, shave excision or complete excision) should be offered for single actinic keratoses.	
5.5	5.5	modified 2022
Current data do not allow recommendations for therapy of AK with chemical peels.	Chemoexfoliation via peels can be offered for single or multiple actinic keratoses as well as for field cancerization.	
	5.6	new 2022

Version 1.1	Version 2.01	Change
	Potassium hydroxide 5% solution may be offered for single or multiple actinic keratoses.	
5.6	5.7	modified 2022
Treatment with ablative laser procedures may be offered for single or multiple Olsen's grade I-III AK and for field cancers in immunocompetent patients.	Ablative laser procedures may be offered for single or multiple actinic keratoses as well as for field cancerization.	
5.7	5.8	modified 2022
Treatment with non-ablative laser procedures may be offered for single or multiple Olsen grade I-II AK.	Non-ablative laser procedures may be offered for single or multiple actinic keratoses.	
5.8	5.9	modified 2022
Treatment with diclofenac sodium 3% in hyaluronic acid 2.5% gel should be offered for single or multiple grade I-II AK according to Olsen in immunocompetent individuals.	Diclofenac sodium 3% gel should be offered for single or multiple actinic keratoses.	
5.9	5.10	modified 2022
Field-directed therapy with diclofenac sodium 3% in hyaluronic acid 2.5% gel should be offered for field cancerization.	Diclofenac sodium 3% gel should be offered for field cancerization.	
5.10	5.11	modified 2022
5-Fluorouracil 5% cream should be offered for the treatment of single and multiple Olsen grade I-II AK.	5-Fluorouracil 5% cream should be offered for single and multiple actinic keratoses.	
5.11	5.12	modified 2022

Version 1.1	Version 2.01	Change
Field-directed therapy with 5-fluorouracil 5% cream should be offered for field carcinomatization.	5-Fluorouracil 5% cream should be offered for field cancerization.	
	5.13	new 2022
	5-Fluorouracil 4% cream should be offered for single and multiple actinic keratoses and for field cancerization.	
5.12	5.14	modified 2022
Evidence is available for the efficacy of 5-fluorouracil 0.5% cream for single and multiple grade I-II AK according to Olsen. However, there is currently no approval for this concentration in Germany.	There is evidence for the efficacy of 5-fluorouracil 0.5% cream in single and multiple actinic keratoses. However, there is currently no approval for this concentration in Germany.	
5.13	5.15	modified 2022
5-Fluorouracil 0.5% with salicylic acid 10% in solution should be offered lesion-directed or field-directed for single or multiple grade I-II AK according to Olsen and for field carcinomatization in immunocompetent individuals.	5-Fluorouracil 0.5% with salicylic acid 10% in solution should be offered for single or multiple actinic keratoses as well as for field cancerization.	
5.14	5.16	modified 2022
Ingenol mebutate should be offered as field-directed therapy for single or multiple grade I-II Olsen's AK and for field carcinomatization. suspended as a result of dormant approval (see Red Hand Letter).	Ingenol mebutate shall not be offered for actinic keratosis therapy.	
5.15	5.17	modified 2022

Version 1.1	Version 2.01	Change
Imiquimod 5% cream should be offered on a field-directed basis for single or multiple grade I-II AK according to Olsen and for field cancerization in immunocompetent individuals.	Imiquimod 5% cream should be offered for single or multiple actinic keratoses as well as for field cancerization.	
5.17	5.18	modified 2022
Imiquimod 3.75% cream should be offered field-directed for multiple grade I-II AK according to Olsen and for field cancerization in immunocompetent individuals on the face or hairless capillitium.	Imiquimod 3.75% cream should be offered for multiple actinic keratoses as well as for field cancerization.	
	5.19	new 2022
	Tirbanibulin 1% ointment should be offered for single or multiple actinic keratoses as well as for field cancerization.	
5.18	5.20	modified 2022
Conventional photodynamic therapy with 5-aminolevulinic acid or its methyl ester (5-ALA or MAL) should be offered on a field-directed basis for single or multiple grade I-II AK according to Olsen and for field cancers.	Photodynamic therapy with red light illumination using 5-aminolevulinic acid (ALA) or its methyl ester (MAL) should be offered for single or multiple actinic keratoses and for field cancerization.	
5.19	5.21	modified 2022
MAL in combination with daylight (daylight MAL-PDT) should be offered on a field-directed basis for nonpigmented, single or multiple grade I-II AK according to Olsen, and for	Photodynamic therapy with natural or simulated daylight with 5-aminolevulinic acid (ALA) or its methyl ester (MAL) should be offered for single or multiple actinic keratoses as well as for field cancerization.	

Version 1.1	Version 2.01	Change
field cancers on the face and capillitium in immunocompetent individuals.		
5.23	5.22	modified 2022
Treatment with photodynamic therapy with MAL in combination with illumination by an artificial red light source (630 nm) should be offered for single or multiple grade I-II AK according to Olsen, as well as for field cancerization in immunosuppressed patients.	Photodynamic therapy with red light illumination using 5-aminolevulinic acid (ALA) or its methyl ester (MAL) should be offered for single or multiple actinic keratoses and for field cancerization in immunosuppressed patients.	
5.24	5.23	modified 2022
Field-directed therapy with imiquimod 5% cream may be offered to immunosuppressed patients with multiple grade I-II AK according to Olsen, as well as in field cancerization. In this case, the lack of approval should be noted.	Imiquimod 5% cream may be offered for single or multiple actinic keratoses and for field cancerization in immunosuppressed patients. For the latter, the lack of regulatory approval should be noted.	
5.25	5.24	modified 2022
Therapy with diclofenac sodium 3% in hyaluronic acid 2.5% gel should be offered to patients with single or multiple grade I-II AK according to Olsen as well as in field carcinomatization under immunosuppression.	Diclofenac sodium 3% gel should be offered for single or multiple actinic keratoses and for field cancerization in immunocompromised patients.	
	6.1	new 2022
	The indication for therapy of cheilitis actinica should be made in synopsis of the clinical presentation, risk factors (e.g. immunosuppression, cumulative UV exposure, involvement of the entire lower lip, involvement also of the upper lip), comorbidities,	

Version 1.1	Version 2.01	Change
	life expectancy and the patient's wishes.	
	6.2	new 2022
	Before choosing a treatment procedure, a biopsy should be obtained for diagnostic confirmation and to exclude invasive squamous cell carcinoma.	
	6.3	new 2022
	Histological control shall be carried out if there is clinical evidence of a lack of response or incomplete response to therapy.	
	6.4	new 2022
	Surgical removal of cheilitis actinica (e.g., by vermilionectomy or lip-shave with histological workup and information on the status of resection margins) shall be offered in cases of extensive involvement.	
	6.5	new 2022
	Treatment of cheilitis actinica with ablative laser procedures (CO ₂ , Er:YAG) may be offered.	
	6.6	new 2022
	Insufficient data currently does not allow recommendations for the therapy of cheilitis actinica with non-ablative laser procedures.	
	6.7	new 2022
	The data available on cryosurgery do not allow a conclusive	

Version 1.1	Version 2.01	Change
	recommendation for the therapy of cheilitis actinica.	
	6.8	new 2022
	Chemical peeling shall not be used for cheilitis actinica because of a lack of evidence of benefit.	
	6.9	new 2022
	Treatment with diclofenac sodium 3% gel may be offered for cheilitis actinica.	
	6.10	new 2022
	Insufficient data currently does not allow an evidence-based recommendation for topical therapy of cheilitis actinica with 5-fluorouracil.	
	6.12	new 2022
	Photodynamic therapy with red light illumination and 5-aminolevulinic acid (ALA) or its methyl ester (MAL) should be offered for therapy of cheilitis actinica.	
	6.13	new 2022
	Methyl aminolevulinate (MAL) in combination with natural or simulated daylight (MAL-dIPDT) should be offered for therapy of cheilitis actinica.	
	7.1	new 2022
	Prior to treatment of Bowen's disease, a biopsy shall be obtained to exclude invasive squamous cell carcinoma,	

Version 1.1	Version 2.01	Change
	<p>other neoplasia, or inflammatory conditions.</p> <p>If there is clinical evidence of a lack of response or incomplete response to therapy, histological control shall be carried out.</p>	
	7.2	new 2022
	Surgical excision of Bowen's disease (e.g., by shave excision or complete excision) shall be offered for single lesions.	
	7.3	new 2022
	Cryosurgery may be offered for the treatment of Bowen's disease.	
	7.4	new 2022
	Ablative laser procedures may be offered to treat Bowen's disease.	
	7.5	new 2022
	5-Fluorouracil 5% cream should be offered for the treatment of Bowen's disease.	
	7.6	new 2022
	Imiquimod 5% cream may be offered for the treatment of Bowen's disease in immunocompetent individuals. In this case, the lack of approval should be noted.	
	7.7	new 2022
	Photodynamic therapy with red light illumination should be offered for the treatment of Bowen's disease in two therapy cycles within 4 weeks.	

Version 1.1	Version 2.01	Change
	7.8	new 2022
	Pretreatment (e.g., ablative fractional laser procedures, microneedling) may be offered before photodynamic therapy with red light illumination to enhance penetration.	
	8.1	new 2022
	The following risk factors of SCC shall be reported to the examining pathologist/dermatopathologist if present: recurrence, tumor diameter >2 cm, localization ear, lip or temple, immunosuppression and evidence of perineural invasion, no displaceability from the subsurface.	
	8.2	new 2022
	Surgical therapy of the primary tumor shall be carried out according to the following algorithm: see Figure 4 .	
6.9	8.12	modified 2022
Adjuvant radiotherapy should be performed if risk factors are present: Scarce resection margin (<2 mm, in the absence of the possibility of resection) Extensive perineural sheath infiltration.	Adjuvant radiotherapy should be performed in the presence of extensive perineural sheath infiltration.	
6.9	8.13	modified 2022
Adjuvant radiotherapy should be performed in the presence of risk factors: Scarce resection margin (<2 mm, in the absence of the possibility of resection) Extensive perineural sheath infiltration.	Adjuvant radiotherapy may be considered if the resection margin is close.	

Version 1.1	Version 2.01	Change
	8.14	new 2022
	Current data do not support a recommendation for combining adjuvant radiotherapy with systemic therapy.	
	8.20	new 2022
	In case of (distant) metastasis or locally advanced disease that cannot be controlled by surgical or radiotherapeutic interventions or only with major limitations of functionality, the indication for systemic therapy shall be considered.	
	8.21	new 2022
	The indication for systemic therapy should be made in an interdisciplinary tumor board.	
	8.22	new 2022
	Patients with locally advanced or metastatic SCC shall be offered first-line immunotherapy with a PD-1-inhibitor approved for this indication.	
	8.23	new 2022
	In case of progression under PD-1-blockade or contraindications to this type of immunotherapy, EGFR-directed therapy or chemotherapy shall be offered.	
7.1	9.1	modified 2022
Follow-up of patients with cutaneous SCC* should be offered at risk-adjusted intervals according to the following schedule:	Follow-up for patients with SCC of the skin should be offered at risk-adjusted intervals according to the following schedule:	

Version 1.1	Version 2.01	Change																																																																						
	<table border="1"> <thead> <tr> <th></th> <th>Year 1-2</th> <th>Year 3-5</th> <th>Year 6-10</th> </tr> </thead> <tbody> <tr> <td colspan="4">Primary tumor stage</td> </tr> <tr> <td>Low risk</td> <td>6-monthly</td> <td>Yearly</td> <td>..</td> </tr> <tr> <td>High risk</td> <td>3-monthly</td> <td>6-monthly</td> <td>annually</td> </tr> <tr> <td>Immunocompromised patients</td> <td>3-monthly</td> <td>3-6-monthly</td> <td>3-6-monthly according to risk profile</td> </tr> <tr> <td colspan="4">Advanced stages</td> </tr> <tr> <td>Locally advanced/ metastatic</td> <td>3-monthly (up to and including year 3)</td> <td>3-6-monthly (year 4-5)</td> <td>6-monthly/ annually</td> </tr> </tbody> </table>		Year 1-2	Year 3-5	Year 6-10	Primary tumor stage				Low risk	6-monthly	Yearly	..	High risk	3-monthly	6-monthly	annually	Immunocompromised patients	3-monthly	3-6-monthly	3-6-monthly according to risk profile	Advanced stages				Locally advanced/ metastatic	3-monthly (up to and including year 3)	3-6-monthly (year 4-5)	6-monthly/ annually																																											
	Year 1-2	Year 3-5	Year 6-10																																																																					
Primary tumor stage																																																																								
Low risk	6-monthly	Yearly	..																																																																					
High risk	3-monthly	6-monthly	annually																																																																					
Immunocompromised patients	3-monthly	3-6-monthly	3-6-monthly according to risk profile																																																																					
Advanced stages																																																																								
Locally advanced/ metastatic	3-monthly (up to and including year 3)	3-6-monthly (year 4-5)	6-monthly/ annually																																																																					
	9.2	new 2022																																																																						
	<p>The following examination methods are recommended depending on risk factors of the primary tumor, immunosuppression or after locally advanced and metastatic squamous cell carcinoma of the skin according to the present scheme:</p> <table border="1"> <thead> <tr> <th>Stage</th> <th colspan="3">Physical examination</th> <th colspan="3">Lymph node sonography</th> <th colspan="3">Imaging examinations CT, MRI, PET-CT</th> </tr> <tr> <th>Year</th> <th>1-2</th> <th>3-5</th> <th>6-10</th> <th>1-2</th> <th>3-5</th> <th>6-10</th> <th>1-3</th> <th>4-5</th> <th>6-10</th> </tr> </thead> <tbody> <tr> <td>Primary tumors</td> <td>2x</td> <td>1x</td> <td>-</td> <td>0-2x</td> <td>-</td> <td>-</td> <td>-</td> <td>-</td> <td>-</td> </tr> <tr> <td>Low risk</td> <td></td> <td></td> <td></td> <td></td> <td></td> <td></td> <td></td> <td></td> <td></td> </tr> <tr> <td>High risk</td> <td>4x</td> <td>2x</td> <td>1x</td> <td>1-4x***</td> <td>0-2x***</td> <td>-</td> <td>0-2x**</td> <td>-</td> <td>-</td> </tr> <tr> <td>Immunosuppressed patients</td> <td>4x</td> <td>2-4x</td> <td>2-4x</td> <td>1-4x***</td> <td>0-2x***</td> <td>-</td> <td>0-2x**</td> <td>-</td> <td>-</td> </tr> <tr> <td>Locally advanced / metastasized</td> <td>4x</td> <td>4x</td> <td>2-4x</td> <td>4x</td> <td>2x</td> <td>-</td> <td>2x</td> <td>-</td> <td>-</td> </tr> </tbody> </table> <p>*for R0 resected stages, Low risk: TD ≤6mm, <4mm for desmoplasia, G1-2 differentiation, High risk: TD > 6mm, >4mm for desmoplasia, G3-4 differentiation, perineural tumor growth, immunosuppressed and patients with secondary tumors, see question 1.3 ** in case of perineural tumor growth *** depending on risk factors</p>	Stage	Physical examination			Lymph node sonography			Imaging examinations CT, MRI, PET-CT			Year	1-2	3-5	6-10	1-2	3-5	6-10	1-3	4-5	6-10	Primary tumors	2x	1x	-	0-2x	-	-	-	-	-	Low risk										High risk	4x	2x	1x	1-4x***	0-2x***	-	0-2x**	-	-	Immunosuppressed patients	4x	2-4x	2-4x	1-4x***	0-2x***	-	0-2x**	-	-	Locally advanced / metastasized	4x	4x	2-4x	4x	2x	-	2x	-	-	
Stage	Physical examination			Lymph node sonography			Imaging examinations CT, MRI, PET-CT																																																																	
Year	1-2	3-5	6-10	1-2	3-5	6-10	1-3	4-5	6-10																																																															
Primary tumors	2x	1x	-	0-2x	-	-	-	-	-																																																															
Low risk																																																																								
High risk	4x	2x	1x	1-4x***	0-2x***	-	0-2x**	-	-																																																															
Immunosuppressed patients	4x	2-4x	2-4x	1-4x***	0-2x***	-	0-2x**	-	-																																																															
Locally advanced / metastasized	4x	4x	2-4x	4x	2x	-	2x	-	-																																																															
7.3	9.4	modified 2022																																																																						
<p>Lymph node ultrasonography should be performed in patients at increased risk of metastasis or with unclear palpation findings.</p>	<p>Lymph node ultrasonography should be performed in patients at high risk of metastasis* or with unclear palpation findings and in cases of locally advanced and metastatic SCC of the skin.</p> <p>*High risk: TD >6mm, >4mm in desmoplasia, G3-4 differentiation, perineural tumor growth, immunosuppressed and patients with secondary tumors.</p>																																																																							

Version 1.1	Version 2.01	Change
7.4	9.5	modified 2022
X-ray thoracic examinations should not be routinely performed in follow-up. Abdominal ultrasonography should not be routinely performed in follow-up.	Chest X-ray examinations and abdominal ultrasonography should not be routinely performed during follow-up.	
7.5	9.6	modified 2022
Cross-sectional imaging should be performed to clarify recurrences, e.g., with suspected involvement of functional structures or when perineural tumor growth or metastasis-specific findings are suspected.	Cross-sectional imaging should be performed to investigate recurrences, e.g. with suspected involvement of functional structures, in cases of locally advanced or metastatic squamous cell carcinoma of the skin, or in cases of suspected perineural tumor growth or metastatic findings.	
	9.7	new 2022
	All patients with squamous cell carcinoma of the skin (e.g., even with a tumor thickness of ≤ 2.0 mm without the presence of other risk factors) shall be followed up because of the possible development of secondary skin tumors. The frequency of follow-up should also take into account the number of actinic keratoses as well as squamous cell carcinomas of the skin in the history.	

13 List of Tables

Table 1: Participating professional associations and organizations (alphabetical).....	11
Table 2: Composition of Guideline Workgroups.....	14
Table 3: Abbreviations Used	16
Table 4: Scheme of evidence grading according to Oxford (2011 version).....	21
Table 5: Scheme of recommendation grading.....	23
Table 6: Consensus strength.....	24
Table 7: Age-standardized incidence rate for SCC of the skin for regions with coverage judged to be sufficiently high and stable (per 100,000 persons and year, old European standard) .	27
Table 8: Crude incidence rates as projected case numbers in Germany in 2014-2018	28
Table 9: TNM classification of SCC of the skin for the labial skin (excluding lip vermilion), trunk, upper extremities and shoulders, lower extremities, and hip and scrotum (8th edition, 2017)	42
Table 10: TNM classification of SCC of the head and neck according to AJCC / UICC (8th edition, 2017)	44
Table 11: Factors to consider when making treatment decisions for AK*	60
Table 12: Lesion-directed and field-directed therapy methods in AK	61
Table 13: Therapy duration of interventions for AK	62
Table 14: Overview of the included single studies on cryosurgery.....	65
Table 15: Overview of included individual studies on chemoexfoliation	71
Table 16: Individual studies on potassium hydroxide	73
Table 17: Overview of the included single studies on ablative laser therapy	75
Table 18: Overview of individual studies on diclofenac sodium 3% gel	79
Table 19: Overview of included individual studies on 5-FU (concentration 5%).....	86
Table 20: Overview of included individual studies on 5-FU (concentration 0.5%).....	94
Table 21: Overview of included individual studies on 5-FU with SA	97
Table 22: Overview of individual studies on imiquimod 5%.....	102
Table 23: Overview of individual studies on imiquimod 3.75%	109
Table 24: Overview of included single studies on tirbanibulin.....	111
Table 25: Overview of included individual studies on MAL-PDT	113
Table 26: Overview of included individual studies on ALA-PDT	119

Table 27: Overview of included individual studies on daylight PDT	131
Table 28: Overview of the included individual studies for the immunosuppressed subgroup	132
Table 29: Overview of individual studies on other topicals.....	137
Table 30: Overview of the included single studies on retinoids	146
Table 31: Balance sheet of ablative and physical procedures	149
Table 32: Balance sheet drug interventions	151
Table 33: Therapy methods for cheilitis actinica.....	159
Table 34: Balance sheet interventions for cheilitis actinica.....	168
Table 35: Adverse events of the comparison cryosurgery vs. MAL red light PDT vs. placebo vs. 5- fluorouracil 5% cream for the treatment of Bowen's disease	176
Table 36: Ongoing therapeutic trials with the use of PD1 blockers in cutaneous SCC (FUI = follow-up interval)	214
Table 37: Therapeutic studies on the use of chemotherapeutic agents, interferon alpha, and 13-cis retinoic acid in cutaneous SCC	216
Table 38: Therapeutic studies with the use of EGFR blockers in cutaneous SCC	218
Table 39: Sensitivity and specificity of imaging techniques	227
Table 40: Overview of occupational skin cancer.....	234
Table 41: Quality Indicator.....	237
Table 42: Changes in Version 2.01	238

14 List of Figures

Figure 1: Age-standardized incidence rate for SCC of the skin (select registries by state, period 2009-2018)	26
Figure 2: Age-specific incidence rate for pool registries (2014-2018) per 100,000 persons	29
Figure 3: Age-standardized disease rates for SCC of the skin in the Netherlands and Germany (men and women); compared with incidence rates for melanoma	30
Figure 4: Algorithm for surgical therapy.....	191

15 Literature References

1. Schafer I, Reusch M, Siebert J, Spehr C, Augustin M. Health care characteristics of basal cell carcinoma in Germany: the role of insurance status and socio-demographic factors. *J.Dtsch.Dermatol.Ges.* 2014;12:803-811. URL: <https://www.ncbi.nlm.nih.gov/pubmed/25176460>
2. Flohil SC, van der Leest RJ, Dowlatshahi EA, Hofman A, de Vries E, Nijsten T. Prevalence of actinic keratosis and its risk factors in the general population: the Rotterdam Study. *J Invest Dermatol.* 2013;133:1971-8. URL: <https://pubmed.ncbi.nlm.nih.gov/23510990/>
3. Green AC. Epidemiology of actinic keratoses. *Curr Probl Dermatol.* 2015;46:1-7. URL: <https://www.ncbi.nlm.nih.gov/pubmed/25561199>
4. Memon AA, Tomenson JA, Bothwell J, Friedmann PS. Prevalence of solar damage and actinic keratosis in a Merseyside population. *Br J Dermatol.* 2000;142:1154-9. URL: <https://www.ncbi.nlm.nih.gov/pubmed/10848739>
5. Schmitt J, Seidler A, Diepgen TL, Bauer A. Occupational ultraviolet light exposure increases the risk for the development of cutaneous squamous cell carcinoma: a systematic review and meta-analysis. *Br.J.Dermatol.* 2011;164:291-307. URL: <https://www.ncbi.nlm.nih.gov/pubmed/21054335>
6. Leiter U, Keim U, Eigentler T, Katalinic A, Holleczek B, Martus P, et al. Incidence, Mortality, and Trends of Nonmelanoma Skin Cancer in Germany. *J Invest Dermatol.* 2017; URL: <https://www.ncbi.nlm.nih.gov/pubmed/28487088>
7. Katalinic A, Kunze U, Schafer T. Epidemiology of cutaneous melanoma and non-melanoma skin cancer in Schleswig-Holstein, Germany: incidence, clinical subtypes, tumour stages and localization (epidemiology of skin cancer). *Br.J.Dermatol.* 2003;149:1200-1206. URL: <https://www.ncbi.nlm.nih.gov/pubmed/14674897>
8. Leiter U, Garbe C. Epidemiology of melanoma and nonmelanoma skin cancer--the role of sunlight. *Adv.Exp.Med.Biol.* 2008;624:89-103. URL: <https://pubmed.ncbi.nlm.nih.gov/18348450/>
9. Rudolph C, Schnoor M, Eisemann N, Katalinic A. Incidence trends of nonmelanoma skin cancer in Germany from 1998 to 2010. *J.Dtsch.Dermatol.Ges.* 2015;13:788-797. URL: <https://pubmed.ncbi.nlm.nih.gov/26213814/>
10. Eisemann N, Jansen L, Castro FA, Chen T, Eberle A, Nennecke A, et al. Survival from non-melanoma skin cancer in Germany. *Br.J.Dermatol.* 2015; URL: <https://pubmed.ncbi.nlm.nih.gov/26676514/>
11. Waldmann A, Nolte S, Weinstock MA, Breitbart EW, Eisemann N, Geller AC, et al. Skin cancer screening participation and impact on melanoma incidence in Germany--an observational study on incidence trends in regions with and without population-based screening. *Br.J.Cancer.* 2012;106:970-974. URL: <https://pubmed.ncbi.nlm.nih.gov/22294187/>
12. Augustin M, Stadler R, Reusch M, Schafer I, Kornek T, Luger T. Skin cancer screening in Germany - perception by the public. *J Dtsch Dermatol Ges.* 2012;10:42-9. URL: <https://pubmed.ncbi.nlm.nih.gov/21923730/>
13. Stang A, Jockel KH. Declining mortality rates for nonmelanoma skin cancers in West Germany, 1968-99. *Br.J.Dermatol.* 2004;150:517-522. URL: <https://pubmed.ncbi.nlm.nih.gov/15030336/>

14. Keim U, van der Pols JC, Williams GM, Green AC. Exclusive development of a single type of keratinocyte skin cancer: evidence from an Australian population-based cohort study. *J Invest Dermatol.* 2015;135:728-33. URL: <https://www.ncbi.nlm.nih.gov/pubmed/25233075>
15. Hollestein LM, de Vries E, Nijsten T. Trends of cutaneous squamous cell carcinoma in the Netherlands: Increased incidence rates, but stable relative survival and mortality 1989-2008. *Eur.J.Cancer.* 2012;48:2046-2053. URL: <https://pubmed.ncbi.nlm.nih.gov/22342554/>
16. Xiang F, Lucas R, Hales S, Neale R. Incidence of nonmelanoma skin cancer in relation to ambient UV radiation in white populations, 1978-2012: empirical relationships. *JAMA Dermatol.* 2014;150:1063-1071. URL: <https://pubmed.ncbi.nlm.nih.gov/25103031/>
17. Raasch BA, Buettner PG. Multiple nonmelanoma skin cancer in an exposed Australian population. *Int.J.Dermatol.* 2002;41:652-658. URL: <https://pubmed.ncbi.nlm.nih.gov/12390187/>
18. Karia PS, Han J, Schmults CD. Cutaneous squamous cell carcinoma: estimated incidence of disease, nodal metastasis, and deaths from disease in the United States, 2012. *J.Am.Acad.Dermatol.* 2013;68:957-966. URL: <https://pubmed.ncbi.nlm.nih.gov/23375456/>
19. Brantsch KD, Meisner C, Schonfisch B, Trilling B, Wehner-Caroli J, Rocken M, et al. Analysis of risk factors determining prognosis of cutaneous squamous-cell carcinoma: a prospective study. *Lancet Oncol.* 2008;9:713-20. URL: <https://pubmed.ncbi.nlm.nih.gov/18617440/>
20. Eigentler T, Leiter U, Häfner H, Garbe C, Röcken M, Breuninger H. Survival of Patients with Cutaneous Squamous Cell Carcinoma: Results of a Prospective Cohort Study. *J Invest Dermatol.* 2017;137(11):2309-2315. URL: <https://pubmed.ncbi.nlm.nih.gov/28736229/>
21. Lewis KG, Weinstock MA. Trends in nonmelanoma skin cancer mortality rates in the United States, 1969 through 2000. *J.Invest Dermatol.* 2007;127:2323-2327. URL: <https://pubmed.ncbi.nlm.nih.gov/17522705/>
22. Strunk T, Szeimies RM. [Actinic keratoses Pathogenesis, clinical aspect and modern therapeutic options]. *Hautarzt.* 2014;65:241-52; quiz 253-4
23. Marinescu A, Stepan AE, Margaritescu C, Marinescu AM, Zavoi RE, Simionescu CE, et al. P53, p16 and Ki67 immunoexpression in cutaneous squamous cell carcinoma and its precursor lesions. *Rom J Morphol Embryol.* 2016;57:691-696. URL: <https://www.ncbi.nlm.nih.gov/pubmed/27833960>
24. El Ghissassi F, Baan R, Straif K, Grosse Y, Secretan B, Bouvard V, et al. A review of human carcinogens--part D: radiation. *Lancet Oncol.* 2009;10(8):751-2. URL: <https://pubmed.ncbi.nlm.nih.gov/19655431/>
25. Berg D, Otley CC. Skin cancer in organ transplant recipients: Epidemiology, pathogenesis, and management. *J Am Acad Dermatol.* 2002;47:1-17; quiz 18-20. URL: <http://www.ncbi.nlm.nih.gov/pubmed/12077575>
26. Euvrard S, Kanitakis J, Claudy A. Skin cancers after organ transplantation. *N Engl J Med.* 2003;348:1681-91. URL: <http://www.ncbi.nlm.nih.gov/pubmed/12711744>
27. Zwald FO, Brown M. Skin cancer in solid organ transplant recipients: advances in therapy and management: part I Epidemiology of skin cancer in solid organ transplant recipients. *J Am Acad Dermatol.* 2011;65:253-61; quiz 262. URL: <http://www.ncbi.nlm.nih.gov/pubmed/21763561>
28. Ulrich C, Schmook T, Nindl I, Meyer T, Sterry W, Stockfleth E. Cutaneous precancers in organ transplant recipients: an old enemy in a new surrounding. *Br.J.Dermatol.* 2003;149 Suppl 66:40-42. URL: <https://www.ncbi.nlm.nih.gov/pubmed/14616348>

29. Harwood C, Mesher D, McGregor J, Mitchell L, Leedham-Green M, Raftery M, et al. A surveillance model for skin cancer in organ transplant recipients: a 22-year prospective study in an ethnically diverse population. *Am J Transplant*. 2013;13(1):119-29. URL: <https://pubmed.ncbi.nlm.nih.gov/23072567/>
30. Marcil I, Stern RS. Risk of developing a subsequent nonmelanoma skin cancer in patients with a history of nonmelanoma skin cancer: a critical review of the literature and meta-analysis. *Arch Dermatol*. 2000;136:1524-30. URL: <http://www.ncbi.nlm.nih.gov/pubmed/11115165>
31. Lott DG, Manz R, Koch C, Lorenz RR. Aggressive behavior of nonmelanotic skin cancers in solid organ transplant recipients. *Transplantation*. 2010;90:683-7. URL: <http://www.ncbi.nlm.nih.gov/pubmed/20808266>
32. Thompson AK, Kelley BF, Prokop LJ, Murad MH, Baum CL. Risk Factors for Cutaneous Squamous Cell Carcinoma Recurrence, Metastasis, and Disease-Specific Death: A Systematic Review and Meta-analysis. *JAMA Dermatol*. 2016;152:419-28. URL: <https://www.ncbi.nlm.nih.gov/pubmed/26762219>
33. Ratushny V, Gober MD, Hick R, Ridky TW, Seykora JT. From keratinocyte to cancer: the pathogenesis and modeling of cutaneous squamous cell carcinoma. *The Journal of clinical investigation*. 2012;122:464-72. URL: <http://www.ncbi.nlm.nih.gov/pubmed/22293185>
34. Fernandez-Figueras MT, Carrato C, Saenz X, Puig L, Musulen E, Ferrandiz C, et al. Actinic keratosis with atypical basal cells (AK I) is the most common lesion associated with invasive squamous cell carcinoma of the skin. *Journal of the European Academy of Dermatology and Venereology : JEADV*. 2015;29:991-7. URL: <http://onlinelibrary.wiley.com/doi/10.1111/jdv.12848/abstract>
35. Stockfleth E, Ferrandiz C, Grob JJ, Leigh I, Pehamberger H, Kerl H. Development of a treatment algorithm for actinic keratoses: a European Consensus. *European journal of dermatology : EJD*. 2008;18:651-9. URL: <http://www.ncbi.nlm.nih.gov/pubmed/18955209>
36. Criscione VD, Weinstock MA, Naylor MF, Luque C, Eide MJ, Bingham SF. Actinic keratoses: Natural history and risk of malignant transformation in the Veterans Affairs Topical Tretinoin Chemoprevention Trial. *Cancer*. 2009;115:2523-30. URL: <http://www.ncbi.nlm.nih.gov/pubmed/19382202>
37. Fuchs A, Marmur E. The kinetics of skin cancer: progression of actinic keratosis to squamous cell carcinoma. *Dermatologic surgery : official publication for American Society for Dermatologic Surgery [et al.]*. 2007;33:1099-101. URL: <http://onlinelibrary.wiley.com/doi/10.1111/j.1524-4725.2007.33224.x/abstract>
38. Heerfordt IM, Nissen CV, Poulsen T, Philipsen PA, Wulf HC. Thickness of Actinic Keratosis Does Not Predict Dysplasia Severity or P53 Expression. *Scientific reports*. 2016;6:33952. URL: <https://www.ncbi.nlm.nih.gov/pmc/articles/PMC5037398/pdf/srep33952.pdf>
39. Jiyad Z, O'Rourke P, Soyer HP, Green AC. Actinic keratosis-related signs predictive of squamous cell carcinoma in renal transplant recipients: a nested case-control study. *The British journal of dermatology*. 2017;176:965-970. URL: <http://www.ncbi.nlm.nih.gov/pubmed/27584866>
40. Pandey S, Mercer SE, Dallas K, Emanuel PO, Goldenberg G. Evaluation of the prognostic significance of follicular extension in actinic keratoses. *The Journal of clinical and aesthetic dermatology*. 2012;5:25-8. URL: https://www.ncbi.nlm.nih.gov/pmc/articles/PMC3366442/pdf/jcad_5_4_25.pdf
41. Vilcea AM, Vilcea ID, Georgescu CV, Patrascu V. The value of the histopathologic examination in the diagnosis and management of the actinic keratosis. *Romanian journal of morphology*

- and embryology = Revue roumaine de morphologie et embryologie. 2012;53:927-34. URL: <http://www.ncbi.nlm.nih.gov/pubmed/23303015>
42. Wallingford SC, Russell SA, Vail A, Proby CM, Lear JT, Green AC. Actinic keratoses, actinic field change and associations with squamous cell carcinoma in renal transplant recipients in Manchester, UK. *Acta dermato-venereologica*. 2015;95:830-4. URL: <https://www.ncbi.nlm.nih.gov/pubmed/25784002>
 43. Smit P, Plomp E, Neumann HA, Thio HB. The influence of the location of the lesion on the absolute risk of the development of skin cancer in a patient with actinic keratosis. *Journal of the European Academy of Dermatology and Venereology : JEADV*. 2013;27:667-71. URL: <http://onlinelibrary.wiley.com/doi/10.1111/jdv.12008/abstract>
 44. Werner RN, Sammain A, Erdmann R, Hartmann V, Stockfleth E, Nast A. The natural history of actinic keratosis: a systematic review. *Br J Dermatol*. 2013;169:502-18. URL: <https://www.ncbi.nlm.nih.gov/pubmed/23647091>
 45. Dirschka T, Pellacani G, Micali G, Malveyh J, Stratigos A, Casari A, et al. A proposed scoring system for assessing the severity of actinic keratosis on the head: actinic keratosis area and severity index. *J Eur Acad Dermatol Venereol*. 2017;31(8):1295-1302. URL: <https://pubmed.ncbi.nlm.nih.gov/28401585/>
 46. Dreno B, Cerio R, Dirschka T, Nart IF, Lear JT, Peris K, et al. A Novel Actinic Keratosis Field Assessment Scale for Grading Actinic Keratosis Disease Severity. *Acta dermato-venereologica*. 2017;97:1108-1113. URL: <http://www.ncbi.nlm.nih.gov/pubmed/28536731>
 47. Brinkman JN, Hajder E, van der Holt B, Den Bakker MA, Hovius SE, Mureau MA. The Effect of Differentiation Grade of Cutaneous Squamous Cell Carcinoma on Excision Margins, Local Recurrence, Metastasis, and Patient Survival: A Retrospective Follow-Up Study. *Ann Plast Surg*. 2015;75:323-6. URL: <https://pubmed.ncbi.nlm.nih.gov/24401812/>
 48. Campoli M, Brodland DG, Zitelli J. A prospective evaluation of the clinical, histologic, and therapeutic variables associated with incidental perineural invasion in cutaneous squamous cell carcinoma. *J Am Acad Dermatol*. 2014;70:630-6. URL: <https://www.ncbi.nlm.nih.gov/pubmed/24433872>
 49. Haisma MS, Plaat BE, Bijl HP, Roodenburg JL, Diercks GF, Romeijn TR, et al. Multivariate analysis of potential risk factors for lymph node metastasis in patients with cutaneous squamous cell carcinoma of the head and neck. *J Am Acad Dermatol*. 2016;75:722-30. URL: <https://www.ncbi.nlm.nih.gov/pubmed/27473455>
 50. Oddone N, Morgan GJ, Palme CE, Perera L, Shannon J, Wong E, et al. Metastatic cutaneous squamous cell carcinoma of the head and neck: the Immunosuppression, Treatment, Extranodal spread, and Margin status (ITEM) prognostic score to predict outcome and the need to improve survival. *Cancer*. 2009;115:1883-91. URL: <https://www.ncbi.nlm.nih.gov/pubmed/19224549>
 51. Petter G, Hausteiner UF. [Histological and clinical prognostic factors in squamous cell carcinoma of the skin A contribution to the multicenter carcinoma study of the association of surgical and oncological dermatology]. *Hautarzt*. 1999;50:412-7. URL: <https://www.ncbi.nlm.nih.gov/pubmed/10427509>
 52. Roozeboom MH, Lohman BG, Westers-Attema A, Nelemans PJ, Botterweck AA, van Marion AM, et al. Clinical and histological prognostic factors for local recurrence and metastasis of cutaneous squamous cell carcinoma: analysis of a defined population. *Acta Derm Venereol*. 2013;93:417-21. URL: <https://www.ncbi.nlm.nih.gov/pubmed/23138613>

53. Schmults CD, Karia PS, Carter JB, Han J, Qureshi AA. Factors predictive of recurrence and death from cutaneous squamous cell carcinoma: a 10-year, single-institution cohort study. *JAMA Dermatol.* 2013;149:541-7. URL: <https://www.ncbi.nlm.nih.gov/pubmed/23677079>
54. Cherpelis BS, Marcusen C, Lang PG. Prognostic factors for metastasis in squamous cell carcinoma of the skin. *Dermatol Surg.* 2002;28:268-73. URL: <https://www.ncbi.nlm.nih.gov/pubmed/11896781>
55. Ch'ng S, Maitra A, Allison RS, Chaplin JM, Gregor RT, Lea R, et al. Parotid and cervical nodal status predict prognosis for patients with head and neck metastatic cutaneous squamous cell carcinoma. *J Surg Oncol.* 2008;98:101-5. URL: <https://www.ncbi.nlm.nih.gov/pubmed/18523982>
56. Ch'ng S, Clark JR, Brunner M, Palme CE, Morgan GJ, Veness MJ. Relevance of the primary lesion in the prognosis of metastatic cutaneous squamous cell carcinoma. *Head Neck.* 2013;35:190-4. URL: <https://www.ncbi.nlm.nih.gov/pubmed/22422542>
57. Wermker K, Kluwig J, Schipmann S, Klein M, Schulze HJ, Hallermann C. Prediction score for lymph node metastasis from cutaneous squamous cell carcinoma of the external ear. *Eur J Surg Oncol.* 2015;41:128-35. URL: <https://www.ncbi.nlm.nih.gov/pubmed/25182221>
58. Manyam BV, Garsa AA, Chin RI, Reddy CA, Gastman B, Thorstad W, et al. A multi-institutional comparison of outcomes of immunosuppressed and immunocompetent patients treated with surgery and radiation therapy for cutaneous squamous cell carcinoma of the head and neck. *Cancer.* 2017;123:2054-2060. URL: <https://pubmed.ncbi.nlm.nih.gov/28171708/>
59. Manyam BV, Gastman B, Zhang AY, Reddy CA, Burkey BB, Scharpf J, et al. Inferior outcomes in immunosuppressed patients with high-risk cutaneous squamous cell carcinoma of the head and neck treated with surgery and radiation therapy. *J Am Acad Dermatol.* 2015;73:221-7. URL: <https://www.ncbi.nlm.nih.gov/pubmed/26028524>
60. Schmitz L, Gupta G, Stücker M, Doerler M, Gambichler T, Welzel J, et al. Evaluation of two histological classifications for actinic keratoses - PRO classification scored highest inter-rater reliability. *J Eur Acad Dermatol Venereol.* 2019;33(6):1092-1097. URL: <https://pubmed.ncbi.nlm.nih.gov/30887613/>
61. Schmitz L, Gambichler T, Gupta G, Stücker M, Stockfleth E, Szeimies R, et al. Actinic keratoses show variable histological basal growth patterns - a proposed classification adjustment. *J Eur Acad Dermatol Venereol.* 2018;32(5):745-751. URL: <https://pubmed.ncbi.nlm.nih.gov/28796914/>
62. Schmitz L, Gambichler T, Kost C, Gupta G, Stücker M, Stockfleth E, et al. Cutaneous squamous cell carcinomas are associated with basal proliferating actinic keratoses. *Br J Dermatol.* 2019;180(4):916-921. URL: <https://pubmed.ncbi.nlm.nih.gov/29526028/>
63. Lee D, Kim B, Yang S, Kim M, Yoon T, Youn S. Histopathological predictor of the progression from actinic keratosis to squamous cell carcinoma: quantitative computer-aided image analysis. *J Eur Acad Dermatol Venereol.* 2021;35(1):116-122. URL: <https://pubmed.ncbi.nlm.nih.gov/32455470/>
64. Conforti C, Giuffrida R, Pizzichetta M, Di Meo N, Magaton-Rizzi G, Zalaudek I. Integrating the concept of field cancerization in the classification and risk assessment of cutaneous squamous cell carcinoma: proposal for a new classification and terminology of keratinocyte skin cancer. *J Eur Acad Dermatol Venereol.* 2019;33(9):e327-e330. URL: <https://pubmed.ncbi.nlm.nih.gov/30980765/>
65. Leitlinienprogramm Onkologie (Deutsche Krebsgesellschaft DK). S3-Leitlinie Prävention von Hautkrebs, Langversion 21. 2021;AWMF Registernummer: 032/052OL

66. Slaughter DP, Southwick HW, Smejkal W. Field cancerization in oral stratified squamous epithelium; clinical implications of multicentric origin. *Cancer*. 1953;6:963-8. URL: <https://www.ncbi.nlm.nih.gov/pubmed/13094644>
67. Braakhuis BJ, Tabor MP, Kummer JA, Leemans CR, Brakenhoff RH. A genetic explanation of Slaughter's concept of field cancerization: evidence and clinical implications. *Cancer Res*. 2003;63:1727-30. URL: <https://www.ncbi.nlm.nih.gov/pubmed/12702551>
68. Malvey J. A new vision of actinic keratosis beyond visible clinical lesions. *J Eur Acad Dermatol Venereol*. 2015;29 Suppl 1:3-8. URL: <https://www.ncbi.nlm.nih.gov/pubmed/25470718>
69. Dirschka T, Gupta G, Micali G, Stockfleth E, Basset-Seguín N, Del Marmol V, et al. Real-world approach to actinic keratosis management: practical treatment algorithm for office-based dermatology. *J Dermatolog Treat*. 2017;28:431-442. URL: <https://www.ncbi.nlm.nih.gov/pubmed/27796187>
70. Einspahr J, Alberts DS, Aickin M, Welch K, Bozzo P, Grogan T, et al. Expression of p53 protein in actinic keratosis, adjacent, normal-appearing, and non-sun-exposed human skin. *Cancer Epidemiol Biomarkers Prev*. 1997;6:583-7. URL: <https://www.ncbi.nlm.nih.gov/pubmed/9264270>
71. Amirnia M, Babaie-Ghazani A, Fakhrjou A, Khodaeiani E, Alikhah H, Naghavi-behzad M, et al. Immunohistochemical study of cyclooxygenase-2 in skin tumors. *J Dermatolog Treat*. 2014;25:380-7. URL: <https://www.ncbi.nlm.nih.gov/pubmed/22667343>
72. Torres A, Storey L, Anders M, Miller RL, Bulbulian BJ, Jin J, et al. Microarray analysis of aberrant gene expression in actinic keratosis: effect of the Toll-like receptor-7 agonist imiquimod. *Br J Dermatol*. 2007;157:1132-47. URL: <https://www.ncbi.nlm.nih.gov/pubmed/17944981>
73. Zaravinos A, Kanellou P, Baritaki S, Bonavida B, Spandidos DA. BRAF and RKIP are significantly decreased in cutaneous squamous cell carcinoma. *Cell Cycle*. 2009;8:1402-8. URL: <https://www.ncbi.nlm.nih.gov/pubmed/19342899>
74. Roewert-Huber J, Stockfleth E, Kerl H. Pathology and pathobiology of actinic (solar) keratosis - an update. *Br J Dermatol*. 2007;157 Suppl 2:18-20. URL: <https://www.ncbi.nlm.nih.gov/pubmed/18067626>
75. Erlendsson AM, Egekvist H, Lorentzen HF, Philipsen PA, Stausbol-Gron B, Stender IM, et al. Actinic keratosis: a cross-sectional study of disease characteristics and treatment patterns in Danish dermatology clinics. *Int J Dermatol*. 2016;55:309-16. URL: <https://www.ncbi.nlm.nih.gov/pubmed/26276415>
76. Figueras Nart I, Cerio R, Dirschka T, Dreno B, Lear JT, Pellacani G, et al. Defining the actinic keratosis field: a literature review and discussion. *J Eur Acad Dermatol Venereol*. 2017; URL: <https://www.ncbi.nlm.nih.gov/pubmed/29055153>
77. Schmitz L, Kahl P, Majores M, Bierhoff E, Stockfleth E, Dirschka T. Actinic keratosis: correlation between clinical and histological classification systems. *J Eur Acad Dermatol Venereol*. 2016;30(8):1303-7. URL: <https://pubmed.ncbi.nlm.nih.gov/26955898/>
78. Wheller L, Soyer HP. Clinical features of actinic keratoses and early squamous cell carcinoma. *Curr Probl Dermatol*. 2015;46:58-63. URL: <https://www.ncbi.nlm.nih.gov/pubmed/25561207>
79. Huerta-Brogeras M, Olmos O, Borbujo J, Hernandez-Nunez A, Castano E, Romero-Mate A, et al. Validation of dermoscopy as a real-time noninvasive diagnostic imaging technique for actinic keratosis. *Arch Dermatol*. 2012;148:1159-64. URL: <https://www.ncbi.nlm.nih.gov/pubmed/23069952>

80. Akay BN, Kocyigit P, Heper AO, Erdem C. Dermatoscopy of flat pigmented facial lesions: diagnostic challenge between pigmented actinic keratosis and lentigo maligna. *Br J Dermatol*. 2010;163:1212-7. URL: <https://www.ncbi.nlm.nih.gov/pubmed/21083845>
81. Lallas A, Pyne J, Kyrgidis A, Andreani S, Argenziano G, Cavaller A, et al. The clinical and dermoscopic features of invasive cutaneous squamous cell carcinoma depend on the histopathological grade of differentiation. *Br J Dermatol*. 2015;172:1308-15. URL: <https://www.ncbi.nlm.nih.gov/pubmed/25363081>
82. Zalaudek I, Argenziano G. Dermoscopy of actinic keratosis, intraepidermal carcinoma and squamous cell carcinoma. *Curr Probl Dermatol*. 2015;46:70-6. URL: <https://www.ncbi.nlm.nih.gov/pubmed/25561209>
83. Lallas A, Tschandl P, Kyrgidis A, Stolz W, Rabinovitz H, Cameron A, et al. Dermoscopic clues to differentiate facial lentigo maligna from pigmented actinic keratosis. *Br J Dermatol*. 2016;174:1079-85. URL: <https://www.ncbi.nlm.nih.gov/pubmed/26784739>
84. Welzel J, Ulrich M, Lange-Aschenfeldt S, Stolz W, Sattler E. S1-Leitlinie 013-076: Konfokale Lasermikroskopie in der Dermatologie. 2017
85. Malvehy J, Alarcon I, Montoya J, Rodriguez-Azaredo R, Puig S. Treatment monitoring of 05% 5-fluorouracil and 10% salicylic acid in clinical and subclinical actinic keratoses with the combination of optical coherence tomography and reflectance confocal microscopy. *J Eur Acad Dermatol Venereol*. 2016;30:258-65. URL: <https://www.ncbi.nlm.nih.gov/pubmed/26538346>
86. Malvehy J, Roldan-Marin R, Iglesias-Garcia P, Diaz A, Puig S. Monitoring treatment of field cancerisation with 3% diclofenac sodium 25% hyaluronic acid by reflectance confocal microscopy: a histologic correlation. *Acta Derm Venereol*. 2015;95:45-50. URL: <https://www.ncbi.nlm.nih.gov/pubmed/24696069>
87. Ulrich M, Alarcon I, Malvehy J, Puig S. In vivo reflectance confocal microscopy characterization of field-directed 5-fluorouracil 05%/salicylic acid 10% in actinic keratosis. *Dermatology*. 2015;230:193-8. URL: <https://www.ncbi.nlm.nih.gov/pubmed/25721522>
88. Ulrich M, Krueger-Corcoran D, Roewert-Huber J, Sterry W, Stockfleth E, Astner S. Reflectance confocal microscopy for noninvasive monitoring of therapy and detection of subclinical actinic keratoses. *Dermatology*. 2010;220:15-24. URL: <https://www.ncbi.nlm.nih.gov/pubmed/19907131>
89. Ulrich M, Reinhold U, Skov T, Elvang Sondergaard R, Guitera P. Histological examination confirms clinical clearance of actinic keratoses following treatment with ingenol mebutate 005% gel. *Br J Dermatol*. 2017;176:71-80. URL: <https://www.ncbi.nlm.nih.gov/pubmed/27518593>
90. Boone MA, Marneffe A, Suppa M, Miyamoto M, Alarcon I, Hofmann-Wellenhof R, et al. High-definition optical coherence tomography algorithm for the discrimination of actinic keratosis from normal skin and from squamous cell carcinoma. *J Eur Acad Dermatol Venereol*. 2015;29:1606-15. URL: <https://www.ncbi.nlm.nih.gov/pubmed/25656269>
91. Friis KBE, Themstrup L, Jemec GBE. Optical coherence tomography in the diagnosis of actinic keratosis-A systematic review. *Photodiagnosis Photodyn Ther*. 2017;18:98-104. URL: <https://www.ncbi.nlm.nih.gov/pubmed/28188920>
92. Schuh S, Kaestle R, Sattler EC, Welzel J. Optical coherence tomography of actinic keratoses and basal cell carcinomas - differentiation by quantification of signal intensity and layer thickness. *J Eur Acad Dermatol Venereol*. 2016;30:1321-6. URL: <https://www.ncbi.nlm.nih.gov/pubmed/26915996>

93. Maier T, Cekovic D, Ruzicka T, Sattler EC, Berking C. Treatment monitoring of topical ingenol mebutate in actinic keratoses with the combination of optical coherence tomography and reflectance confocal microscopy: a case series. *Br J Dermatol*. 2015;172:816-8. URL: <https://www.ncbi.nlm.nih.gov/pubmed/25070046>
94. Markowitz O, Schwartz M, Feldman E, Bieber A, Bienenfeld A, Nandan N, et al. Defining Field Cancerization of the Skin Using Noninvasive Optical Coherence Tomography Imaging to Detect and Monitor Actinic Keratosis in Ingenol Mebutate 0015%- Treated Patients. *J Clin Aesthet Dermatol*. 2016;9:18-25. URL: <https://www.ncbi.nlm.nih.gov/pubmed/27386042>
95. Themstrup L, Banzhaf CA, Mogensen M, Jemec GB. Optical coherence tomography imaging of non-melanoma skin cancer undergoing photodynamic therapy reveals subclinical residual lesions. *Photodiagnosis Photodyn Ther*. 2014;11:7-12. URL: <https://www.ncbi.nlm.nih.gov/pubmed/24280439>
96. Ulrich M, Lange-Asschenfeldt S, Skak K, Skov T, Osterdal ML, Rowert-Huber HJ, et al. Biological Effects of Ingenol Mebutate Gel in Moderate to Severe Actinic Fields Assessed by Reflectance Confocal Microscopy: A Phase I Study. *J Drugs Dermatol*. 2016;15:1181-1189. URL: <https://www.ncbi.nlm.nih.gov/pubmed/27741334>
97. Nguyen KP, Peppelman M, Hoogedoorn L, Van Erp PE, Gerritsen MP. The current role of in vivo reflectance confocal microscopy within the continuum of actinic keratosis and squamous cell carcinoma: a systematic review. *Eur J Dermatol*. 2016;26:549-565. URL: <https://www.ncbi.nlm.nih.gov/pubmed/28007674>
98. Ulrich M, Maltusch A, Rius-Diaz F, Rowert-Huber J, Gonzalez S, Sterry W, et al. Clinical applicability of in vivo reflectance confocal microscopy for the diagnosis of actinic keratoses. *Dermatol Surg*. 2008;34:610-9. URL: <https://www.ncbi.nlm.nih.gov/pubmed/18261097>
99. Stratigos A, Garbe C, Lebbe C, Malvehy J, del Marmol V, Pehamberger H, et al. Diagnosis and treatment of invasive squamous cell carcinoma of the skin: European consensus-based interdisciplinary guideline. *Eur J Cancer*. 2015;51:1989-2007. URL: <https://www.ncbi.nlm.nih.gov/pubmed/26219687>
100. Diepgen TL, Drexler H, Elsner P, Schmitt J. [UV-irradiation-induced skin cancer as a new occupational disease]. *Hautarzt*. 2015;66:154-9. URL: <https://www.ncbi.nlm.nih.gov/pubmed/25737435>
101. Bilen N, Dal H, Kaur AC. Scraping cytology in the diagnosis of malignant squamous neoplasms of the skin. *Acta Cytol*. 2000;44:101-3. URL: <https://www.ncbi.nlm.nih.gov/pubmed/10667170>
102. Christensen E, Bofin A, Gudmundsdottir I, Skogvoll E. Cytological diagnosis of basal cell carcinoma and actinic keratosis, using Papanicolaou and May-Grunwald-Giemsa stained cutaneous tissue smear. *Cytopathology*. 2008;19:316-22. URL: <https://www.ncbi.nlm.nih.gov/pubmed/17916094>
103. Vega-Memije E, De Larios NM, Waxtein LM, Dominguez-Soto L. Cytodiagnosis of cutaneous basal and squamous cell carcinoma. *Int J Dermatol*. 2000;39:116-20. URL: <https://www.ncbi.nlm.nih.gov/pubmed/10692060>
104. Xing Y, Cromwell KD, Cormier JN. Review of diagnostic imaging modalities for the surveillance of melanoma patients. *Dermatol Res Pract*. 2012;2012:941921. URL: <https://www.ncbi.nlm.nih.gov/pubmed/21876688>
105. de Bree R, Takes RP, Castelijns JA, Medina JE, Stoeckli SJ, Mancuso AA, et al. Advances in diagnostic modalities to detect occult lymph node metastases in head and neck squamous

- cell carcinoma. *Head Neck*. 2015;37:1829-39. URL: <https://www.ncbi.nlm.nih.gov/pubmed/24954811>
106. Yoon DY, Hwang HS, Chang SK, Rho YS, Ahn HY, Kim JH, et al. CT, MR, US, 18F-FDG PET/CT, and their combined use for the assessment of cervical lymph node metastases in squamous cell carcinoma of the head and neck. *Eur Radiol*. 2009;19:634-42. URL: <https://www.ncbi.nlm.nih.gov/pubmed/18843493>
107. Teymoortash A, Schultz E, Werner J. Klinische Bedeutung parotidealer Metastasen von Plattenepithelkarzinomen der Kopfhaut. *Der Hautarzt*. 2007;58:323-327. URL: <https://doi.org/10.1007/s00105-006-1275-8>, <https://link.springer.com/content/pdf/10.1007%2Fs00105-006-1275-8.pdf>
108. Liao LJ, Lo WC, Hsu WL, Wang CT, Lai MS. Detection of cervical lymph node metastasis in head and neck cancer patients with clinically NO neck-a meta-analysis comparing different imaging modalities. *BMC Cancer*. 2012;12:236. URL: <https://www.ncbi.nlm.nih.gov/pubmed/22691269>
109. Heusch P, Sproll C, Buchbender C, Rieser E, Terjung J, Antke C, et al. Diagnostic accuracy of ultrasound, (1)(8)F-FDG-PET/CT, and fused (1)(8)F-FDG-PET-MR images with DWI for the detection of cervical lymph node metastases of HNSCC. *Clin Oral Investig*. 2014;18:969-78. URL: <https://www.ncbi.nlm.nih.gov/pubmed/23892450>
110. Diederich S. [Radiological diagnosis of pulmonary metastases: imaging findings and diagnostic accuracy]. *Radiologe*. 2004;44:663-70. URL: <https://www.ncbi.nlm.nih.gov/pubmed/15232688>
111. Fischbach F, Knollmann F, Griesshaber V, Freund T, Akkol E, Felix R. Detection of pulmonary nodules by multislice computed tomography: improved detection rate with reduced slice thickness. *Eur Radiol*. 2003;13:2378-83. URL: <https://www.ncbi.nlm.nih.gov/pubmed/12743736>
112. Rinne D, Baum RP, Hor G, Kaufmann R. Primary staging and follow-up of high risk melanoma patients with whole-body 18F-fluorodeoxyglucose positron emission tomography: results of a prospective study of 100 patients. *Cancer*. 1998;82:1664-71. URL: <https://www.ncbi.nlm.nih.gov/pubmed/9576286>
113. Ruiz ES, Karia PS, Morgan FC, Schmultz CD. The positive impact of radiologic imaging on high-stage cutaneous squamous cell carcinoma management. *J Am Acad Dermatol*. 2017;76:217-225. URL: <https://pubmed.ncbi.nlm.nih.gov/27707594/>
114. de Bree R, Haigentz M, Silver CE, Paccagnella D, Hamoir M, Hartl DM, et al. Distant metastases from head and neck squamous cell carcinoma Part II Diagnosis. *Oral Oncol*. 2012;48:780-6. URL: <https://www.ncbi.nlm.nih.gov/pubmed/22520053>
115. Rohde M, Dyrvig AK, Johansen J, Sorensen JA, Gerke O, Nielsen AL, et al. 18F-fluoro-deoxy-glucose-positron emission tomography/computed tomography in diagnosis of head and neck squamous cell carcinoma: a systematic review and meta-analysis. *Eur J Cancer*. 2014;50:2271-9. URL: <https://www.ncbi.nlm.nih.gov/pubmed/25011659>
116. Schlittenbauer T, Zeilinger M, Nkenke E, Kreissel S, Wurm MC, Lell M, et al. Positron emission tomography-computed tomography versus positron emission tomography-magnetic resonance imaging for diagnosis of oral squamous cell carcinoma: A pilot study. *J Craniomaxillofac Surg*. 2015;43:2129-35. URL: <https://www.ncbi.nlm.nih.gov/pubmed/26498514>
117. Senft A, Hoekstra OS, Witte BI, Leemans CR, de Bree R. Screening for distant metastases in head and neck cancer patients using FDG-PET and chest CT: validation of an

- algorithm. *Eur Arch Otorhinolaryngol*. 2016;273:2643-50. URL: <https://www.ncbi.nlm.nih.gov/pubmed/26350882>
118. Lonneux M, Hamoir M, Reyckler H, Maingon P, Duvillard C, Calais G, et al. Positron emission tomography with [18F]fluorodeoxyglucose improves staging and patient management in patients with head and neck squamous cell carcinoma: a multicenter prospective study. *J Clin Oncol*. 2010;28:1190-5. URL: <https://www.ncbi.nlm.nih.gov/pubmed/20124179>
119. Fujiwara M, Suzuki T, Takiguchi T, Fukamizu H, Tokura Y. Evaluation of positron emission tomography imaging to detect lymph node metastases in patients with high-risk cutaneous squamous cell carcinoma. *The Journal of Dermatology*. 2016;43:1314-1320. URL: <http://dx.doi.org/10.1111/1346-8138.13403>
120. Mahajan S, Barker C, Singh B, Pandit-Taskar N. Clinical value of 18F-FDG-PET/CT in staging cutaneous squamous cell carcinoma. *Nucl Med Commun*. 2019;40(7):744-751. URL: <https://pubmed.ncbi.nlm.nih.gov/31095044/>
121. Mahajan S, Barker C, Mauguen A, Singh B, Pandit-Taskar N. Restaging [18F] fludeoxyglucose positron emission tomography/computed tomography scan in recurrent cutaneous squamous cell carcinoma: Diagnostic performance and prognostic significance. *J Am Acad Dermatol*. 2020;82(4):878-886. URL: <https://pubmed.ncbi.nlm.nih.gov/31562942/>
122. Gupta AK, Paquet M, Villanueva E, Brintnell W. Interventions for actinic keratoses. *Cochrane Database Syst Rev*. 2012;12:Cd004415. URL: <https://www.ncbi.nlm.nih.gov/pubmed/23235610>
123. Werner RN, Stockfleth E, Connolly SM, Correia O, Erdmann R, Foley P, et al. Evidence- and consensus-based (S3) Guidelines for the Treatment of Actinic Keratosis - International League of Dermatological Societies in cooperation with the European Dermatology Forum - Short version. *J Eur Acad Dermatol Venereol*. 2015;29:2069-79. URL: <https://www.ncbi.nlm.nih.gov/pubmed/26370093>
124. Marks R, Rennie G, Selwood TS. Malignant transformation of solar keratoses to squamous cell carcinoma. *Lancet*. 1988;1:795-7. URL: <https://www.ncbi.nlm.nih.gov/pubmed/2895318>
125. Quaedvlieg PJ, Tirsi E, Thissen MR, Krekels GA. Actinic keratosis: how to differentiate the good from the bad ones?. *Eur J Dermatol*. 2006;16:335-9. URL: <https://www.ncbi.nlm.nih.gov/pubmed/16935787>
126. Schmitz L, Brehmer A, Falkenberg C, Gambichler T, Heppt M, Steeb T, et al. Treatment-resistant actinic keratoses are characterized by distinct clinical and histological features. *Ital J Dermatol Venerol*. 2021;156(2):213-219. URL: <https://pubmed.ncbi.nlm.nih.gov/33960752/>
127. Vegter S, Tolley K. A network meta-analysis of the relative efficacy of treatments for actinic keratosis of the face or scalp in Europe. *PLoS One*. 2014;9:e96829. URL: <https://www.ncbi.nlm.nih.gov/pubmed/24892649>
128. Kiefer C, Sturtz S, Bender R. Indirect Comparisons and Network Meta-Analyses. *Dtsch Arztebl Int*. 2015;112:803-8. URL: <https://www.ncbi.nlm.nih.gov/pubmed/26634940>
129. Steeb T, Wessely A, Schmitz L, Heppt F, Kirchberger M, Berking C, et al. Interventions for Actinic Keratosis in Nonscalp and Nonface Localizations: Results from a Systematic Review with Network Meta-Analysis. *J Invest Dermatol*. 2021;141(2):345-354.e8. URL: <https://pubmed.ncbi.nlm.nih.gov/32645365/>
130. Ulrich M, Pellacani G, Ferrandiz C, Lear JT. Evidence for field cancerisation treatment of actinic keratoses with topical diclofenac in hyaluronic acid. *Eur J Dermatol*. 2014;24:158-167

131. Heppt M, Steeb T, Ruzicka T, Berking C. Cryosurgery combined with topical interventions for actinic keratosis: a systematic review and meta-analysis. *Br J Dermatol*. 2019;180(4):740-748. URL: <https://pubmed.ncbi.nlm.nih.gov/30447074/>
132. Heppt M, Steeb T, Leiter U, Berking C. Efficacy of photodynamic therapy combined with topical interventions for the treatment of actinic keratosis: a meta-analysis. *J Eur Acad Dermatol Venereol*. 2019;33(5):863-873. URL: <https://pubmed.ncbi.nlm.nih.gov/30710390/>
133. Steeb T, Koch E, Wessely A, Wiest L, Schmitz L, Berking C, et al. Chemical peelings for the treatment of actinic keratosis: a systematic review and meta-analysis. *J Eur Acad Dermatol Venereol*. 2021;35(3):641-649. URL: <https://pubmed.ncbi.nlm.nih.gov/32745330/>
134. Steeb T, Schlager J, Kohl C, Ruzicka T, Heppt M, Berking C. Laser-assisted photodynamic therapy for actinic keratosis: A systematic review and meta-analysis. *J Am Acad Dermatol*. 2019;80(4):947-956. URL: <https://pubmed.ncbi.nlm.nih.gov/30267719/>
135. Foley P, Merlin K, Cumming S, Campbell J, Crouch R, Harrison S, et al. A comparison of cryotherapy and imiquimod for treatment of actinic keratoses: lesion clearance, safety, and skin quality outcomes. *J Drugs Dermatol*. 2011;10:1432-8. URL: <https://www.ncbi.nlm.nih.gov/pubmed/22134568>
136. Krawtchenko N, Roewert-Huber J, Ulrich M, Mann I, Sterry W, Stockfleth E. A randomised study of topical 5% imiquimod vs topical 5-fluorouracil vs cryosurgery in immunocompetent patients with actinic keratoses: a comparison of clinical and histological outcomes including 1-year follow-up. *Br J Dermatol*. 2007;157 Suppl 2:34-40. URL: <https://www.ncbi.nlm.nih.gov/pubmed/18067630>
137. Morton C, Campbell S, Gupta G, Keohane S, Lear J, Zaki I, et al. Intraindividual, right-left comparison of topical methyl aminolaevulinate-photodynamic therapy and cryotherapy in subjects with actinic keratoses: a multicentre, randomized controlled study. *Br J Dermatol*. 2006;155:1029-36. URL: <https://www.ncbi.nlm.nih.gov/pubmed/17034536>
138. Simon JC, Dominicus R, Karl L, Rodriguez R, Willers C, Dirschka T. A prospective randomized exploratory study comparing the efficacy of once-daily topical 05% 5-fluorouracil in combination with 100% salicylic acid (5-FU/SA) vs cryosurgery for the treatment of hyperkeratotic actinic keratosis. *J Eur Acad Dermatol Venereol*. 2015;29:881-9. URL: <https://www.ncbi.nlm.nih.gov/pubmed/25257941>
139. Zane C, Facchinetti E, Rossi MT, Specchia C, Ortel B, Calzavara-Pinton P. Cryotherapy is preferable to ablative CO2 laser for the treatment of isolated actinic keratoses of the face and scalp: a randomized clinical trial. *Br J Dermatol*. 2014;170:1114-21. URL: <https://www.ncbi.nlm.nih.gov/pubmed/24472087>
140. Kaufmann R, Spelman L, Weightman W, Reifenberger J, Szeimies RM, Verhaeghe E, et al. Multicentre intraindividual randomized trial of topical methyl aminolaevulinate-photodynamic therapy vs cryotherapy for multiple actinic keratoses on the extremities. *Br J Dermatol*. 2008;158:994-9. URL: <https://www.ncbi.nlm.nih.gov/pubmed/18341663>
141. Askew DA, Mickan SM, Soyer HP, Wilkinson D. Effectiveness of 5-fluorouracil treatment for actinic keratosis--a systematic review of randomized controlled trials. *Int J Dermatol*. 2009;48:453-63. URL: <https://www.ncbi.nlm.nih.gov/pubmed/19416373>
142. Freeman M, Vinciullo C, Francis D, Spelman L, Nguyen R, Fergin P, et al. A comparison of photodynamic therapy using topical methyl aminolevulinate (Metvix) with single cycle cryotherapy in patients with actinic keratosis: a prospective, randomized study. *J Dermatolog Treat*. 2003;14:99-106. URL: <https://www.ncbi.nlm.nih.gov/pubmed/12775317>

143. Szeimies RM, Karrer S, Radakovic-Fijan S, Tanew A, Calzavara-Pinton PG, Zane C, et al. Photodynamic therapy using topical methyl 5-aminolevulinate compared with cryotherapy for actinic keratosis: A prospective, randomized study. *J Am Acad Dermatol*. 2002;47:258-62. URL: <https://www.ncbi.nlm.nih.gov/pubmed/12140473>
144. Holzer G, Pinkowicz A, Radakovic S, Schmidt JB, Tanew A. Randomized controlled trial comparing 35% trichloroacetic acid peel and 5-aminolaevulinic acid photodynamic therapy for treating multiple actinic keratosis. *Br J Dermatol*. 2017;176:1155-1161. URL: <https://www.ncbi.nlm.nih.gov/pubmed/28012181>
145. Lawrence N, Cox S, Cockerell C, Freeman R, Cruz P. A comparison of the efficacy and safety of Jessner's solution and 35% trichloroacetic acid vs 5% fluorouracil in the treatment of widespread facial actinic keratoses. *Arch Dermatol*. 1995;131(2):176-81. URL: <https://pubmed.ncbi.nlm.nih.gov/7857114/>
146. Di Nuzzo S, Cortelazzi C, Boccaletti V, Zucchi A, Conti M, Montanari P, et al. Comparative study of trichloroacetic acid vs photodynamic therapy with topical 5-aminolevulinic acid for actinic keratosis of the scalp. *Photodermatol Photoimmunol Photomed*. 2015;31(5):233-8. URL: <https://pubmed.ncbi.nlm.nih.gov/25660106/>
147. Coleman WP, Yarborough JM, Mandy SH. Dermabrasion for prophylaxis and treatment of actinic keratoses. *Dermatol Surg*. 1996;22:17-21. URL: <https://www.ncbi.nlm.nih.gov/pubmed/8556252>
148. Salehi Farid A, Niknam S, Gholami K, Tavakolpour S, Teimourpour A, Daneshpazhooh M, et al. Comparing efficacy and safety of potassium hydroxide 5% solution with 5-fluorouracil cream in patients with actinic keratoses: a randomized controlled trial. *J Dermatolog Treat*. 2020;;1-7. URL: <https://pubmed.ncbi.nlm.nih.gov/32875946/>
149. Reinhold U, Bai-Habelski J, Abeck D, Denfeld R, Dominicus R, Fischer T, et al. [Potassium hydroxide 5% solution in actinic keratosis : A novel therapeutic approach in the lesion-directed treatment]. *Hautarzt*. 2021;; URL: <https://pubmed.ncbi.nlm.nih.gov/34387709/>
150. Ostertag JU, Quaedvlieg PJ, van der Geer S, Nelemans P, Christianen ME, Neumann MH, et al. A clinical comparison and long-term follow-up of topical 5-fluorouracil versus laser resurfacing in the treatment of widespread actinic keratoses. *Lasers Surg Med*. 2006;38:731-9. URL: <https://www.ncbi.nlm.nih.gov/pubmed/16912977>
151. Sierra H, Yelamos O, Cordova M, Chen CJ, Rajadhyaksha M. Reflectance confocal microscopy-guided laser ablation of basal cell carcinomas: initial clinical experience. *J Biomed Opt*. 2017;22:1-13. URL: <https://www.ncbi.nlm.nih.gov/pubmed/28831793>
152. Sierra H, Damanpour S, Hibler B, Nehal K, Rossi A, Rajadhyaksha M. Confocal imaging of carbon dioxide laser-ablated basal cell carcinomas: An ex-vivo study on the uptake of contrast agent and ablation parameters. *Lasers Surg Med*. 2016;48:133-9. URL: <https://www.ncbi.nlm.nih.gov/pubmed/26392001>
153. Hantash BM, Stewart DB, Cooper ZA, Rehms WE, Koch RJ, Swetter SM. Facial resurfacing for nonmelanoma skin cancer prophylaxis. *Arch Dermatol*. 2006;142:976-82. URL: <https://www.ncbi.nlm.nih.gov/pubmed/16924046>
154. Nguyen BT, Gan SD, Konnikov N, Liang CA. Treatment of superficial basal cell carcinoma and squamous cell carcinoma in situ on the trunk and extremities with ablative fractional laser-assisted delivery of topical fluorouracil. *J Am Acad Dermatol*. 2015;72:558-60. URL: <https://www.ncbi.nlm.nih.gov/pubmed/25687314>

155. Karmisholt KE, Haedersdal M. Ablative fractional laser intensifies treatment outcome of scalp actinic keratoses with ingenol mebutate: a case report. *J Eur Acad Dermatol Venereol*. 2016;30:854-5. URL: <https://www.ncbi.nlm.nih.gov/pubmed/25732962>
156. Ko DY, Jeon SY, Kim KH, Song KH. Fractional erbium: YAG laser-assisted photodynamic therapy for facial actinic keratoses: a randomized, comparative, prospective study. *J Eur Acad Dermatol Venereol*. 2014;28:1529-39. URL: <https://www.ncbi.nlm.nih.gov/pubmed/24341367>
157. Togsverd-Bo K, Haak CS, Thaysen-Petersen D, Wulf HC, Anderson RR, Haedersdal M. Intensified photodynamic therapy of actinic keratoses with fractional CO2 laser: a randomized clinical trial. *Br J Dermatol*. 2012;166:1262-9. URL: <https://www.ncbi.nlm.nih.gov/pubmed/22348388>
158. Helsing P, Togsverd-Bo K, Veierod MB, Mork G, Haedersdal M. Intensified fractional CO2 laser-assisted photodynamic therapy vs laser alone for organ transplant recipients with multiple actinic keratoses and wart-like lesions: a randomized half-side comparative trial on dorsal hands. *Br J Dermatol*. 2013;169:1087-92. URL: <https://pubmed.ncbi.nlm.nih.gov/23855503/>
159. Lapidoth M, Adatto M, Halachmi S. Treatment of actinic keratoses and photodamage with non-contact fractional 1540-nm laser quasi-ablation: an ex vivo and clinical evaluation. *Lasers Med Sci*. 2013;28:537-42. URL: <https://www.ncbi.nlm.nih.gov/pubmed/22538843>
160. Alexiades-Armenakas MR, Geronemus RG. Laser-mediated photodynamic therapy of actinic keratoses. *Arch Dermatol*. 2003;139:1313-20. URL: <https://www.ncbi.nlm.nih.gov/pubmed/14568836>
161. Moskalik K, Kozlow A, Demin E, Boiko E. Powerful neodymium laser radiation for the treatment of facial carcinoma: 5 year follow-up data. *Eur J Dermatol*. 2010;20:738-42. URL: <https://www.ncbi.nlm.nih.gov/pubmed/21056940>
162. Gollnick H, Dirschka T, Ostendorf R, Kerl H, Kunstfeld R. Long-term clinical outcomes of imiquimod 5% cream vs diclofenac 3% gel for actinic keratosis on the face or scalp: a pooled analysis of two randomized controlled trials. *J Eur Acad Dermatol Venereol*. 2020;34(1):82-89. URL: <https://pubmed.ncbi.nlm.nih.gov/31407414/>
163. Stockfleth E, Harwood C, Serra-Guillén C, Larsson T, Østerdal M, Skov T. Phase IV head-to-head randomized controlled trial comparing ingenol mebutate 0.015% gel with diclofenac sodium 3% gel for the treatment of actinic keratosis on the face or scalp. *Br J Dermatol*. 2018;178(2):433-442. URL: <https://pubmed.ncbi.nlm.nih.gov/29030864/>
164. Ezzedine K, Painchault C, Brignone M. Systematic Literature Review and Network Meta-analysis of the Efficacy and Acceptability of Interventions in Actinic Keratoses. *Acta Derm Venereol*. 2021;101(1):adv00358. URL: <https://pubmed.ncbi.nlm.nih.gov/33170301/>
165. Akarsu S, Aktan S, Atahan A, Koc P, Ozkan S. Comparison of topical 3% diclofenac sodium gel and 5% imiquimod cream for the treatment of actinic keratoses. *Clin Exp Dermatol*. 2011;36:479-84. URL: <https://www.ncbi.nlm.nih.gov/pubmed/21418281>
166. Gebauer K, Brown P, Varigos G. Topical diclofenac in hyaluronan gel for the treatment of solar keratoses. *Australas J Dermatol*. 2003;44:40-3. URL: <https://www.ncbi.nlm.nih.gov/pubmed/12581080>
167. Kose O, Koc E, Erbil AH, Caliskan E, Kurumlu Z. Comparison of the efficacy and tolerability of 3% diclofenac sodium gel and 5% imiquimod cream in the treatment of actinic keratosis. *J Dermatolog Treat*. 2008;19:159-63. URL: <https://www.ncbi.nlm.nih.gov/pubmed/18569272>

168. McEwan LE, Smith JG. Topical diclofenac/hyaluronic acid gel in the treatment of solar keratoses. *Australas J Dermatol*. 1997;38:187-9. URL: <https://www.ncbi.nlm.nih.gov/pubmed/9431711>
169. Pflugfelder A, Welter AK, Leiter U, Weide B, Held L, Eigentler TK, et al. Open label randomized study comparing 3 months vs 6 months treatment of actinic keratoses with 3% diclofenac in 25% hyaluronic acid gel: a trial of the German Dermatologic Cooperative Oncology Group. *J Eur Acad Dermatol Venereol*. 2012;26:48-53. URL: <https://www.ncbi.nlm.nih.gov/pubmed/21414035>
170. Rivers JK, Arlette J, Shear N, Guenther L, Carey W, Poulin Y. Topical treatment of actinic keratoses with 30% diclofenac in 25% hyaluronan gel. *Br J Dermatol*. 2002;146:94-100. URL: <https://www.ncbi.nlm.nih.gov/pubmed/11841372>
171. Segatto MM, Dornelles SI, Silveira VB, Frantz Gde O. Comparative study of actinic keratosis treatment with 3% diclofenac sodium and 5% 5-fluorouracil. *An Bras Dermatol*. 2013;88:732-8. URL: <https://www.ncbi.nlm.nih.gov/pubmed/24173178>
172. Ulrich C, Johannsen A, Rowert-Huber J, Ulrich M, Sterry W, Stockfleth E. Results of a randomized, placebo-controlled safety and efficacy study of topical diclofenac 3% gel in organ transplant patients with multiple actinic keratoses. *Eur J Dermatol*. 2010;20:482-8. URL: <https://www.ncbi.nlm.nih.gov/pubmed/20507841>
173. Wolf JE, Taylor JR, Tschen E, Kang S. Topical 30% diclofenac in 25% hyaluronan gel in the treatment of actinic keratoses. *Int J Dermatol*. 2001;40:709-13. URL: <https://www.ncbi.nlm.nih.gov/pubmed/11737438>
174. Zane C, Facchinetti E, Rossi MT, Specchia C, Calzavara-Pinton PG. A randomized clinical trial of photodynamic therapy with methyl aminolaevulinate vs diclofenac 3% plus hyaluronic acid gel for the treatment of multiple actinic keratoses of the face and scalp. *Br J Dermatol*. 2014;170:1143-50. URL: <https://www.ncbi.nlm.nih.gov/pubmed/24506666>
175. Stockfleth E, Kerl H, Zwingers T, Willers C. Low-dose 5-fluorouracil in combination with salicylic acid as a new lesion-directed option to treat topically actinic keratoses: histological and clinical study results. *Br J Dermatol*. 2011;165:1101-8. URL: <https://www.ncbi.nlm.nih.gov/pubmed/21517801>
176. Stockfleth E, Zwingers T, Willers C. Recurrence rates and patient assessed outcomes of 05% 5-fluorouracil in combination with salicylic acid treating actinic keratoses. *Eur J Dermatol*. 2012;22:370-4. URL: <https://www.ncbi.nlm.nih.gov/pubmed/22494856>
177. Jansen M, Kessels J, Nelemans P, Kouloubis N, Arits A, van Pelt H, et al. Randomized Trial of Four Treatment Approaches for Actinic Keratosis. *N Engl J Med*. 2019;380(10):935-946. URL: <https://pubmed.ncbi.nlm.nih.gov/30855743/>
178. Wu Y, Tang N, Cai L, Li Q. Relative efficacy of 5-fluorouracil compared with other treatments among patients with actinic keratosis: A network meta-analysis. *Dermatol Ther*. 2019;32(3):e12822. URL: <https://pubmed.ncbi.nlm.nih.gov/30638294/>
179. Loven K, Stein L, Furst K, Levy S. Evaluation of the efficacy and tolerability of 05% fluorouracil cream and 5% fluorouracil cream applied to each side of the face in patients with actinic keratosis. *Clin Ther*. 2002;24:990-1000. URL: <https://www.ncbi.nlm.nih.gov/pubmed/12117087>
180. Pomerantz H, Hogan D, Eilers D, Swetter SM, Chen SC, Jacob SE, et al. Long-term Efficacy of Topical Fluorouracil Cream, 5%, for Treating Actinic Keratosis: A Randomized Clinical Trial. *JAMA Dermatol*. 2015;151:952-60. URL: <https://www.ncbi.nlm.nih.gov/pubmed/25950503>

181. Tanghetti E, Werschler P. Comparison of 5% 5-fluorouracil cream and 5% imiquimod cream in the management of actinic keratoses on the face and scalp. *J Drugs Dermatol*. 2007;6:144-7. URL: <https://www.ncbi.nlm.nih.gov/pubmed/17373172>
182. Smith S, Piacquadio D, Morhenn V, Atkin D, Fitzpatrick R. Short incubation PDT versus 5-FU in treating actinic keratoses. *J Drugs Dermatol*. 2003;2:629-35. URL: <https://www.ncbi.nlm.nih.gov/pubmed/14711141>
183. Jansen M, Kessels J, Merks I, Nelemans P, Kelleners-Smeets N, Mosterd K, et al. A trial-based cost-effectiveness analysis of topical 5-fluorouracil vs imiquimod vs ingenol mebutate vs methyl aminolaevulinate conventional photodynamic therapy for the treatment of actinic keratosis in the head and neck area performed in the Netherlands. *Br J Dermatol*. 2020;183(4):738-744. URL: <https://pubmed.ncbi.nlm.nih.gov/31961446/>
184. Dohil M. Efficacy, Safety, and Tolerability of 4% 5-Fluorouracil Cream in a Novel Patented Aqueous Cream Containing Peanut Oil Once Daily Compared With 5% 5-Fluorouracil Cream Twice Daily: Meeting the Challenge in the Treatment of Actinic Keratosis. *J Drugs Dermatol*. 2016;15(10):1218-1224. URL: <https://pubmed.ncbi.nlm.nih.gov/27741339/>
185. Jorizzo J, Stewart D, Bucko A, Davis SA, Espy P, Hino P, et al. Randomized trial evaluating a new 05% fluorouracil formulation demonstrates efficacy after 1-, 2-, or 4-week treatment in patients with actinic keratosis. *Cutis*. 2002;70:335-9. URL: <https://www.ncbi.nlm.nih.gov/pubmed/12502122>
186. Weiss J, Menter A, Hevia O, Jones T, Ling M, Rist T, et al. Effective treatment of actinic keratosis with 05% fluorouracil cream for 1, 2, or 4 weeks. *Cutis*. 2002;70:22-9. URL: <https://www.ncbi.nlm.nih.gov/pubmed/12353677>
187. Rahvar M, Lamel SA, Maibach HI. Randomized, vehicle-controlled trials of topical 5-fluorouracil therapy for actinic keratosis treatment: an overview. *Immunotherapy*. 2012;4:939-45. URL: <https://www.ncbi.nlm.nih.gov/pubmed/23046237>
188. Jorizzo J, Weiss J, Furst K, VandePol C, Levy SF. Effect of a 1-week treatment with 05% topical fluorouracil on occurrence of actinic keratosis after cryosurgery: a randomized, vehicle-controlled clinical trial. *Arch Dermatol*. 2004;140:813-6. URL: <https://www.ncbi.nlm.nih.gov/pubmed/15262691>
189. Jorizzo J, Weiss J, Vamvakias G. One-week treatment with 05% fluorouracil cream prior to cryosurgery in patients with actinic keratoses: a double-blind, vehicle-controlled, long-term study. *J Drugs Dermatol*. 2006;5:133-9. URL: <https://www.ncbi.nlm.nih.gov/pubmed/16485881>
190. Levy S, Furst K, Chern W. A pharmacokinetic evaluation of 05% and 5% fluorouracil topical cream in patients with actinic keratosis. *Clin Ther*. 2001;23:908-20. URL: <https://www.ncbi.nlm.nih.gov/pubmed/11440290>
191. Samorano LP, Torezan LA, Sanches JA. Evaluation of the tolerability and safety of a 0015% ingenol mebutate gel compared to 5% 5-fluorouracil cream for the treatment of facial actinic keratosis: a prospective randomized trial. *J Eur Acad Dermatol Venereol*. 2015;29:1822-7. URL: <https://www.ncbi.nlm.nih.gov/pubmed/25727104>
192. Stockfleth E, von Kiedrowski R, Dominicus R, Ryan J, Ellery A, Falques M, et al. Efficacy and Safety of 5-Fluorouracil 05%/Salicylic Acid 10% in the Field-Directed Treatment of Actinic Keratosis: A Phase III, Randomized, Double-Blind, Vehicle-Controlled Trial. *Dermatol Ther (Heidelb)*. 2017;7:81-96. URL: <https://www.ncbi.nlm.nih.gov/pubmed/27995485>

193. Stockfleth E, Sibbring GC, Alarcon I. New Topical Treatment Options for Actinic Keratosis: A Systematic Review. *Acta Derm Venereol.* 2016;96:17-22. URL: <https://www.ncbi.nlm.nih.gov/pubmed/26068001>
194. Lebwohl M, Swanson N, Anderson LL, Melgaard A, Xu Z, Berman B. Ingenol mebutate gel for actinic keratosis. *N Engl J Med.* 2012;366:1010-9. URL: <https://www.ncbi.nlm.nih.gov/pubmed/22417254>
195. Garbe C, Basset-Seguín N, Poulin Y, Larsson T, Osterdal ML, Venkata R, et al. Efficacy and safety of follow-up field treatment of actinic keratosis with ingenol mebutate 0015% gel: a randomized, controlled 12-month study. *Br J Dermatol.* 2016;174:505-13. URL: <https://www.ncbi.nlm.nih.gov/pubmed/26471889>
196. Lebwohl M, Shumack S, Stein Gold L, Melgaard A, Larsson T, Tyring SK. Long-term follow-up study of ingenol mebutate gel for the treatment of actinic keratoses. *JAMA Dermatol.* 2013;149:666-70. URL: <https://www.ncbi.nlm.nih.gov/pubmed/23553119>
197. Anderson L, Schmieder GJ, Werschler WP, Tschen EH, Ling MR, Stough DB, et al. Randomized, double-blind, double-dummy, vehicle-controlled study of ingenol mebutate gel 0025% and 005% for actinic keratosis. *J Am Acad Dermatol.* 2009;60:934-43. URL: <https://www.ncbi.nlm.nih.gov/pubmed/19467365>
198. Pellacani G, Peris K, Guillen C, Clonier F, Larsson T, Venkata R, et al. A randomized trial comparing simultaneous vs sequential field treatment of actinic keratosis with ingenol mebutate on two separate areas of the head and body. *J Eur Acad Dermatol Venereol.* 2015;29:2192-8. URL: <https://www.ncbi.nlm.nih.gov/pubmed/26300464>
199. Zane C, Fabiano A, Arisi M, Calzavara-Pinton P. A Randomized Split-Face Clinical Trial of Photodynamic Therapy with Methyl Aminolevulinate versus Ingenol Mebutate Gel for the Treatment of Multiple Actinic Keratoses of the Face and Scalp. *Dermatology.* 2016;232:472-7. URL: <https://www.ncbi.nlm.nih.gov/pubmed/27578305>
200. Moggio E, Arisi M, Zane C, Calzavara-Pinton I, Calzavara-Pinton P. A randomized split-face clinical trial analyzing daylight photodynamic therapy with methyl aminolaevulinate vs ingenol mebutate gel for the treatment of multiple actinic keratoses of the face and the scalp. *Photodiagnosis Photodyn Ther.* 2016;16:161-165. URL: <https://www.ncbi.nlm.nih.gov/pubmed/27530375>
201. Sinnya S, Tan JM, Prow TW, Primiero C, McEniery E, Selmer J, et al. A randomized, phase IIa exploratory trial to assess the safety and preliminary efficacy of LEO 43204 in patients with actinic keratosis. *Br J Dermatol.* 2016;174:305-11. URL: <https://www.ncbi.nlm.nih.gov/pubmed/26499175>
202. Alomar A, Bichel J, McRae S. Vehicle-controlled, randomized, double-blind study to assess safety and efficacy of imiquimod 5% cream applied once daily 3 days per week in one or two courses of treatment of actinic keratoses on the head. *Br J Dermatol.* 2007;157:133-41. URL: <https://www.ncbi.nlm.nih.gov/pubmed/17501955>
203. Gebauer K, Shumack S, Cowen PS. Effect of dosing frequency on the safety and efficacy of imiquimod 5% cream for treatment of actinic keratosis on the forearms and hands: a phase II, randomized placebo-controlled trial. *Br J Dermatol.* 2009;161:897-903. URL: <https://www.ncbi.nlm.nih.gov/pubmed/19545297>
204. Jorizzo J, Dinehart S, Matheson R, Moore JK, Ling M, Fox TL, et al. Vehicle-controlled, double-blind, randomized study of imiquimod 5% cream applied 3 days per week in one or two courses of treatment for actinic keratoses on the head. *J Am Acad Dermatol.* 2007;57:265-8. URL: <https://www.ncbi.nlm.nih.gov/pubmed/17512087>

205. Korman N, Moy R, Ling M, Matheson R, Smith S, McKane S, et al. Dosing with 5% imiquimod cream 3 times per week for the treatment of actinic keratosis: results of two phase 3, randomized, double-blind, parallel-group, vehicle-controlled trials. *Arch Dermatol*. 2005;141:467-73. URL: <https://www.ncbi.nlm.nih.gov/pubmed/15837864>
206. Lebwohl M, Dinehart S, Whiting D, Lee PK, Tawfik N, Jorizzo J, et al. Imiquimod 5% cream for the treatment of actinic keratosis: results from two phase III, randomized, double-blind, parallel group, vehicle-controlled trials. *J Am Acad Dermatol*. 2004;50:714-21. URL: <https://www.ncbi.nlm.nih.gov/pubmed/15097955>
207. Stockfleth E, Meyer T, Benninghoff B, Salasche S, Papadopoulos L, Ulrich C, et al. A randomized, double-blind, vehicle-controlled study to assess 5% imiquimod cream for the treatment of multiple actinic keratoses. *Arch Dermatol*. 2002;138:1498-502. URL: <https://www.ncbi.nlm.nih.gov/pubmed/12437457>
208. Szeimies RM, Gerritsen MJ, Gupta G, Ortonne JP, Serresi S, Bichel J, et al. Imiquimod 5% cream for the treatment of actinic keratosis: results from a phase III, randomized, double-blind, vehicle-controlled, clinical trial with histology. *J Am Acad Dermatol*. 2004;51:547-55. URL: <https://www.ncbi.nlm.nih.gov/pubmed/15389189>
209. Hadley G, Derry S, Moore RA. Imiquimod for actinic keratosis: systematic review and meta-analysis. *J Invest Dermatol*. 2006;126:1251-5. URL: <https://www.ncbi.nlm.nih.gov/pubmed/16557235>
210. Chen K, Yap LM, Marks R, Shumack S. Short-course therapy with imiquimod 5% cream for solar keratoses: a randomized controlled trial. *Australas J Dermatol*. 2003;44:250-5. URL: <https://www.ncbi.nlm.nih.gov/pubmed/14616490>
211. Ooi T, Barnetson RS, Zhuang L, McKane S, Lee JH, Slade HB, et al. Imiquimod-induced regression of actinic keratosis is associated with infiltration by T lymphocytes and dendritic cells: a randomized controlled trial. *Br J Dermatol*. 2006;154:72-8. URL: <https://www.ncbi.nlm.nih.gov/pubmed/16403097>
212. Ortonne JP, Gupta G, Ortonne N, Duteil L, Queille C, Malfefet P. Effectiveness of cross polarized light and fluorescence diagnosis for detection of sub-clinical and clinical actinic keratosis during imiquimod treatment. *Exp Dermatol*. 2010;19:641-7. URL: <https://www.ncbi.nlm.nih.gov/pubmed/20201959>
213. Ulrich C, Bichel J, Euvrard S, Guidi B, Proby CM, van de Kerkhof PC, et al. Topical immunomodulation under systemic immunosuppression: results of a multicentre, randomized, placebo-controlled safety and efficacy study of imiquimod 5% cream for the treatment of actinic keratoses in kidney, heart, and liver transplant patients. *Br J Dermatol*. 2007;157 Suppl 2:25-31. URL: <https://www.ncbi.nlm.nih.gov/pubmed/18067628>
214. Hanke CW, Beer KR, Stockfleth E, Wu J, Rosen T, Levy S. Imiquimod 25% and 375% for the treatment of actinic keratoses: results of two placebo-controlled studies of daily application to the face and balding scalp for two 3-week cycles. *J Am Acad Dermatol*. 2010;62:573-81. URL: <https://www.ncbi.nlm.nih.gov/pubmed/20133012>
215. Swanson N, Abramovits W, Berman B, Kulp J, Rigel DS, Levy S. Imiquimod 25% and 375% for the treatment of actinic keratoses: results of two placebo-controlled studies of daily application to the face and balding scalp for two 2-week cycles. *J Am Acad Dermatol*. 2010;62:582-90. URL: <https://www.ncbi.nlm.nih.gov/pubmed/20133013>
216. Peris K, Stockfleth E, Gupta G, Aractingi S, Dakovic R, Dirschka T, et al. Efficacy of imiquimod 375% from Lmax according to the number of actinic keratosis lesions. *J Eur Acad Dermatol Venereol*. 2015;29:2470-3. URL: <https://www.ncbi.nlm.nih.gov/pubmed/26954313>

217. Blauvelt A, Kempers S, Lain E, Schlesinger T, Tyring S, Forman S, et al. Phase 3 Trials of Tirbanibulin Ointment for Actinic Keratosis. *N Engl J Med*. 2021;384(6):512-520. URL: <https://pubmed.ncbi.nlm.nih.gov/33567191/>
218. Smolinski M, Bu Y, Clements J, Gelman I, Hegab T, Cutler D, et al. Discovery of Novel Dual Mechanism of Action Src Signaling and Tubulin Polymerization Inhibitors (KX2-391 and KX2-361). *J Med Chem*. 2018;61(11):4704-4719. URL: <https://pubmed.ncbi.nlm.nih.gov/29617135/>
219. Hauschild A, Stockfleth E, Popp G, Borrosch F, Brüning H, Dominicus R, et al. Optimization of photodynamic therapy with a novel self-adhesive 5-aminolaevulinic acid patch: results of two randomized controlled phase III studies. *Br J Dermatol*. 2009;160(5):1066-74. URL: <https://pubmed.ncbi.nlm.nih.gov/19222455/>
220. Apalla Z, Sotiriou E, Panagiotidou D, Lefaki I, Goussi C, Ioannides D. The impact of different fluence rates on pain and clinical outcome in patients with actinic keratoses treated with photodynamic therapy. *Photodermatol Photoimmunol Photomed*. 2011;27:181-5. URL: <https://www.ncbi.nlm.nih.gov/pubmed/21729165>
221. Giehl KA, Kriz M, Grahovac M, Ruzicka T, Berking C. A controlled trial of photodynamic therapy of actinic keratosis comparing different red light sources. *Eur J Dermatol*. 2014;24:335-41. URL: <https://www.ncbi.nlm.nih.gov/pubmed/24876164>
222. Jeffes EW, McCullough JL, Weinstein GD, Kaplan R, Glazer SD, Taylor JR. Photodynamic therapy of actinic keratoses with topical aminolevulinic acid hydrochloride and fluorescent blue light. *J Am Acad Dermatol*. 2001;45:96-104. URL: <https://www.ncbi.nlm.nih.gov/pubmed/11423841>
223. Pariser DM, Houlihan A, Ferdon MB, Berg JE. Randomized Vehicle-Controlled Study of Short Drug Incubation Aminolevulinic Acid Photodynamic Therapy for Actinic Keratoses of the Face or Scalp. *Dermatol Surg*. 2016;42:296-304. URL: <https://www.ncbi.nlm.nih.gov/pubmed/26863596>
224. Piacquadio DJ, Chen DM, Farber HF, Fowler JF, Glazer SD, Goodman JJ, et al. Photodynamic therapy with aminolevulinic acid topical solution and visible blue light in the treatment of multiple actinic keratoses of the face and scalp: investigator-blinded, phase 3, multicenter trials. *Arch Dermatol*. 2004;140:41-6. URL: <https://www.ncbi.nlm.nih.gov/pubmed/14732659>
225. Schmieder GJ, Huang EY, Jarratt M. A multicenter, randomized, vehicle-controlled phase 2 study of blue light photodynamic therapy with aminolevulinic acid HCl 20% topical solution for the treatment of actinic keratoses on the upper extremities: the effect of occlusion during the drug incubation period. *J Drugs Dermatol*. 2012;11:1483-9. URL: <https://www.ncbi.nlm.nih.gov/pubmed/23377520>
226. Taub AF, Garretson CB. A randomized, blinded, bilateral intraindividual, vehicle-controlled trial of the use of photodynamic therapy with 5-aminolevulinic acid and blue light for the treatment of actinic keratoses of the upper extremities. *J Drugs Dermatol*. 2011;10:1049-56. URL: <https://www.ncbi.nlm.nih.gov/pubmed/22052276>
227. Moloney FJ, Collins P. Randomized, double-blind, prospective study to compare topical 5-aminolaevulinic acid methylester with topical 5-aminolaevulinic acid photodynamic therapy for extensive scalp actinic keratosis. *Br J Dermatol*. 2007;157:87-91. URL: <https://www.ncbi.nlm.nih.gov/pubmed/17501954>
228. Szeimies RM, Radny P, Sebastian M, Borrosch F, Dirschka T, Krahn-Sentleben G, et al. Photodynamic therapy with BF-200 ALA for the treatment of actinic keratosis: results of a

- prospective, randomized, double-blind, placebo-controlled phase III study. *Br J Dermatol.* 2010;163:386-94. URL: <https://www.ncbi.nlm.nih.gov/pubmed/20518784>
229. Dirschka T, Radny P, Dominicus R, Mensing H, Bruning H, Jenne L, et al. Long-term (6 and 12 months) follow-up of two prospective, randomized, controlled phase III trials of photodynamic therapy with BF-200 ALA and methyl aminolaevulinate for the treatment of actinic keratosis. *Br J Dermatol.* 2013;168:825-36. URL: <https://www.ncbi.nlm.nih.gov/pubmed/23252768>
230. Dirschka T, Radny P, Dominicus R, Mensing H, Bruning H, Jenne L, et al. Photodynamic therapy with BF-200 ALA for the treatment of actinic keratosis: results of a multicentre, randomized, observer-blind phase III study in comparison with a registered methyl-5-aminolaevulinate cream and placebo. *Br J Dermatol.* 2012;166:137-46. URL: <https://www.ncbi.nlm.nih.gov/pubmed/21910711>
231. Reinhold U, Dirschka T, Ostendorf R, Aschoff R, Berking C, Philipp-Dormston WG, et al. A randomized, double-blind, phase III, multicentre study to evaluate the safety and efficacy of BF-200 ALA (Ameluz((R))) vs placebo in the field-directed treatment of mild-to-moderate actinic keratosis with photodynamic therapy (PDT) when using the BF-RhodoLED((R)) lamp. *Br J Dermatol.* 2016;175:696-705. URL: <https://pubmed.ncbi.nlm.nih.gov/26921093/>
232. Szeimies RM, Matheson RT, Davis SA, Bhatia AC, Frambach Y, Klovekorn W, et al. Topical methyl aminolevulinate photodynamic therapy using red light-emitting diode light for multiple actinic keratoses: a randomized study. *Dermatol Surg.* 2009;35:586-92. URL: <https://www.ncbi.nlm.nih.gov/pubmed/19309347>
233. Pariser DM, Lowe NJ, Stewart DM, Jarratt MT, Lucky AW, Pariser RJ, et al. Photodynamic therapy with topical methyl aminolevulinate for actinic keratosis: results of a prospective randomized multicenter trial. *J Am Acad Dermatol.* 2003;48:227-32. URL: <https://www.ncbi.nlm.nih.gov/pubmed/12582393>
234. Pariser D, Loss R, Jarratt M, Abramovits W, Spencer J, Geronemus R, et al. Topical methyl-aminolevulinate photodynamic therapy using red light-emitting diode light for treatment of multiple actinic keratoses: A randomized, double-blind, placebo-controlled study. *J Am Acad Dermatol.* 2008;59:569-76. URL: <https://www.ncbi.nlm.nih.gov/pubmed/18707799>
235. Tarstedt M, Rosdahl I, Berne B, Svanberg K, Wennberg AM. A randomized multicenter study to compare two treatment regimens of topical methyl aminolevulinate (Metvix)-PDT in actinic keratosis of the face and scalp. *Acta Derm Venereol.* 2005;85:424-8. URL: <https://www.ncbi.nlm.nih.gov/pubmed/16159735>
236. von Felbert V, Hoffmann G, Hoff-Lesch S, Abuzahra F, Renn CN, Braathen LR, et al. Photodynamic therapy of multiple actinic keratoses: reduced pain through use of visible light plus water-filtered infrared A compared with light from light-emitting diodes. *Br J Dermatol.* 2010;163:607-15. URL: <https://www.ncbi.nlm.nih.gov/pubmed/20426780>
237. Seubring I, Groenewoud JMM, Gerritsen MP. Comparison of "Lesion-by-Lesion" and Field Photodynamic Therapy in the Prevention of Actinic Keratoses: A Randomized, Split-Face, Single-Blind Pilot Study. *Dermatology.* 2016;232:708-714. URL: <https://pubmed.ncbi.nlm.nih.gov/28095373/>
238. Kohl E, Popp C, Zeman F, Unger P, Koller M, Landthaler M, et al. Photodynamic therapy using intense pulsed light for treating actinic keratoses and photoaged skin of the dorsal hands: a randomized placebo-controlled study. *Br J Dermatol.* 2017;176:352-362. URL: <https://www.ncbi.nlm.nih.gov/pubmed/27518833>

239. Assikar S, Labrunie A, Kerob D, Couraud A, Bédane C. Daylight photodynamic therapy with methyl aminolevulinate cream is as effective as conventional photodynamic therapy with blue light in the treatment of actinic keratosis: a controlled randomized intra-individual study. *J Eur Acad Dermatol Venereol*. 2020;34(8):1730-1735. URL: <https://pubmed.ncbi.nlm.nih.gov/31955461/>
240. Dirschka T, Ekanayake-Bohlig S, Dominicus R, Aschoff R, Herrera-Ceballos E, Botella-Estrada R, et al. A randomized, intraindividual, non-inferiority, Phase III study comparing daylight photodynamic therapy with BF-200 ALA gel and MAL cream for the treatment of actinic keratosis. *J Eur Acad Dermatol Venereol*. 2019;33(2):288-297. URL: <https://pubmed.ncbi.nlm.nih.gov/30022544/>
241. Räsänen J, Neittaanmäki N, Ylitalo L, Hagman J, Rissanen P, Ylianttila L, et al. 5-aminolaevulinic acid nanoemulsion is more effective than methyl-5-aminolaevulinate in daylight photodynamic therapy for actinic keratosis: a nonsponsored randomized double-blind multicentre trial. *Br J Dermatol*. 2019;181(2):265-274. URL: <https://pubmed.ncbi.nlm.nih.gov/30329163/>
242. Wiegell SR, Haedersdal M, Philipsen PA, Eriksen P, Enk CD, Wulf HC. Continuous activation of PpIX by daylight is as effective as and less painful than conventional photodynamic therapy for actinic keratoses; a randomized, controlled, single-blinded study. *Br J Dermatol*. 2008;158:740-6. URL: <https://www.ncbi.nlm.nih.gov/pubmed/18294318>
243. Wiegell SR, Haedersdal M, Eriksen P, Wulf HC. Photodynamic therapy of actinic keratoses with 8% and 16% methyl aminolaevulinate and home-based daylight exposure: a double-blinded randomized clinical trial. *Br J Dermatol*. 2009;160:1308-14. URL: <https://www.ncbi.nlm.nih.gov/pubmed/19416257>
244. Wiegell SR, Fabricius S, Stender IM, Berne B, Kroon S, Andersen BL, et al. A randomized, multicentre study of directed daylight exposure times of 1(1/2) vs 2(1/2) h in daylight-mediated photodynamic therapy with methyl aminolaevulinate in patients with multiple thin actinic keratoses of the face and scalp. *Br J Dermatol*. 2011;164:1083-90. URL: <https://www.ncbi.nlm.nih.gov/pubmed/21219287>
245. Neittaanmaki-Perttu N, Gronroos M, Karppinen T, Snellman E, Rissanen P. Photodynamic Therapy for Actinic Keratoses: A Randomized Prospective Non-sponsored Cost-effectiveness Study of Daylight-mediated Treatment Compared with Light-emitting Diode Treatment. *Acta Derm Venereol*. 2016;96:241-4. URL: <https://www.ncbi.nlm.nih.gov/pubmed/26258496>
246. Rubel DM, Spelman L, Murrell DF, See JA, Hewitt D, Foley P, et al. Daylight photodynamic therapy with methyl aminolevulinate cream as a convenient, similarly effective, nearly painless alternative to conventional photodynamic therapy in actinic keratosis treatment: a randomized controlled trial. *Br J Dermatol*. 2014;171:1164-71. URL: <https://www.ncbi.nlm.nih.gov/pubmed/26258496>
247. Lacour JP, Ulrich C, Gilaberte Y, Von Felbert V, Basset-Seguín N, Dreno B, et al. Daylight photodynamic therapy with methyl aminolevulinate cream is effective and nearly painless in treating actinic keratoses: a randomised, investigator-blinded, controlled, phase III study throughout Europe. *J Eur Acad Dermatol Venereol*. 2015;29:2342-8. URL: <https://www.ncbi.nlm.nih.gov/pubmed/26435363>
248. Dragieva G, Prinz BM, Hafner J, Dummer R, Burg G, Binswanger U, et al. A randomized controlled clinical trial of topical photodynamic therapy with methyl aminolaevulinate in the treatment of actinic keratoses in transplant recipients. *Br J Dermatol*. 2004;151:196-200. URL: <https://www.ncbi.nlm.nih.gov/pubmed/15270891>

249. Morton C, Horn M, Leman J, Tack B, Bedane C, Tjioe M, et al. Comparison of topical methyl aminolevulinate photodynamic therapy with cryotherapy or Fluorouracil for treatment of squamous cell carcinoma in situ: Results of a multicenter randomized trial. *Arch Dermatol*. 2006;142(6):729-35. URL: <https://pubmed.ncbi.nlm.nih.gov/16785375/>
250. Miola A, Ferreira E, Lima T, Schmitt J, Abbade L, Miot H. Effectiveness and safety of 0.5% colchicine cream vs photodynamic therapy with methyl aminolaevulinate in the treatment of actinic keratosis and skin field cancerization of the forearms: a randomized controlled trial. *Br J Dermatol*. 2018;179(5):1081-1087. URL: <https://pubmed.ncbi.nlm.nih.gov/29862491/>
251. Ulrich M, Reinhold U, Dominicus R, Aschoff R, Szeimies R, Dirschka T. Red light photodynamic therapy with BF-200 ALA showed superior efficacy in the treatment of actinic keratosis on the extremities, trunk, and neck in a vehicle-controlled phase III study. *J Am Acad Dermatol*. 2021; URL: <https://pubmed.ncbi.nlm.nih.gov/33744350/>
252. Brian Jiang S, Kempers S, Rich P, Marcus S, Houlihan A, Piacquadio D, et al. A Randomized, Vehicle-Controlled Phase 3 Study of Aminolevulinic Acid Photodynamic Therapy for the Treatment of Actinic Keratoses on the Upper Extremities. *Dermatol Surg*. 2019;45(7):890-897. URL: <https://pubmed.ncbi.nlm.nih.gov/30640777/>
253. Ulrich M, Reinhold U, Dominicus R, Aschoff R, Szeimies R, Dirschka T. Red light photodynamic therapy with BF-200 ALA showed superior efficacy in the treatment of actinic keratosis on the extremities, trunk, and neck in a vehicle-controlled phase III study. *J Am Acad Dermatol*. 2021;85(6):1510-1519. URL: <https://pubmed.ncbi.nlm.nih.gov/33744350/>
254. Hauschild A, Popp G, Stockfleth E, Meyer KG, Imberger D, Mohr P, et al. Effective photodynamic therapy of actinic keratoses on the head and face with a novel, self-adhesive 5-aminolaevulinic acid patch. *Exp Dermatol*. 2009;18:116-21. URL: <https://www.ncbi.nlm.nih.gov/pubmed/18643849>
255. Szeimies RM, Stockfleth E, Popp G, Borrosch F, Bruning H, Dominicus R, et al. Long-term follow-up of photodynamic therapy with a self-adhesive 5-aminolaevulinic acid patch: 12 months data. *Br J Dermatol*. 2010;162:410-4. URL: <https://www.ncbi.nlm.nih.gov/pubmed/19804593>
256. Neittaanmaki-Perttu N, Karppinen TT, Gronroos M, Tani TT, Snellman E. Daylight photodynamic therapy for actinic keratoses: a randomized double-blinded nonsponsored prospective study comparing 5-aminolaevulinic acid nanoemulsion (BF-200) with methyl-5-aminolaevulinate. *Br J Dermatol*. 2014;171:1172-80. URL: <https://www.ncbi.nlm.nih.gov/pubmed/25109244>
257. Dahle DO, Grotmol T, Leivestad T, Hartmann A, Midtvedt K, Reisaeter AV, et al. Association Between Pretransplant Cancer and Survival in Kidney Transplant Recipients. *Transplantation*. 2017;101:2599-2605. URL: <https://www.ncbi.nlm.nih.gov/pubmed/28207636>
258. Togsverd-Bo K, Halldin C, Sandberg C, Gonzalez H, Wennberg A, Sørensen S, et al. Photodynamic therapy is more effective than imiquimod for actinic keratosis in organ transplant recipients: a randomized intraindividual controlled trial. *Br J Dermatol*. 2018;178(4):903-909. URL: <https://pubmed.ncbi.nlm.nih.gov/28796885/>
259. Veronese F, Zavattaro E, Orioni G, Landucci G, Tarantino V, Airoidi C, et al. Efficacy of new class I medical device for actinic keratoses: a randomized controlled prospective study. *J Dermatolog Treat*. 2021;32(6):625-630. URL: <https://pubmed.ncbi.nlm.nih.gov/31689138/>

260. Heppt M, Steeb T, Niesert A, Zacher M, Leiter U, Garbe C, et al. Local interventions for actinic keratosis in organ transplant recipients: a systematic review. *Br J Dermatol*. 2019;180(1):43-50. URL: <https://pubmed.ncbi.nlm.nih.gov/30188570/>
261. Wennberg AM, Stenquist B, Stockfleth E, Keohane S, Lear JT, Jemec G, et al. Photodynamic therapy with methyl aminolevulinate for prevention of new skin lesions in transplant recipients: A randomized study. *Transplantation*. 2008;86:423-429. URL: <https://pubmed.ncbi.nlm.nih.gov/18698246/>
262. Santos-Juanes J, Esteve A, Mas-Vidal A, Coto-Segura P, Salgueiro E, Gomez E, et al. Acute renal failure caused by imiquimod 5% cream in a renal transplant patient: review of the literature on side effects of imiquimod. *Dermatology*. 2011;222:109-12. URL: <https://www.ncbi.nlm.nih.gov/pubmed/21304243>
263. Akar A, Bulent Tastan H, Erbil H, Arca E, Kurumlu Z, Gur AR. Efficacy and safety assessment of 05% and 1% colchicine cream in the treatment of actinic keratoses. *J Dermatolog Treat*. 2001;12:199-203. URL: <https://www.ncbi.nlm.nih.gov/pubmed/12241628>
264. Alberts DS, Dorr RT, Einspahr JG, Aickin M, Saboda K, Xu MJ, et al. Chemoprevention of human actinic keratoses by topical 2-(difluoromethyl)-dl-ornithine. *Cancer Epidemiol Biomarkers Prev*. 2000;9:1281-6. URL: <https://www.ncbi.nlm.nih.gov/pubmed/11142412>
265. Evans M, Kalman D, Alvarez P, Paquet M, Guthrie N. A randomized, double-blind, placebo-controlled clinical trial evaluating Dermiyol((R)) cream for the treatment of actinic keratoses. *Clin Cosmet Investig Dermatol*. 2014;7:215-24. URL: <https://www.ncbi.nlm.nih.gov/pmc/articles/PMC4132222/>
266. Moloney F, Vestergaard M, Radojkovic B, Damian D. Randomized, double-blinded, placebo controlled study to assess the effect of topical 1% nicotinamide on actinic keratoses. *Br J Dermatol*. 2010;162:1138-9. URL: <https://www.ncbi.nlm.nih.gov/pubmed/20199551>
267. Pflugfelder A, Andonov E, Weide B, Dirschka T, Schempp C, Stockfleth E, et al. Lack of activity of betulin-based Oleogel-S10 in the treatment of actinic keratoses: a randomized, multicentre, placebo-controlled double-blind phase II trial. *Br J Dermatol*. 2015;172:926-32. URL: <https://www.ncbi.nlm.nih.gov/pubmed/25124939/>
268. Tong DW, Barnetson RS. Beta-1,3-D-glucan gel in the treatment of solar keratoses. *Australas J Dermatol*. 1996;37:137-8. URL: <https://www.ncbi.nlm.nih.gov/pubmed/8771866>
269. Thompson SC, Jolley D, Marks R. Reduction of solar keratoses by regular sunscreen use. *N Engl J Med*. 1993;329:1147-51. URL: <https://www.ncbi.nlm.nih.gov/pubmed/8377777>
270. Stoddard M, Herrmann J, Moy L, Moy R. Improvement of Actinic Keratoses Using Topical DNA Repair Enzymes: A Randomized Placebo-Controlled Trial. *J Drugs Dermatol*. 2017;16(10):1030-1034. URL: <https://pubmed.ncbi.nlm.nih.gov/29036257/>
271. Yang C, Wong T, Lee C, Hong C, Chang C, Lai F, et al. Efficacy and safety of topical SR-T100 gel in treating actinic keratosis in Taiwan: A Phase III randomized double-blind vehicle-controlled parallel trial. *J Dermatol Sci*. 2018;90(3):295-302. URL: <https://pubmed.ncbi.nlm.nih.gov/29530340/>
272. Weiss J, Ulrich M, Bukhalo M, Osterdal ML, Bang B, Hanke CW. A seamless phase I/II dose-finding trial assessing ingenol disoxate (LEO 43204) for field treatment of actinic keratosis on the scalp. *Br J Dermatol*. 2017;176:1456-1464. URL: <https://www.ncbi.nlm.nih.gov/pubmed/28078678>
273. Bourcier M, Stein Gold L, Guenther L, Andreassen CM, Selmer J, Goldenberg G. A dose-finding trial with a novel ingenol derivative (ingenol disoxate: LEO 43204) for field treatment

- of actinic keratosis on full face or 250 cm² on the chest. *J Dermatolog Treat.* 2017;1-7. URL: <https://www.ncbi.nlm.nih.gov/pubmed/28264612>
274. Szeimies RM, Bichel J, Ortonne JP, Stockfleth E, Lee J, Meng TC. A phase II dose-ranging study of topical resiquimod to treat actinic keratosis. *Br J Dermatol.* 2008;159:205-10. URL: <https://www.ncbi.nlm.nih.gov/pubmed/18476957>
275. Huyke C, Laszczyk M, Scheffler A, Ernst R, Schempp CM. [Treatment of actinic keratoses with birch bark extract: a pilot study]. *J Dtsch Dermatol Ges.* 2006;4:132-6. URL: <https://www.ncbi.nlm.nih.gov/pubmed/16503940>
276. Huyke C, Reuter J, Rodig M, Kersten A, Laszczyk M, Scheffler A, et al. Treatment of actinic keratoses with a novel betulin-based oleogel A prospective, randomized, comparative pilot study. *J Dtsch Dermatol Ges.* 2009;7:128-33. URL: <https://www.ncbi.nlm.nih.gov/pubmed/18808378>
277. Jurk M, Heil F, Vollmer J, Schetter C, Krieg AM, Wagner H, et al. Human TLR7 or TLR8 independently confer responsiveness to the antiviral compound R-848. *Nat Immunol.* 2002;3:499. URL: <https://www.ncbi.nlm.nih.gov/pubmed/12032557>
278. Alirezai M, Dupuy P, Amblard P, Kalis B, Souteyrand P, Frappaz A, et al. Clinical evaluation of topical isotretinoin in the treatment of actinic keratoses. *J Am Acad Dermatol.* 1994;30:447-51. URL: <https://www.ncbi.nlm.nih.gov/pubmed/8113458>
279. Misiewicz J, Sendagorta E, Golebiowska A, Lorenc B, Czarnetzki BM, Jablonska S. Topical treatment of multiple actinic keratoses of the face with arotinoid methyl sulfone (Ro 14-9706) cream versus tretinoin cream: a double-blind, comparative study. *J Am Acad Dermatol.* 1991;24:448-51. URL: <https://www.ncbi.nlm.nih.gov/pubmed/2061443>
280. Kang S, Goldfarb MT, Weiss JS, Metz RD, Hamilton TA, Voorhees JJ, et al. Assessment of adapalene gel for the treatment of actinic keratoses and lentiginos: a randomized trial. *J Am Acad Dermatol.* 2003;49:83-90. URL: <https://www.ncbi.nlm.nih.gov/pubmed/12833014>
281. Moriarty M, Dunn J, Darragh A, Lambe R, Brick I. Etretinate in treatment of actinic keratosis A double-blind crossover study. *Lancet.* 1982;1:364-5. URL: <https://www.ncbi.nlm.nih.gov/pubmed/6120350>
282. Amann PM, Merk HF, Baron JM. [Retinoids in dermatopharmacology]. *Hautarzt.* 2014;65:98-105. URL: <https://www.ncbi.nlm.nih.gov/pubmed/24419474>
283. Chen K, Craig JC, Shumack S. Oral retinoids for the prevention of skin cancers in solid organ transplant recipients: a systematic review of randomized controlled trials. *Br J Dermatol.* 2005;152:518-23. URL: <https://www.ncbi.nlm.nih.gov/pubmed/15787821>
284. Watson AB. Preventative effect of etretinate therapy on multiple actinic keratoses. *Cancer Detect Prev.* 1986;9:161-5. URL: <https://www.ncbi.nlm.nih.gov/pubmed/3524840>
285. Bercovitch L. Topical chemotherapy of actinic keratoses of the upper extremity with tretinoin and 5-fluorouracil: a double-blind controlled study. *Br J Dermatol.* 1987;116:549-52. URL: <https://www.ncbi.nlm.nih.gov/pubmed/3555597>
286. Robinson J. Actinic cheilitis A prospective study comparing four treatment methods. *Arch Otolaryngol Head Neck Surg.* 1989;115(7):848-52. URL: <https://pubmed.ncbi.nlm.nih.gov/2736096/>
287. Lai M, Pampena R, Cornacchia L, Pellacani G, Peris K, Longo C. Treatments of actinic cheilitis: A systematic review of the literature. *J Am Acad Dermatol.* 2020;83(3):876-887. URL: <https://pubmed.ncbi.nlm.nih.gov/31400450/>

288. Carvalho M, de Moraes S, Lemos C, Santiago Júnior J, Vasconcelos B, Pellizzer E. Surgical versus non-surgical treatment of actinic cheilitis: A systematic review and meta-analysis. *Oral Dis*. 2019;25(4):972-981. URL: <https://pubmed.ncbi.nlm.nih.gov/29908101/>
289. Salgueiro A, de Jesus L, de Souza I, Rados P, Visioli F. Treatment of actinic cheilitis: a systematic review. *Clin Oral Investig*. 2019;23(5):2041-2053. URL: <https://pubmed.ncbi.nlm.nih.gov/31011833/>
290. Laws R, Wilde J, Grabski W. Comparison of electrodesiccation with CO2 laser for the treatment of actinic cheilitis. *Dermatol Surg*. 2000;26(4):349-53. URL: <https://pubmed.ncbi.nlm.nih.gov/10759824/>
291. Lubritz R, Smolewski S. Cryosurgery cure rate of premalignant leukoplakia of the lower lip. *J Dermatol Surg Oncol*. 1983;9(3):235-7. URL: <https://pubmed.ncbi.nlm.nih.gov/6826879/>
292. Shah A, Doherty S, Rosen T. Actinic cheilitis: a treatment review. *Int J Dermatol*. 2010;49(11):1225-34. URL: <https://pubmed.ncbi.nlm.nih.gov/20964646/>
293. Alamillos-Granados F, Naval-Gías L, Dean-Ferrer A, Alonso del Hoyo J. Carbon dioxide laser vermilionectomy for actinic cheilitis. *J Oral Maxillofac Surg*. 1993;51(2):118-21. URL: <https://pubmed.ncbi.nlm.nih.gov/8426249/>
294. Dufresne R, Garrett A, Bailin P, Ratz J. Carbon dioxide laser treatment of chronic actinic cheilitis. *J Am Acad Dermatol*. 1988;19(5 Pt 1):876-8. URL: <https://pubmed.ncbi.nlm.nih.gov/3142939/>
295. Castiñeiras I, Del Pozo J, Mazaira M, Rodríguez-Lojo R, Fonseca E. Actinic cheilitis: evolution to squamous cell carcinoma after carbon dioxide laser vaporization A study of 43 cases. *J Dermatolog Treat*. 2010;21(1):49-53. URL: <https://pubmed.ncbi.nlm.nih.gov/19418331/>
296. Orenstein A, Goldan O, Weissman O, Winkler E, Haik J. A new modality in the treatment of actinic cheilitis using the Er:YAG laser. *J Cosmet Laser Ther*. 2007;9(1):23-5. URL: <https://pubmed.ncbi.nlm.nih.gov/17506137/>
297. Gonzaga A, de Oliveira P, da Silveira É, Queiroz L, de Medeiros A. Diclofenac sodium gel therapy as an alternative to actinic cheilitis. *Clin Oral Investig*. 2018;22(3):1319-1325. URL: <https://pubmed.ncbi.nlm.nih.gov/28986686/>
298. Husein-ElAhmed H, Almazan-Fernandez F, Husein-ElAhmed S. Ingenol mebutate versus imiquimod versus diclofenac for actinic cheilitis: a 6-month follow-up clinical study. *Clin Exp Dermatol*. 2019;44(2):231-234. URL: <https://pubmed.ncbi.nlm.nih.gov/30242791/>
299. Lima GS, Silva G, Gomes A, de Araújo L, Salum F. Diclofenac in hyaluronic acid gel: an alternative treatment for actinic cheilitis. *J Appl Oral Sci*. 18(5):533-7. URL: <https://pubmed.ncbi.nlm.nih.gov/21085813/>
300. Smith K, Germain M, Yeager J, Skelton H. Topical 5% imiquimod for the therapy of actinic cheilitis. *J Am Acad Dermatol*. 2002;47(4):497-501. URL: <https://pubmed.ncbi.nlm.nih.gov/12271290/>
301. Paolino G, Cantoresi F, Mercuri S, Cantisani C. Clinical evaluation and efficacy of Imiquimod 375% cream for the treatment of actinic keratosis, pigmented basal cell carcinomas, and actinic cheilitis. *Dermatol Ther*. 2020;33(3):e13356. URL: <https://pubmed.ncbi.nlm.nih.gov/32239714/>

302. Sotiriou E, Apalla Z, Koussidou-Erremonti T, Ioannides D. Actinic cheilitis treated with one cycle of 5-aminolaevulinic acid-based photodynamic therapy: report of 10 cases. *Br J Dermatol*. 2008;159(1):261-2. URL: <https://pubmed.ncbi.nlm.nih.gov/18489592/>
303. Sotiriou E, Apalla Z, Chovarda E, Panagiotidou D, Ioannides D. Photodynamic therapy with 5-aminolevulinic acid in actinic cheilitis: an 18-month clinical and histological follow-up. *J Eur Acad Dermatol Venereol*. 2010;24(8):916-20. URL: <https://pubmed.ncbi.nlm.nih.gov/20028448/>
304. Berking C, Herzinger T, Flaig M, Brenner M, Borelli C, Degitz K. The efficacy of photodynamic therapy in actinic cheilitis of the lower lip: a prospective study of 15 patients. *Dermatol Surg*. 2007;33(7):825-30. URL: <https://pubmed.ncbi.nlm.nih.gov/17598848/>
305. Chaves Y, Torezan L, Lourenço S, Neto C. Evaluation of the efficacy of photodynamic therapy for the treatment of actinic cheilitis. *Photodermatol Photoimmunol Photomed*. 2017;33(1):14-21. URL: <https://pubmed.ncbi.nlm.nih.gov/27864997/>
306. Ribeiro C, Souza F, Jordão J, Haendchen L, Mesquita L, Schmitt J, et al. Photodynamic therapy in actinic cheilitis: clinical and anatomopathological evaluation of 19 patients. *An Bras Dermatol*. 87(3):418-23. URL: <https://pubmed.ncbi.nlm.nih.gov/22714758/>
307. Radakovic S, Tanew A. 5-aminolaevulinic acid patch-photodynamic therapy in the treatment of actinic cheilitis. *Photodermatol Photoimmunol Photomed*. 2017;33(6):306-310. URL: <https://pubmed.ncbi.nlm.nih.gov/28703320/>
308. Radakovic S, Dangl M, Tanew A. 5-Aminolevulinic acid patch (Alacare) photodynamic therapy for actinic cheilitis: data from a prospective 12-month follow-up study on 21 patients. *J Eur Acad Dermatol Venereol*. 2020;34(9):2011-2015. URL: <https://pubmed.ncbi.nlm.nih.gov/31999856/>
309. Yazdani Abyaneh M, Falto-Aizpurua L, Griffith R, Nouri K. Photodynamic therapy for actinic cheilitis: a systematic review. *Dermatol Surg*. 2015;41(2):189-98. URL: <https://pubmed.ncbi.nlm.nih.gov/25627629/>
310. Levi A, Hodak E, Enk C, Snast I, Slodownik D, Lapidoth M. Daylight photodynamic therapy for the treatment of actinic cheilitis. *Photodermatol Photoimmunol Photomed*. 2019;35(1):11-16. URL: <https://pubmed.ncbi.nlm.nih.gov/30066408/>
311. Andreadis D, Pavlou A, Vakirlis E, Anagnostou E, Vrani F, Pouloupoulos A, et al. Daylight photodynamic therapy for the management of actinic cheilitis. *Arch Dermatol Res*. 2020;312(10):731-737. URL: <https://pubmed.ncbi.nlm.nih.gov/32266532/>
312. Choi S, Kim K, Song K. Efficacy of ablative fractional laser-assisted photodynamic therapy for the treatment of actinic cheilitis: 12-month follow-up results of a prospective, randomized, comparative trial. *Br J Dermatol*. 2015;173(1):184-91. URL: <https://pubmed.ncbi.nlm.nih.gov/25400009/>
313. Sotiriou E, Lallas A, Goussi C, Apalla Z, Trigoni A, Chovarda E, et al. Sequential use of photodynamic therapy and imiquimod 5% cream for the treatment of actinic cheilitis: a 12-month follow-up study. *Br J Dermatol*. 2011;165(4):888-92. URL: <https://pubmed.ncbi.nlm.nih.gov/21916880/>
314. Ali H, Shipman A, Orpin S. John Templeton Bowen, MD, 1857-1940: the centenary of his most famous publication. *Clin Exp Dermatol*. 2012;37(7):825-8. URL: <https://pubmed.ncbi.nlm.nih.gov/22998547/>
315. Peterka E, Lynch F, Goltz R. An association between Bowen's disease and internal cancer. *Arch Dermatol*. 1961;84(4):623. URL: <https://pubmed.ncbi.nlm.nih.gov/14485715/>

316. Kao G. Carcinoma arising in Bowen's disease. *Arch Dermatol*. 1986;122(10):1124-6. URL: <https://pubmed.ncbi.nlm.nih.gov/3767398/>
317. Leibovitch I, Huilgol S, Selva D, Richards S, Paver R. Cutaneous squamous carcinoma in situ (Bowen's disease): treatment with Mohs micrographic surgery. *J Am Acad Dermatol*. 2005;52(6):997-1002. URL: <https://pubmed.ncbi.nlm.nih.gov/15928618/>
318. Morton C, Whitehurst C, Moseley H, McColl J, Moore J, Mackie R. Comparison of photodynamic therapy with cryotherapy in the treatment of Bowen's disease. *Br J Dermatol*. 1996;135(5):766-71. URL: <https://pubmed.ncbi.nlm.nih.gov/8977678/>
319. Bath-Hextall F, Matin R, Wilkinson D, Leonardi-Bee J. Interventions for cutaneous Bowen's disease. *Cochrane Database Syst Rev*. 2013;(6):CD007281. URL: <https://pubmed.ncbi.nlm.nih.gov/23794286/>
320. Cai H, Wang Y, Zheng J, Sun P, Yang Z, Li Y, et al. Photodynamic therapy in combination with CO2 laser for the treatment of Bowen's disease. *Lasers Med Sci*. 2015;30(5):1505-10. URL: <https://pubmed.ncbi.nlm.nih.gov/25899562/>
321. Perrett C, McGregor J, Warwick J, Karran P, Leigh I, Proby C, et al. Treatment of post-transplant premalignant skin disease: a randomized inpatient comparative study of 5-fluorouracil cream and topical photodynamic therapy. *Br J Dermatol*. 2007;156(2):320-8. URL: <https://pubmed.ncbi.nlm.nih.gov/17223873/>
322. Salim A, Leman J, McColl J, Chapman R, Morton C. Randomized comparison of photodynamic therapy with topical 5-fluorouracil in Bowen's disease. *Br J Dermatol*. 2003;148(3):539-43. URL: <https://pubmed.ncbi.nlm.nih.gov/12653747/>
323. Patel G, Goodwin R, Chawla M, Laidler P, Price P, Finlay A, et al. Imiquimod 5% cream monotherapy for cutaneous squamous cell carcinoma in situ (Bowen's disease): a randomized, double-blind, placebo-controlled trial. *J Am Acad Dermatol*. 2006;54(6):1025-32. URL: <https://pubmed.ncbi.nlm.nih.gov/16713457/>
324. Genouw E, Verheire B, Ongenae K, De Schepper S, Creytens D, Verhaeghe E, et al. Laser-assisted photodynamic therapy for superficial basal cell carcinoma and Bowen's disease: a randomized inpatient comparison between a continuous and a fractional ablative CO. *J Eur Acad Dermatol Venereol*. 2018;32(11):1897-1905. URL: <https://pubmed.ncbi.nlm.nih.gov/29633367/>
325. Kim H, Song K. Ablative fractional laser-assisted photodynamic therapy provides superior long-term efficacy compared with standard methyl aminolevulinate photodynamic therapy for lower extremity Bowen disease. *J Am Acad Dermatol*. 2018;79(5):860-868. URL: <https://pubmed.ncbi.nlm.nih.gov/29857012/>
326. Ko D, Kim K, Song K. A randomized trial comparing methyl aminolevulinate photodynamic therapy with and without Er:YAG ablative fractional laser treatment in Asian patients with lower extremity Bowen disease: results from a 12-month follow-up. *Br J Dermatol*. 2014;170(1):165-72. URL: <https://pubmed.ncbi.nlm.nih.gov/24102369/>
327. Morton C, Whitehurst C, Moore J, MacKie R. Comparison of red and green light in the treatment of Bowen's disease by photodynamic therapy. *Br J Dermatol*. 2000;143(4):767-72. URL: <https://pubmed.ncbi.nlm.nih.gov/11069454/>
328. Wu Y, Wang P, Zhang L, Wang B, Wang X. Enhancement of Photodynamic Therapy for Bowen's Disease Using Plum-Blossom Needling to Augment Drug Delivery. *Dermatol Surg*. 2018;44(12):1516-1524. URL: <https://pubmed.ncbi.nlm.nih.gov/29994952/>
329. Sun L, Chin R, Gastman B, Thorstad W, Yom S, Reddy C, et al. Association of Disease Recurrence With Survival Outcomes in Patients With Cutaneous Squamous Cell Carcinoma of

- the Head and Neck Treated With Multimodality Therapy. *JAMA Dermatol.* 2019;155(4):442-447. URL: <https://pubmed.ncbi.nlm.nih.gov/30810715/>
330. Breuninger H, Schaumburg-Lever G, Holzschuh J, Horny HP. Desmoplastic squamous cell carcinoma of skin and vermilion surface: a highly malignant subtype of skin cancer. *Cancer.* 1997;79:915-9. URL: <https://www.ncbi.nlm.nih.gov/pubmed/9041153>
331. Clayman GL, Lee JJ, Holsinger FC, Zhou X, Duvic M, El-Naggar AK, et al. Mortality risk from squamous cell skin cancer. *J Clin Oncol.* 2005;23:759-65. URL: <https://www.ncbi.nlm.nih.gov/pubmed/15681519>
332. Tschetter A, Campoli M, Zitelli J, Brodland D. Long-term clinical outcomes of patients with invasive cutaneous squamous cell carcinoma treated with Mohs micrographic surgery: A 5-year, multicenter, prospective cohort study. *J Am Acad Dermatol.* 2020;82(1):139-148. URL: <https://pubmed.ncbi.nlm.nih.gov/31279037/>
333. Dzubow LM, Rigel DS, Robins P. Risk factors for local recurrence of primary cutaneous squamous cell carcinomas Treatment by microscopically controlled excision. *Arch Dermatol.* 1982;118:900-2. URL: <https://www.ncbi.nlm.nih.gov/pubmed/7138046>
334. Breuninger H, Black B, Rassner G. Microstaging of squamous cell carcinomas. *Am J Clin Pathol.* 1990;94:624-7. URL: <https://www.ncbi.nlm.nih.gov/pubmed/2239827>
335. Eroglu A, Berberoglu U, Berreroglu S. Risk factors related to locoregional recurrence in squamous cell carcinoma of the skin. *J Surg Oncol.* 1996;61:124-30. URL: <https://pubmed.ncbi.nlm.nih.gov/8606543/>
336. Mourouzis C, Boynton A, Grant J, Umar T, Wilson A, Macpheson D, et al. Cutaneous head and neck SCCs and risk of nodal metastasis - UK experience. *J Craniomaxillofac Surg.* 2009;37:443-7. URL: <https://www.ncbi.nlm.nih.gov/pubmed/19713116>
337. Brougham ND, Dennett ER, Cameron R, Tan ST. The incidence of metastasis from cutaneous squamous cell carcinoma and the impact of its risk factors. *J Surg Oncol.* 2012;106:811-5. URL: <https://www.ncbi.nlm.nih.gov/pubmed/22592943>
338. Peat B, Insull P, Ayers R. Risk stratification for metastasis from cutaneous squamous cell carcinoma of the head and neck. *ANZ J Surg.* 2012;82:230-3. URL: <https://www.ncbi.nlm.nih.gov/pubmed/22510179>
339. Karia PS, Jambusaria-Pahlajani A, Harrington DP, Murphy GF, Qureshi AA, Schmults CD. Evaluation of American Joint Committee on Cancer, International Union Against Cancer, and Brigham and Women's Hospital tumor staging for cutaneous squamous cell carcinoma. *J Clin Oncol.* 2014;32:327-34. URL: <https://www.ncbi.nlm.nih.gov/pubmed/24366933>
340. Vasconcelos L, Melo JC, Miot HA, Marques ME, Abbade LP. Invasive head and neck cutaneous squamous cell carcinoma: clinical and histopathological characteristics, frequency of local recurrence and metastasis. *An Bras Dermatol.* 2014;89:562-8. URL: <https://www.ncbi.nlm.nih.gov/pmc/articles/PMC4148268/pdf/abd-89-04-0562.pdf>
341. Wermker K, Belok F, Schipmann S, Klein M, Schulze HJ, Hallermann C. Prediction model for lymph node metastasis and recommendations for elective neck dissection in lip cancer. *J Craniomaxillofac Surg.* 2015;43:545-52. URL: <https://www.ncbi.nlm.nih.gov/pubmed/25753473>
342. Harris BN, Bayoumi A, Rao S, Moore MG, Farwell DG, Bewley AF. Factors Associated with Recurrence and Regional Adenopathy for Head and Neck Cutaneous Squamous Cell Carcinoma. *Otolaryngol Head Neck Surg.* 2017;156:863-869. URL: <http://journals.sagepub.com/doi/pdf/10.1177/0194599817697053>

343. Khan K, Mykula R, Kerstein R, Rabey N, Bragg T, Crick A, et al. A 5-year follow-up study of 633 cutaneous SCC excisions: Rates of local recurrence and lymph node metastasis. *J Plast Reconstr Aesthet Surg*. 2018;71(8):1153-1158. URL: <https://pubmed.ncbi.nlm.nih.gov/29803777/>
344. Stewart T, Saunders A. Risk factors for positive margins after wide local excision of cutaneous squamous cell carcinoma. *J Dermatolog Treat*. 2018;29(7):706-708. URL: <https://pubmed.ncbi.nlm.nih.gov/29448853/>
345. van Lee C, Roorda B, Wakkee M, Voorham Q, Mooyaart A, de Vijlder H, et al. Recurrence rates of cutaneous squamous cell carcinoma of the head and neck after Mohs micrographic surgery vs standard excision: a retrospective cohort study. *Br J Dermatol*. 2019;181(2):338-343. URL: <https://pubmed.ncbi.nlm.nih.gov/30199574/>
346. Korhonen N, Ylitalo L, Luukkaala T, Itkonen J, Häihälä H, Jernman J, et al. Recurrent and Metastatic Cutaneous Squamous Cell Carcinomas in a Cohort of 774 Patients in Finland. *Acta Derm Venereol*. 2020;100(8):adv00121. URL: <https://pubmed.ncbi.nlm.nih.gov/32255495/>
347. Rowe DE, Carroll RJ, Day CL. Prognostic factors for local recurrence, metastasis, and survival rates in squamous cell carcinoma of the skin, ear, and lip Implications for treatment modality selection. *J Am Acad Dermatol*. 1992;26:976-90. URL: <https://www.ncbi.nlm.nih.gov/pubmed/1607418>
348. Alam M, Ratner D. Cutaneous Squamous-Cell Carcinoma. *New England Journal of Medicine*. 2001;344:975-983. URL: <http://www.nejm.org/doi/full/10.1056/NEJM200103293441306>
349. Cheng J, Yan S. Prognostic variables in high-risk cutaneous squamous cell carcinoma: a review. *J Cutan Pathol*. 2016;43:994-1004. URL: <http://onlinelibrary.wiley.com/store/10.1111/cup.12766/asset/cup12766.pdf?v=1&t=j9zqbt pz&s=3c3898fa72baae8ce9a31a08d090a8acc21f740f>
350. Skulsky SL, O'Sullivan B, McArdle O, Leader M, Roche M, Conlon PJ, et al. Review of high-risk features of cutaneous squamous cell carcinoma and discrepancies between the American Joint Committee on Cancer and NCCN Clinical Practice Guidelines In Oncology. *Head Neck*. 2017;39:578-594. URL: <https://pubmed.ncbi.nlm.nih.gov/27882625/>
351. Johnson T, Smith N. Mohs Surgery versus Standard Local Excision for Basal Cell Carcinoma, Squamous Cell Carcinoma, and Melanoma Skin Cancer. *Facial Plast Surg*. 2020;36(2):133-140. URL: <https://pubmed.ncbi.nlm.nih.gov/32413920/>
352. Breuninger H, Eigentler T, Häfner H, Leiter U. Local surgical treatment of cutaneous squamous cell carcinoma: deficits and controversies in the literature. *J Dtsch Dermatol Ges*. 2019;17(10):999-1004. URL: <https://pubmed.ncbi.nlm.nih.gov/31545559/>
353. Breuninger H, Brantsch K, Eigentler T, Häfner H. Comparison and evaluation of the current staging of cutaneous carcinomas. *JDDG: Journal der Deutschen Dermatologischen Gesellschaft*. 2012;10:579-586. URL: <http://dx.doi.org/10.1111/j.1610-0387.2012.07896.x>
354. Stratigos A, Garbe C, Dessinioti C, Lebbe C, Bataille V, Bastholt L, et al. European interdisciplinary guideline on invasive squamous cell carcinoma of the skin: Part 1 epidemiology, diagnostics and prevention. *Eur J Cancer*. 2020;128:60-82. URL: <https://pubmed.ncbi.nlm.nih.gov/32113941/>
355. Bonerandi JJ, Beauvillain C, Caquant L, Chassagne JF, Chaussade V, Clavere P, et al. Guidelines for the diagnosis and treatment of cutaneous squamous cell carcinoma and precursor lesions. *J Eur Acad Dermatol Venereol*. 2011;25 Suppl 5:1-51. URL: <https://www.ncbi.nlm.nih.gov/pubmed/22070399>

356. SIGN. Scottish Intercollegiate Guidelines Network (SIGN) Management of primary cutaneous squamous cell carcinoma Edinburgh: SIGN; 2014 (SIGN publication no 140) [June 2014]. <http://www.sign.ac.uk> Last access November 2017. 2014; URL: <https://www.sign.ac.uk/sign-140-management-of-primary-cutaneous-squamous-cell-carcinoma.html>
357. Breuninger H, Eigentler T, Bootz F, Hauschild A, Kortmann R, Wolff K, et al. Brief S2k guidelines – Cutaneous squamous cell carcinoma. JDDG: Journal der Deutschen Dermatologischen Gesellschaft. 2013;11:37-45. URL: http://dx.doi.org/10.1111/ddg.12015_7
358. Schweinzer K ea. Different characteristics between common and desmoplastic cutaneous SCC in local infiltration and local recurrence. Not yet published
359. Schweinzer K, Kofler L, Bauer J, Metzler G, Breuninger H, Hafner HM. Cytokeratin AE1/AE3 immunostaining and 3D-histology: improvement of diagnosis in desmoplastic squamous cell carcinoma of the skin. Arch Dermatol Res. 2017;309:43-46. URL: <https://www.ncbi.nlm.nih.gov/pubmed/27864629>
360. Erkan S, Savundra JM, Wood B, Acharya AN, Rajan GP. Clinical perineural invasion of the trigeminal and facial nerves in cutaneous head and neck squamous cell carcinoma: Outcomes and prognostic implications of multimodality and salvage treatment. Head & Neck. 2017;39:1280-1286. URL: <https://onlinelibrary.wiley.com/doi/abs/10.1002/hed.24607>
361. Warren TA, Panizza B, Porceddu SV, Gandhi M, Patel P, Wood M, et al. Outcomes after surgery and postoperative radiotherapy for perineural spread of head and neck cutaneous squamous cell carcinoma. Head Neck. 2016;38:824-31. URL: <https://www.ncbi.nlm.nih.gov/pubmed/25546817>
362. Hutting KH, Bos PG, Kibbelaar RE, Veeger N, Marck KW, Moues CM. Effective excision of cutaneous squamous cell carcinoma of the face using analysis of intra-operative frozen sections from the whole specimen. J Surg Oncol. 2017; URL: <https://www.ncbi.nlm.nih.gov/pubmed/29073717>
363. Jambusaria-Pahlajani A, Miller CJ, Quon H, Smith N, Klein RQ, Schmults CD. Surgical monotherapy versus surgery plus adjuvant radiotherapy in high-risk cutaneous squamous cell carcinoma: a systematic review of outcomes. Dermatol Surg. 2009;35:574-85. URL: <https://pubmed.ncbi.nlm.nih.gov/19415791/>
364. Turner RJ, Leonard N, Malcolm AJ, Lawrence CM, Dahl MG. A retrospective study of outcome of Mohs' micrographic surgery for cutaneous squamous cell carcinoma using formalin fixed sections. Br J Dermatol. 2000;142:752-7. URL: <https://www.ncbi.nlm.nih.gov/pubmed/10792227>
365. Dunn M, Morgan MB, Beer TW. Perineural invasion: identification, significance, and a standardized definition. Dermatol Surg. 2009;35:214-21. URL: <http://onlinelibrary.wiley.com/store/10.1111/j.1524-4725.2008.34412.x/asset/j.1524-4725.2008.34412.x.pdf?v=1&t=j9zqnt7q&s=a63f0e26d61e2e8825c3d0e039505b37ae0177c4>
366. Haug K, Breuninger H, Metzler G, Eigentler T, Eichner M, Häfner H, et al. Prognostic Impact of Perineural Invasion in Cutaneous Squamous Cell Carcinoma: Results of a Prospective Study of 1,399 Tumors. J Invest Dermatol. 2020;140(10):1968-1975. URL: <https://pubmed.ncbi.nlm.nih.gov/32169476/>
367. Freeman RG, Knox JM, Heaton CL. The treatment of skin cancer A statistical study of 1,341 skin tumors comparing results obtained with irradiation, surgery, and curettage

- followed by electrodesiccation. *Cancer*. 1964;17:535-538. URL: <https://www.ncbi.nlm.nih.gov/pubmed/14136537>
368. Zitelli J. Secondary intention healing: an alternative to surgical repair. *Clin Dermatol*. 2(3):92-106. URL: <https://pubmed.ncbi.nlm.nih.gov/6400321/>
369. Bechara F. [Healing by secondary intention after skin cancer surgery on the head and neck]. *Hautarzt*. 2013;64(8):567-76. URL: <https://pubmed.ncbi.nlm.nih.gov/23868572/>
370. Swetter S, Boldrick J, Pierre P, Wong P, Egbert B. Effects of biopsy-induced wound healing on residual basal cell and squamous cell carcinomas: rate of tumor regression in excisional specimens. *J Cutan Pathol*. 2003;30(2):139-46. URL: <https://pubmed.ncbi.nlm.nih.gov/12641794/>
371. Grupp M, Illes M, Mentzel J, Simon J, Paasch U, Grunewald S. Schnittrandkontrolle von Basalzellkarzinomen mittels ex-vivo konfokaler Laserscanmikroskopie mit digitaler Farbbearbeitung - Anwendung in der Routinediagnostik. *J Dtsch Dermatol Ges*. 2021;19(5):685-693. URL: <https://pubmed.ncbi.nlm.nih.gov/33979047/>
372. Peters N, Schubert M, Bauer J, Ghoreschi F, Moehrle M. Rapid Lump Examination (RLE) - eine schnelle Methode in der mikroskopisch kontrollierten Chirurgie von Basalzellkarzinomen. *J Dtsch Dermatol Ges*. 2019;17(11):1131-1140. URL: <https://pubmed.ncbi.nlm.nih.gov/31765084/>
373. Eberle F, Kanyildiz M, Schnabl S, Schulz C, Häfner H, Adam P, et al. Three dimensional (3D) histology in daily routine: practical implementation and its evaluation. *J Dtsch Dermatol Ges*. 2014;12(11):1028-35. URL: <https://pubmed.ncbi.nlm.nih.gov/25354011/>
374. Boehringer A, Adam P, Schnabl S, Häfner H, Breuninger H. Analysis of incomplete excisions of basal-cell carcinomas after breadloaf microscopy compared with 3D-microscopy: a prospective randomized and blinded study. *J Cutan Pathol*. 2015;42(8):542-53. URL: <https://pubmed.ncbi.nlm.nih.gov/25975523/>
375. Kofler L, Breuninger H, Schreiber R, Eichner M, Häfner H, Schnabl S. Three-dimensional histology vs serial section histology in the treatment of primary basal cell carcinoma: a randomized, prospective, blinded study of 569 tumours. *J Eur Acad Dermatol Venereol*. 2021;35(6):1323-1330. URL: <https://pubmed.ncbi.nlm.nih.gov/33539573/>
376. Friedman NR. Prognostic factors for local recurrence, metastases, and survival rates in squamous cell carcinoma of the skin, ear, and lip. *J Am Acad Dermatol*. 1993;28:281-2. URL: <https://www.ncbi.nlm.nih.gov/pubmed/8432936>
377. Thomas DJ, King AR, Peat BG. Excision margins for nonmelanotic skin cancer. *Plast Reconstr Surg*. 2003;112:57-63. URL: <https://www.ncbi.nlm.nih.gov/pubmed/12832877>
378. Breuninger H, Schaumburg-Lever G. Control of excisional margins by conventional histopathological techniques in the treatment of skin tumours An alternative to Mohs' technique. *J Pathol*. 1988;154:167-71. URL: <http://onlinelibrary.wiley.com/doi/10.1002/path.1711540209/abstract>
379. Stratigos A, Garbe C, Dessinioti C, Lebbe C, Bataille V, Bastholt L, et al. European interdisciplinary guideline on invasive squamous cell carcinoma of the skin: Part 2 Treatment. *Eur J Cancer*. 2020;128:83-102. URL: <https://pubmed.ncbi.nlm.nih.gov/32113942/>
380. Muller FM, Dawe RS, Moseley H, Fleming CJ. Randomized comparison of Mohs micrographic surgery and surgical excision for small nodular basal cell carcinoma: tissue-sparing outcome. *Dermatol Surg*. 2009;35:1349-54. URL: <https://www.ncbi.nlm.nih.gov/pubmed/19500127>

381. Brodland DG, Zitelli JA. Surgical margins for excision of primary cutaneous squamous cell carcinoma. *J Am Acad Dermatol.* 1992;27:241-8. URL: <https://www.ncbi.nlm.nih.gov/pubmed/1430364>
382. Bogdanov-Berezovsky A, Cohen AD, Glesinger R, Cagnano E, Rosenberg L. Risk factors for incomplete excision of squamous cell carcinomas. *J Dermatolog Treat.* 2005;16:341-4. URL: <https://www.ncbi.nlm.nih.gov/pubmed/16428157>
383. Nemet AY, Deckel Y, Martin PA, Kourt G, Chilov M, Sharma V, et al. Management of periocular basal and squamous cell carcinoma: a series of 485 cases. *Am J Ophthalmol.* 2006;142:293-7. URL: <https://www.ncbi.nlm.nih.gov/pubmed/16876511>
384. Phillips T, Harris B, Moore M, Farwell D, Bewley A. Pathological margins and advanced cutaneous squamous cell carcinoma of the head and neck. *J Otolaryngol Head Neck Surg.* 2019;48(1):55. URL: <https://pubmed.ncbi.nlm.nih.gov/31653276/>
385. Bovill ES, Banwell PE. Re-excision of incompletely excised cutaneous squamous cell carcinoma: histological findings influence prognosis. *J Plast Reconstr Aesthet Surg.* 2012;65:1390-5. URL: <https://www.ncbi.nlm.nih.gov/pubmed/22652292>
386. Tan PY, Ek E, Su S, Giorlando F, Dieu T. Incomplete excision of squamous cell carcinoma of the skin: a prospective observational study. *Plast Reconstr Surg.* 2007;120:910-6. URL: <https://www.ncbi.nlm.nih.gov/pubmed/17805118>
387. Hansen C, Wilkinson D, Hansen M, Soyer H. Factors contributing to incomplete excision of nonmelanoma skin cancer by Australian general practitioners. *Archives of Dermatology.* 2009;145:1253-1260. URL: <https://www.ncbi.nlm.nih.gov/pubmed/19917954>
388. Mohs FE, Guyer MF. Pre-excisional Fixation of Tissues in the Treatment of Cancer in Rats. *Cancer Research.* 1941;1:49-51. URL: <http://cancerres.aacrjournals.org/content/canres/1/1/49.full.pdf>
389. Drepper H. Systematic Histological Control of the Tumor Bed as an Advance in the Operative Removal of Deep Facial Skin Cancers. *Hautarzt.* 1963;14:420-3. URL: <https://www.ncbi.nlm.nih.gov/pubmed/14051771>
390. Mohs FE. Chemosurgery: microscopically controlled surgery for skin cancer--past, present and future. *J Dermatol Surg Oncol.* 1978;4:41-54. URL: <https://www.ncbi.nlm.nih.gov/pubmed/618934>
391. Mohs FE. Chemosurgery for the microscopically controlled excision of cutaneous cancer. *Head Neck Surg.* 1978;1:150-66. URL: <https://www.ncbi.nlm.nih.gov/pubmed/755808>
392. Burg G, Hirsch RD, Konz B, Braun-Falco O. Histographic surgery: accuracy of visual assessment of the margins of basal-cell epithelioma. *J Dermatol Surg.* 1975;1:21-4. URL: <https://www.ncbi.nlm.nih.gov/pubmed/1223161>
393. Löser C, Rompel R, Möhrle M, Häfner H, Kunte C, Hassel J, et al. S1 guideline: microscopically controlled surgery (MCS). *J Dtsch Dermatol Ges.* 2015;13(9):942-51. URL: <https://pubmed.ncbi.nlm.nih.gov/26882393/>
394. Kauvar AN, Arpey CJ, Hruza G, Olbricht SM, Bennett R, Mahmoud BH. Consensus for Nonmelanoma Skin Cancer Treatment, Part II: Squamous Cell Carcinoma, Including a Cost Analysis of Treatment Methods. *Dermatol Surg.* 2015;41:1214-40. URL: <https://www.ncbi.nlm.nih.gov/pubmed/26445288>
395. Breuninger H, Eigentler T, Häfner H, Leiter U. *J Dtsch Dermatol Ges.* 2019;17(10):999-1004. URL: <https://pubmed.ncbi.nlm.nih.gov/31631533/>

396. Moehrle M, Breuninger H, Röcken M. A confusing world: what to call histology of three-dimensional tumour margins?. *Journal of the European Academy of Dermatology and Venereology*. 2007;21:591-595. URL: <https://www.ncbi.nlm.nih.gov/pubmed/17447971>
397. Waldman A, Schmults C. Cutaneous Squamous Cell Carcinoma. *Hematol Oncol Clin North Am*. 2019;33(1):1-12. URL: <https://pubmed.ncbi.nlm.nih.gov/30497667/>
398. Hafner HM, Breuninger H, Moehrle M, Trilling B, Krimmel M. 3D histology-guided surgery for basal cell carcinoma and squamous cell carcinoma: recurrence rates and clinical outcome. *Int J Oral Maxillofac Surg*. 2011;40:943-8. URL: <https://www.ncbi.nlm.nih.gov/pubmed/21600736>
399. Griffiths RW, Feeley K, Suvarna SK. Audit of clinical and histological prognostic factors in primary invasive squamous cell carcinoma of the skin: assessment in a minimum 5 year follow-up study after conventional excisional surgery. *Br J Plast Surg*. 2002;55:287-92. URL: <https://www.ncbi.nlm.nih.gov/pubmed/12160533>
400. Lansbury L, Bath-Hextall F, Perkins W, Stanton W, Leonardi-Bee J. Interventions for non-metastatic squamous cell carcinoma of the skin: systematic review and pooled analysis of observational studies. *Bmj*. 2013;347:f6153. URL: <https://www.ncbi.nlm.nih.gov/pubmed/24191270>
401. Jenkins G, Smith AB, Kanatas AN, Houghton DR, Telfer MR. Anatomical restrictions in the surgical excision of scalp squamous cell carcinomas: does this affect local recurrence and regional nodal metastases?. *Int J Oral Maxillofac Surg*. 2014;43:142-6. URL: <https://www.ncbi.nlm.nih.gov/pubmed/24128939>
402. Baker NJ, Webb AA, Macpherson D. Surgical management of cutaneous squamous cell carcinoma of the head and neck. *Br J Oral Maxillofac Surg*. 2001;39:87-90. URL: <https://www.ncbi.nlm.nih.gov/pubmed/11286440>
403. Chren M, Linos E, Torres JS, Stuart SE, Parvataneni R, Boscardin WJ. Tumor Recurrence 5 Years after Treatment of Cutaneous Basal Cell Carcinoma and Squamous Cell Carcinoma. *Journal of Investigative Dermatology*. 2013;133:1188-1196. URL: <https://www.ncbi.nlm.nih.gov/pmc/articles/PMC3711403/>
404. Sepehrpou S, Dawood O, Hatter S, Williams L, Zahd Z, Liebmann R, et al. An assessment of histological margins and recurrence of completely excised cutaneous SCC. *J Plast Reconstr Aesthet Surg*. 2020;73(5):899-903. URL: <https://pubmed.ncbi.nlm.nih.gov/32184053/>
405. Thiem D, Scharr K, Pabst A, Saka B, Kämmerer P. Facial cutaneous squamous cell carcinoma - microscopic safety margins and their impact on developing local recurrences. *J Craniomaxillofac Surg*. 2020;48(1):49-55. URL: <https://pubmed.ncbi.nlm.nih.gov/31810842/>
406. Perkins W. Who should have Mohs micrographic surgery?. *Curr Opin Otolaryngol Head Neck Surg*. 2010;18:283-9. URL: <https://www.ncbi.nlm.nih.gov/pubmed/20613530>
407. Leibovitch I, Huilgol SC, Selva D, Hill D, Richards S, Paver R. Cutaneous squamous cell carcinoma treated with Mohs micrographic surgery in Australia II Perineural invasion. *J Am Acad Dermatol*. 2005;53:261-6. URL: <https://www.ncbi.nlm.nih.gov/pubmed/16021121>
408. Robins P, Dzubow LM, Rigel DS. Squamous-Cell Carcinoma Treated by Mohs' Surgery. *The Journal of Dermatologic Surgery and Oncology*. 1981;7:800-801. URL: <http://dx.doi.org/10.1111/j.1524-4725.1981.tb00168.x>
409. Mohs FE, Snow SN. Microscopically controlled surgical treatment for squamous cell carcinoma of the lower lip. *Surg Gynecol Obstet*. 1985;160:37-41. URL: <https://www.ncbi.nlm.nih.gov/pubmed/3880619>

410. Holmkvist KA, Roenigk RK. Squamous cell carcinoma of the lip treated with Mohs micrographic surgery: outcome at 5 years. *J Am Acad Dermatol.* 1998;38:960-6. URL: <https://www.ncbi.nlm.nih.gov/pubmed/9632005>
411. Marrazzo G, Zitelli J, Brodland D. Clinical outcomes in high-risk squamous cell carcinoma patients treated with Mohs micrographic surgery alone. *J Am Acad Dermatol.* 2019;80(3):633-638. URL: <https://pubmed.ncbi.nlm.nih.gov/30244064/>
412. Kofler L, Breuninger H, Schulz C, Häfner H, Kofler K. Local Recurrence Rates of Skin Tumors After Resection With Complete Circumferential Peripheral and Deep Margin Assessment-Identification of High-Risk Entities. *Dermatol Surg.* 2021;47(2):e31-e36. URL: <https://pubmed.ncbi.nlm.nih.gov/33565775/>
413. Xiong D, Beal B, Varra V, Rodriguez M, Cundall H, Woody N, et al. Outcomes in intermediate-risk squamous cell carcinomas treated with Mohs micrographic surgery compared with wide local excision. *J Am Acad Dermatol.* 2020;82(5):1195-1204. URL: <https://pubmed.ncbi.nlm.nih.gov/31887322/>
414. Loser CR, Rempel R, Mohrle M, Hafner HM, Kunte C, Hassel J, et al. S1 guideline: microscopically controlled surgery (MCS). *J Dtsch Dermatol Ges.* 2015;13:942-51. URL: <https://www.ncbi.nlm.nih.gov/pubmed/20337775>
415. Allen JE, Stolle LB. Utility of sentinel node biopsy in patients with high-risk cutaneous squamous cell carcinoma. *Eur J Surg Oncol.* 2015;41:197-200. URL: <https://www.ncbi.nlm.nih.gov/pubmed/25468745>
416. Demir H, Isken T, Kus E, Ziya Tan Y, Isgoren S, Daglloz Gorur G, et al. Sentinel lymph node biopsy with a gamma probe in patients with high-risk cutaneous squamous cell carcinoma: follow-up results of sentinel lymph node-negative patients. *Nucl Med Commun.* 2011;32:1216-22. URL: <https://www.ncbi.nlm.nih.gov/pubmed/21968433>
417. Fukushima S, Masuguchi S, Igata T, Harada M, Aoi J, Miyashita A, et al. Evaluation of sentinel node biopsy for cutaneous squamous cell carcinoma. *J Dermatol.* 2014;41:539-41. URL: <https://www.ncbi.nlm.nih.gov/pubmed/24909214>
418. Ahmed MM, Moore BA, Schmalbach CE. Utility of head and neck cutaneous squamous cell carcinoma sentinel node biopsy: a systematic review. *Otolaryngol Head Neck Surg.* 2014;150:180-7. URL: <https://www.ncbi.nlm.nih.gov/pubmed/24201060>
419. Kwon S, Dong ZM, Wu PC. Sentinel lymph node biopsy for high-risk cutaneous squamous cell carcinoma: clinical experience and review of literature. *World J Surg Oncol.* 2011;9:80. URL: <https://www.ncbi.nlm.nih.gov/pubmed/21771334>
420. Ross AS, Schmults CD. Sentinel lymph node biopsy in cutaneous squamous cell carcinoma: a systematic review of the English literature. *Dermatol Surg.* 2006;32:1309-21. URL: <https://www.ncbi.nlm.nih.gov/pubmed/17083582>
421. Durham AB, Lowe L, Malloy KM, McHugh JB, Bradford CR, Chubb H, et al. Sentinel Lymph Node Biopsy for Cutaneous Squamous Cell Carcinoma on the Head and Neck. *JAMA Otolaryngol Head Neck Surg.* 2016;142:1171-1176. URL: <https://www.ncbi.nlm.nih.gov/pubmed/27438434>
422. Dwojak S, Emerick KS. Sentinel lymph node biopsy for cutaneous head and neck malignancies. *Expert Review of Anticancer Therapy.* 2015;15:305-315. URL: <https://doi.org/10.1586/14737140.2015.990441>
423. Gore SM, Shaw D, Martin RC, Kelder W, Roth K, Uren R, et al. Prospective study of sentinel node biopsy for high-risk cutaneous squamous cell carcinoma of the head and neck. *Head Neck.* 2016;38 Suppl 1:E884-9. URL: <https://www.ncbi.nlm.nih.gov/pubmed/25965008>

424. Krediet JT, Beyer M, Lenz K, Ulrich C, Lange-Asschenfeldt B, Stockfleth E, et al. Sentinel lymph node biopsy and risk factors for predicting metastasis in cutaneous squamous cell carcinoma. *Br J Dermatol*. 2015;172:1029-36. URL: <https://www.ncbi.nlm.nih.gov/pubmed/25362868>
425. Leiter U, Gutzmer R, Alter M, Ulrich C, Lonsdorf AS, Sachse MM, et al. Kutanes Plattenepithelkarzinom. *Der Hautarzt*. 2016;67:857-866. URL: <https://doi.org/10.1007/s00105-016-3875-2>
426. Navarrete-Dechent C, Veness MJ, Droppelmann N, Uribe P. Cutaneous squamous cell carcinoma and the emerging role of sentinel lymph node biopsy: a review. *Giornale italiano di dermatologia e venereologia : organo ufficiale, Societa italiana di dermatologia e sifilografia*. 2018; URL: <http://europepmc.org/abstract/MED/29485258>, <https://doi.org/10.23736/S0392-0488.18.05936-9>
427. Navarrete-Dechent C, Veness MJ, Droppelmann N, Uribe P. High-risk cutaneous squamous cell carcinoma and the emerging role of sentinel lymph node biopsy: A literature review. *J Am Acad Dermatol*. 2015;73:127-37. URL: <https://www.ncbi.nlm.nih.gov/pubmed/26089049>
428. Silberstein E, Sofrin E, Bogdanov-Berezovsky A, Nash M, Segal N. Lymph Node Metastasis in Cutaneous Head and Neck Squamous Cell Carcinoma. *Dermatol Surg*. 2015;41:1126-9. URL: <https://www.ncbi.nlm.nih.gov/pubmed/26372123>
429. Maruyama H, Tanaka R, Fujisawa Y, Nakamura Y, Ito S, Fujimoto M. Availability of sentinel lymph node biopsy for cutaneous squamous cell carcinoma. *J Dermatol*. 2016; URL: <https://www.ncbi.nlm.nih.gov/pubmed/27666747>
430. Kofler L, Kofler K, Schulz C, Breuninger H, Häfner H. Sentinel lymph node biopsy for high-thickness cutaneous squamous cell carcinoma. *Arch Dermatol Res*. 2021;313(2):119-126. URL: <https://pubmed.ncbi.nlm.nih.gov/32385689/>
431. Fu T, Aasi SZ, Hollmig ST. Management of High-Risk Squamous Cell Carcinoma of the Skin. *Curr Treat Options Oncol*. 2016;17:34. URL: <https://www.ncbi.nlm.nih.gov/pubmed/27262708>
432. Renzi C, Caggiati A, Mannooranparampil TJ, Passarelli F, Tartaglione G, Pennasilico GM, et al. Sentinel lymph node biopsy for high risk cutaneous squamous cell carcinoma: case series and review of the literature. *Eur J Surg Oncol*. 2007;33:364-9. URL: <https://www.ncbi.nlm.nih.gov/pubmed/17129703>
433. Samsanavicius D, Kaikaris V, Norvydas SJ, Liubauskas R, Valiukeviciene S, Makstiene J, et al. Sentinel lymph node biopsy for high-risk cutaneous squamous cell carcinoma: Analysis of recurrence-free survival. *Medicina (Kaunas)*. 2016;52:276-282. URL: <https://www.ncbi.nlm.nih.gov/pubmed/27746117>
434. Schmitt AR, Brewer JD, Bordeaux JS, Baum CL. Staging for cutaneous squamous cell carcinoma as a predictor of sentinel lymph node biopsy results: meta-analysis of American Joint Committee on Cancer criteria and a proposed alternative system. *JAMA Dermatol*. 2014;150:19-24. URL: <https://www.ncbi.nlm.nih.gov/pubmed/24226651>
435. Takahashi A, Imafuku S, Nakayama J, Nakaura J, Ito K, Shibayama Y. Sentinel node biopsy for high-risk cutaneous squamous cell carcinoma. *Eur J Surg Oncol*. 2014;40:1256-62. URL: <https://www.ncbi.nlm.nih.gov/pubmed/24953417>
436. Ebrahimi A, Moncrieff MD, Clark JR, Shannon KF, Gao K, Milross CG, et al. Predicting the pattern of regional metastases from cutaneous squamous cell carcinoma of the head and

- neck based on location of the primary. *Head Neck*. 2010;32:1288-94. URL: <https://www.ncbi.nlm.nih.gov/pubmed/20091686>
437. Gurney B, Newlands C. Management of regional metastatic disease in head and neck cutaneous malignancy 1 Cutaneous squamous cell carcinoma. *Br J Oral Maxillofac Surg*. 2014;52:294-300. URL: <https://www.ncbi.nlm.nih.gov/pubmed/24559975>
438. Martinez JC, Cook JL. High-risk cutaneous squamous cell carcinoma without palpable lymphadenopathy: is there a therapeutic role for elective neck dissection?. *Dermatol Surg*. 2007;33:410-20. URL: <https://www.ncbi.nlm.nih.gov/pubmed/17430374>
439. Wong WK, Morton RP. Elective management of cervical and parotid lymph nodes in stage N0 cutaneous squamous cell carcinoma of the head and neck: a decision analysis. *Eur Arch Otorhinolaryngol*. 2014;271:3011-9. URL: <https://www.ncbi.nlm.nih.gov/pubmed/24337900>
440. Newlands C, Currie R, Memon A, Whitaker S, Woolford T. Non-melanoma skin cancer: United Kingdom National Multidisciplinary Guidelines. *The Journal of Laryngology and Otology*. 2016;130:S125-S132. URL: <http://www.ncbi.nlm.nih.gov/pmc/articles/PMC4873942/>
441. Cannon RB, Dundar Y, Thomas A, Monroe MM, Buchmann LO, Witt BL, et al. Elective Neck Dissection for Head and Neck Cutaneous Squamous Cell Carcinoma with Skull Base Invasion. *Otolaryngol Head Neck Surg*. 2017;156:671-676. URL: <https://www.ncbi.nlm.nih.gov/pubmed/28366108>
442. Herman MP, Amdur RJ, Werning JW, Dziegielewski PT, Morris CG, Mendenhall WM. Elective Neck Management for Squamous Cell Carcinoma Metastatic to the Parotid-area Lymph Nodes. *International Journal of Radiation Oncology · Biology · Physics*. 94:932. URL: <http://dx.doi.org/10.1016/j.ijrobp.2015.12.247>
443. Ebrahimi A, Clark JR, Ahmadi N, Palme CE, Morgan GJ, Veness MJ. Prognostic significance of disease-free interval in head and neck cutaneous squamous cell carcinoma with nodal metastases. *Head Neck*. 2013;35:1138-43. URL: <https://www.ncbi.nlm.nih.gov/pubmed/23152126>
444. Kirke DN, Porceddu S, Wallwork BD, Panizza B, Coman WB. Pathologic occult neck disease in patients with metastatic cutaneous squamous cell carcinoma to the parotid. *Otolaryngol Head Neck Surg*. 2011;144:549-51. URL: <https://www.ncbi.nlm.nih.gov/pubmed/21493233>
445. Bumpous J. Metastatic cutaneous squamous cell carcinoma to the parotid and cervical lymph nodes: treatment and outcomes. *Curr Opin Otolaryngol Head Neck Surg*. 2009;17:122-5. URL: <https://www.ncbi.nlm.nih.gov/pubmed/19346945>
446. D'Souza J, Clark J. Management of the neck in metastatic cutaneous squamous cell carcinoma of the head and neck. *Curr Opin Otolaryngol Head Neck Surg*. 2011;19:99-105. URL: <https://www.ncbi.nlm.nih.gov/pubmed/21297477>
447. Kosec A, Svetina L, Luksic I. Significance of clinical stage, extent of surgery and outcome in cutaneous squamous cell carcinoma of the head and neck. *Int J Oral Maxillofac Surg*. 2013;42:82-8. URL: <https://www.ncbi.nlm.nih.gov/pubmed/23137734>
448. Schmidt C, Martin JM, Khoo E, Plank A, Grigg R. Outcomes of nodal metastatic cutaneous squamous cell carcinoma of the head and neck treated in a regional center. *Head Neck*. 2015;37:1808-15. URL: <https://www.ncbi.nlm.nih.gov/pubmed/24995842>
449. Veness MJ, Palme CE, Smith M, Cakir B, Morgan GJ, Kalnins I. Cutaneous head and neck squamous cell carcinoma metastatic to cervical lymph nodes (nonparotid): a better outcome

- with surgery and adjuvant radiotherapy. *Laryngoscope*. 2003;113:1827-33. URL: <https://www.ncbi.nlm.nih.gov/pubmed/14520114>
450. Gooris PJ, Vermey A, de Visscher JG, Burlage FR, Roodenburg JL. Supraomohyoid neck dissection in the management of cervical lymph node metastases of squamous cell carcinoma of the lower lip. *Head Neck*. 2002;24:678-83. URL: <https://www.ncbi.nlm.nih.gov/pubmed/12112542>
451. Kuscu O, Bajin MD, Suslu N, Hosal AS. The role of suprahyoid neck dissection in the treatment of squamous cell carcinoma of the lower lip: 20 years' experience at a Tertiary Center. *J Craniomaxillofac Surg*. 2016;44:1404-7. URL: <https://www.ncbi.nlm.nih.gov/pubmed/27427340>
452. Robbins KT, Clayman G, Levine PA, Medina J, Sessions R, Shaha A, et al. Neck dissection classification update: revisions proposed by the American Head and Neck Society and the American Academy of Otolaryngology-Head and Neck Surgery. *Arch Otolaryngol Head Neck Surg*. 2002;128:751-8. URL: <https://www.ncbi.nlm.nih.gov/pubmed/12117328>
453. Vartanian JG, Carvalho AL, de Araujo Filho MJ, Junior MH, Magrin J, Kowalski LP. Predictive factors and distribution of lymph node metastasis in lip cancer patients and their implications on the treatment of the neck. *Oral Oncol*. 2004;40:223-7. URL: <https://www.ncbi.nlm.nih.gov/pubmed/14693248>
454. Clark RR, Soutar DS. Lymph node metastases from auricular squamous cell carcinoma: A systematic review and meta-analysis. *J Plast Reconstr Aesthet Surg*. 2008;61:1140-7. URL: <https://www.ncbi.nlm.nih.gov/pubmed/18675609>
455. Peiffer N, Kutz JW, Myers LL, Isaacson B, Sumer BD, Truelson JM, et al. Patterns of regional metastasis in advanced stage cutaneous squamous cell carcinoma of the auricle. *Otolaryngol Head Neck Surg*. 2011;144:36-42. URL: <https://www.ncbi.nlm.nih.gov/pubmed/21493384>
456. Turner SJ, Morgan GJ, Palme CE, Veness MJ. Metastatic cutaneous squamous cell carcinoma of the external ear: a high-risk cutaneous subsite. *J Laryngol Otol*. 2010;124:26-31. URL: <https://www.ncbi.nlm.nih.gov/pubmed/19775493>
457. Werner JA. Patterns of metastasis in head and neck cancer. *Cancer Treat Res* 135:203-207. 2007; URL: <https://pubmed.ncbi.nlm.nih.gov/17953418/>
458. Uren RF. Lymphatic drainage of the skin. *Ann Surg Oncol*. 2004;11:179s-85s. URL: <https://www.ncbi.nlm.nih.gov/pubmed/15023748>
459. Vauterin TJ, Veness MJ, Morgan GJ, Poulsen MG, O'Brien CJ. Patterns of lymph node spread of cutaneous squamous cell carcinoma of the head and neck. *Head Neck*. 2006;28:785-91. URL: <https://www.ncbi.nlm.nih.gov/pubmed/16783833>
460. Hoetzenecker W, Guenova E, Böttinger T, Häfner H, Breuninger H. Mapping of specific sentinel node locations for skin cancer of the head. *Eur J Dermatol*. 21(3):354-8. URL: <https://pubmed.ncbi.nlm.nih.gov/21680279/>
461. Shao A, Wong DKC, McIvor NP, Mylnarek AM, Chaplin JM, Izzard ME, et al. Parotid metastatic disease from cutaneous squamous cell carcinoma: Prognostic role of facial nerve sacrifice, lateral temporal bone resection, immune status and P-stage. *Head & Neck*. 2014;36:545-550. URL: <https://onlinelibrary.wiley.com/doi/abs/10.1002/hed.23323>
462. Sweeny L, Zimmerman T, Carroll WR, Schmalbach CE, Day KE, Rosenthal EL. Head and neck cutaneous squamous cell carcinoma requiring parotidectomy: prognostic indicators and treatment selection. *Otolaryngol Head Neck Surg*. 2014;150:610-7. URL: <https://www.ncbi.nlm.nih.gov/pubmed/24474713>

463. Dunne AA, Budach VG, Wagner W, Werner JA. Management of N0 neck in head and neck cancer: current controversies. *Onkologie*. 2004;27:363-7. URL: <https://www.ncbi.nlm.nih.gov/pubmed/15347891>
464. Ferlito A, Rinaldo A, Silver CE, Gourin CG, Shah JP, Clayman GL, et al. Elective and therapeutic selective neck dissection. *Oral Oncol*. 2006;42:14-25. URL: <https://www.ncbi.nlm.nih.gov/pubmed/15979381>
465. Ferlito A, Rinaldo A, Silver CE, Shah JP, Suarez C, Medina JE, et al. Neck dissection: then and now. *Auris Nasus Larynx*. 2006;33:365-74. URL: <https://www.ncbi.nlm.nih.gov/pubmed/16889923>
466. Nissen CV, Heerfordt IM, Wiegell SR, Mikkelsen CS, Wulf HC. Pretreatment with 5-Fluorouracil Cream Enhances the Efficacy of Daylight-mediated Photodynamic Therapy for Actinic Keratosis. *Acta Derm Venereol*. 2017;97:617-621. URL: <https://www.ncbi.nlm.nih.gov/pubmed/28093604>
467. Werner JA, Dunne AA, Lippert BM. [Indications for neck operation in undiagnosed lymph node metastases 2 Neck dissection in the clinical N0 neck]. *Hno*. 2002;50:370-8; quiz 378-9. URL: <https://www.ncbi.nlm.nih.gov/pubmed/12063698>
468. Lu S, Lien W. Concurrent Radiotherapy With Cetuximab or Platinum-based Chemotherapy for Locally Advanced Cutaneous Squamous Cell Carcinoma of the Head and Neck. *Am J Clin Oncol*. 2018;41(1):95-99. URL: <https://pubmed.ncbi.nlm.nih.gov/26353121/>
469. Mendenhall WM, Amdur RJ, Hinerman RW, Cognetta AB, Mendenhall NP. Radiotherapy for cutaneous squamous and basal cell carcinomas of the head and neck. *Laryngoscope*. 2009;119:1994-9. URL: <https://www.ncbi.nlm.nih.gov/pubmed/19688856>
470. Adelstein DJ, Lavertu P, Saxton JP, Secic M, Wood BG, Wanamaker JR, et al. Mature results of a phase III randomized trial comparing concurrent chemoradiotherapy with radiation therapy alone in patients with stage III and IV squamous cell carcinoma of the head and neck. *Cancer*. 2000;88:876-83. URL: <https://www.ncbi.nlm.nih.gov/pubmed/10679658>
471. Cooper JS, Zhang Q, Pajak TF, Forastiere AA, Jacobs J, Saxman SB, et al. Long-term follow-up of the RTOG 9501/intergroup phase III trial: postoperative concurrent radiation therapy and chemotherapy in high-risk squamous cell carcinoma of the head and neck. *Int J Radiat Oncol Biol Phys*. 2012;84:1198-205. URL: <https://www.ncbi.nlm.nih.gov/pubmed/22749632>
472. Nottage MK, Lin C, Hughes BG, Kenny L, Smith DD, Houston K, et al. Prospective study of definitive chemoradiation in locally or regionally advanced squamous cell carcinoma of the skin. *Head Neck*. 2017;39:679-683. URL: <https://www.ncbi.nlm.nih.gov/pubmed/28032670>
473. Mendenhall WM, Amdur RJ, Hinerman RW, Werning JW, Malyapa RS, Villaret DB, et al. Skin cancer of the head and neck with perineural invasion. *Am J Clin Oncol*. 2007;30:93-6. URL: <https://www.ncbi.nlm.nih.gov/pubmed/17278901>
474. Tanvetyanon T, Padhya T, McCaffrey J, Kish JA, Deconti RC, Trotti A, et al. Postoperative concurrent chemotherapy and radiotherapy for high-risk cutaneous squamous cell carcinoma of the head and neck. *Head Neck*. 2015;37:840-5. URL: <https://www.ncbi.nlm.nih.gov/pubmed/24623654>
475. Zhang J, Wang Y, Wijaya W, Liang Z, Chen J. Efficacy and prognostic factors of adjuvant radiotherapy for cutaneous squamous cell carcinoma: A systematic review and meta-analysis. *J Eur Acad Dermatol Venereol*. 2021;35(9):1777-1787. URL: <https://pubmed.ncbi.nlm.nih.gov/33930213/>

476. Sahovaler A, Krishnan R, Yeh D, Zhou Q, Palma D, Fung K, et al. Outcomes of Cutaneous Squamous Cell Carcinoma in the Head and Neck Region With Regional Lymph Node Metastasis: A Systematic Review and Meta-analysis. *JAMA Otolaryngol Head Neck Surg.* 2019;145(4):352-360. URL: <https://pubmed.ncbi.nlm.nih.gov/30844021/>
477. Veness MJ. Treatment recommendations in patients diagnosed with high-risk cutaneous squamous cell carcinoma. *Australas Radiol.* 2005;49:365-76. URL: <https://www.ncbi.nlm.nih.gov/pubmed/16174174>
478. Han A, Ratner D. What is the role of adjuvant radiotherapy in the treatment of cutaneous squamous cell carcinoma with perineural invasion?. *Cancer.* 2007;109:1053-9. URL: <https://www.ncbi.nlm.nih.gov/pubmed/17279578>
479. Wang JT, Palme CE, Morgan GJ, Gebiski V, Wang AY, Veness MJ. Predictors of outcome in patients with metastatic cutaneous head and neck squamous cell carcinoma involving cervical lymph nodes: Improved survival with the addition of adjuvant radiotherapy. *Head Neck.* 2012;34:1524-8. URL: <https://www.ncbi.nlm.nih.gov/pubmed/22109745>
480. Veness MJ, Morgan GJ, Palme CE, Gebiski V. Surgery and adjuvant radiotherapy in patients with cutaneous head and neck squamous cell carcinoma metastatic to lymph nodes: combined treatment should be considered best practice. *Laryngoscope.* 2005;115:870-5. URL: <https://www.ncbi.nlm.nih.gov/pubmed/15867656>
481. Porceddu S, Bressel M, Poulsen M, Stoneley A, Veness M, Kenny L, et al. Postoperative Concurrent Chemoradiotherapy Versus Postoperative Radiotherapy in High-Risk Cutaneous Squamous Cell Carcinoma of the Head and Neck: The Randomized Phase III TROG 0501 Trial. *J Clin Oncol.* 2018;36(13):1275-1283. URL: <https://pubmed.ncbi.nlm.nih.gov/29537906/>
482. Trosman S, Zhu A, Nicolli E, Leibowitz J, Sargi Z. High-Risk Cutaneous Squamous Cell Cancer of the Head and Neck: Risk Factors for Recurrence and Impact of Adjuvant Treatment. *Laryngoscope.* 2021;131(1):E136-E143. URL: <https://pubmed.ncbi.nlm.nih.gov/32065413/>
483. Palmer J, Schneider C, Hockstein N, Hanlon A, Silberg J, Strasser J, et al. Combination of post-operative radiotherapy and cetuximab for high-risk cutaneous squamous cell cancer of the head and neck: A propensity score analysis. *Oral Oncol.* 2018;78:102-107. URL: <https://pubmed.ncbi.nlm.nih.gov/29496036/>
484. Sapijaszko M, Zloty D, Bourcier M, Poulin Y, Janiszewski P, Ashkenas J. Non-melanoma Skin Cancer in Canada Chapter 5: Management of Squamous Cell Carcinoma. *J Cutan Med Surg.* 2015;19:249-59. URL: <https://www.ncbi.nlm.nih.gov/pubmed/25922470>
485. Waxweiler W, Sigmon JR, Sheehan DJ. Adjunctive radiotherapy in the treatment of cutaneous squamous cell carcinoma with perineural invasion. *J Surg Oncol.* 2011;104:104-5. URL: <https://www.ncbi.nlm.nih.gov/pubmed/21360531>
486. Amoils M, Lee CS, Sunwoo J, Aasi SZ, Hara W, Kim J, et al. Node-positive cutaneous squamous cell carcinoma of the head and neck: Survival, high-risk features, and adjuvant chemoradiotherapy outcomes. *Head Neck.* 2017;39:881-885. URL: <https://www.ncbi.nlm.nih.gov/pubmed/28252823>
487. Chen AM, Grekin RC, Garcia J, Bucci MK, Margolis LW. Radiation therapy for cutaneous squamous cell carcinoma involving the parotid area lymph nodes: dose and volume considerations. *Int J Radiat Oncol Biol Phys.* 2007;69:1377-80. URL: <https://www.ncbi.nlm.nih.gov/pubmed/17689882>
488. Jol JA, van Velthuysen ML, Hilgers FJ, Keus RB, Neering H, Balm AJ. Treatment results of regional metastasis from cutaneous head and neck squamous cell carcinoma. *Eur J Surg Oncol.* 2003;29:81-6. URL: <https://www.ncbi.nlm.nih.gov/pubmed/12559082>

489. Chua MS, Veness MJ, Morgan G, Shakespeare T, Hehir A, GebSKI V, et al. Parotid lymph-node metastases from cutaneous squamous-cell carcinomas: treatment outcome and prognostic factors following surgery and adjuvant radiotherapy. *Australas Radiol.* 2002;46:174-9. URL: <https://www.ncbi.nlm.nih.gov/pmc/articles/PMC3422189/>
490. Hong TS, Kriesel KJ, Hartig GK, Harari PM. Parotid area lymph node metastases from cutaneous squamous cell carcinoma: implications for diagnosis, treatment, and prognosis. *Head Neck.* 2005;27:851-6. URL: <https://www.ncbi.nlm.nih.gov/pubmed/16114004>
491. Strassen U, Hofauer B, Jacobi C, Knopf A. Management of locoregional recurrence in cutaneous squamous cell carcinoma of the head and neck. *Eur Arch Otorhinolaryngol.* 2017;274:501-506. URL: <https://www.ncbi.nlm.nih.gov/pubmed/27498202>
492. Bertino G, Sersa G, De Terlizzi F, Occhini A, Plaschke CC, Groselj A, et al. European Research on Electrochemotherapy in Head and Neck Cancer (EURECA) project: Results of the treatment of skin cancer. *Eur J Cancer.* 2016;63:41-52. URL: <https://www.ncbi.nlm.nih.gov/pubmed/27267144>
493. Campana LG, Testori A, Curatolo P, Quaglino P, Mocellin S, Framarini M, et al. Treatment efficacy with electrochemotherapy: A multi-institutional prospective observational study on 376 patients with superficial tumors. *Eur J Surg Oncol.* 2016;42:1914-1923. URL: <https://www.ncbi.nlm.nih.gov/pubmed/27424789>
494. Kreuter A, Eijk T, Lehmann P, Fischer M, Horn T, Assaf C, et al. Electrochemotherapy in advanced skin tumors and cutaneous metastases – a retrospective multicenter analysis. *J Dtsch Dermatol Ges.* 2015;13:308-315. URL: <https://pubmed.ncbi.nlm.nih.gov/25819239/>
495. Pickering C, Zhou J, Lee J, Drummond J, Peng S, Saade R, et al. Mutational landscape of aggressive cutaneous squamous cell carcinoma. *Clin Cancer Res.* 2014;20(24):6582-92. URL: <https://pubmed.ncbi.nlm.nih.gov/25303977/>
496. Amaral T, Osewold M, Presser D, Meiwes A, Garbe C, Leiter U. Advanced cutaneous squamous cell carcinoma: real world data of patient profiles and treatment patterns. *J Eur Acad Dermatol Venereol.* 2019;33 Suppl 8:44-51. URL: <https://pubmed.ncbi.nlm.nih.gov/31658392/>
497. Salzmann M, Leiter U, Loquai C, Zimmer L, Ugurel S, Gutzmer R, et al. Programmed cell death protein 1 inhibitors in advanced cutaneous squamous cell carcinoma: real-world data of a retrospective, multicenter study. *Eur J Cancer.* 2020;138:125-132. URL: <https://pubmed.ncbi.nlm.nih.gov/32882466/>
498. Migden MR, Rischin D, Schmults CD, Guminski A, Hauschild A, Lewis KD, et al. PD-1 Blockade with Cemiplimab in Advanced Cutaneous Squamous-Cell Carcinoma. *N Engl J Med.* 2018; URL: <https://www.ncbi.nlm.nih.gov/pubmed/29863979>
499. Rischin D, Migden M, Lim A, Schmults C, Khushalani N, Hughes B, et al. Phase 2 study of cemiplimab in patients with metastatic cutaneous squamous cell carcinoma: primary analysis of fixed-dosing, long-term outcome of weight-based dosing. *J Immunother Cancer.* 2020;8(1): URL: <https://pubmed.ncbi.nlm.nih.gov/32554615/>
500. Migden M, Khushalani N, Chang A, Lewis K, Schmults C, Hernandez-Aya L, et al. Cemiplimab in locally advanced cutaneous squamous cell carcinoma: results from an open-label, phase 2, single-arm trial. *Lancet Oncol.* 2020;21(2):294-305. URL: <https://pubmed.ncbi.nlm.nih.gov/31952975/>
501. Maubec E, Boubaya M, Petrow P, Beylot-Barry M, Basset-Seguín N, Deschamps L, et al. Phase II Study of Pembrolizumab As First-Line, Single-Drug Therapy for Patients With

- Unresectable Cutaneous Squamous Cell Carcinomas. *J Clin Oncol*. 2020;38(26):3051-3061. URL: <https://pubmed.ncbi.nlm.nih.gov/32730186/>
502. Grob J, Gonzalez R, Basset-Seguín N, Vornicova O, Schachter J, Joshi A, et al. Pembrolizumab Monotherapy for Recurrent or Metastatic Cutaneous Squamous Cell Carcinoma: A Single-Arm Phase II Trial (KEYNOTE-629). *J Clin Oncol*. 2020;38(25):2916-2925. URL: <https://pubmed.ncbi.nlm.nih.gov/32673170/>
503. Behshad R, Garcia-Zuazaga J, Bordeaux JS. Systemic treatment of locally advanced nonmetastatic cutaneous squamous cell carcinoma: a review of the literature. *Br J Dermatol*. 2011;165:1169-77. URL: <http://onlinelibrary.wiley.com/doi/10.1111/j.1365-2133.2011.10524.x/abstract>
504. Hillen U, Leiter U, Haase S, Kaufmann R, Becker J, Gutzmer R, et al. Advanced cutaneous squamous cell carcinoma: A retrospective analysis of patient profiles and treatment patterns-Results of a non-interventional study of the DeCOG. *Eur J Cancer*. 2018;96:34-43. URL: <https://pubmed.ncbi.nlm.nih.gov/29665511/>
505. Guthrie TH, Porubsky ES, Luxenberg MN, Shah KJ, Wurtz KL, Watson PR. Cisplatin-based chemotherapy in advanced basal and squamous cell carcinomas of the skin: results in 28 patients including 13 patients receiving multimodality therapy. *J Clin Oncol*. 1990;8:342-6. URL: <https://www.ncbi.nlm.nih.gov/pubmed/2405109>
506. Sadek H, Azli N, Wendling JL, Cvitkovic E, Rahal M, Mamelle G, et al. Treatment of advanced squamous cell carcinoma of the skin with cisplatin, 5-fluorouracil, and bleomycin. *Cancer*. 1990;66:1692-6. URL: <https://www.ncbi.nlm.nih.gov/pubmed/1698529>
507. Khansur T, Kennedy A. Cisplatin and 5-fluorouracil for advanced locoregional and metastatic squamous cell carcinoma of the skin. *Cancer*. 1991;67:2030-2. URL: <https://www.ncbi.nlm.nih.gov/pubmed/2004320>
508. Cartei G, Cartei F, Interlandi G, Meneghini G, Jop A, Zingone G, et al. Oral 5-fluorouracil in squamous cell carcinoma of the skin in the aged. *Am J Clin Oncol*. 2000;23:181-4. URL: <https://www.ncbi.nlm.nih.gov/pubmed/10776981>
509. Lippman SM, Parkinson DR, Itri LM, Weber RS, Schantz SP, Ota DM, et al. 13-cis-retinoic acid and interferon alpha-2a: effective combination therapy for advanced squamous cell carcinoma of the skin. *J Natl Cancer Inst*. 1992;84:235-41. URL: <https://www.ncbi.nlm.nih.gov/pubmed/1734084>
510. Shin DM, Khuri FR, Glisson BS, Ginsberg L, Papadimitrakopoulou VM, Clayman G, et al. Phase II study of paclitaxel, ifosfamide, and carboplatin in patients with recurrent or metastatic head and neck squamous cell carcinoma. *Cancer*. 2001;91:1316-23. URL: <https://www.ncbi.nlm.nih.gov/pubmed/11283932>
511. Huis In 't Veld E, Grünhagen D, Deroose J, Nijsten T, Wouters M, Verhoef C, et al. Isolated limb perfusion for unresectable extremity cutaneous squamous cell carcinoma; an effective limb saving strategy. *Br J Cancer*. 2018;119(4):429-434. URL: <https://pubmed.ncbi.nlm.nih.gov/29961756/>
512. Joseph K, Alkaabi K, Warkentin H, Ghosh S, Jha N, Smylie M, et al. Cetuximab-radiotherapy combination in the management of locally advanced cutaneous squamous cell carcinoma. *J Med Imaging Radiat Oncol*. 2019;63(2):257-263. URL: <https://pubmed.ncbi.nlm.nih.gov/30549229/>
513. Maubec E, Petrow P, Scheer-Senyarich I, Duvillard P, Lacroix L, Gelly J, et al. Phase II study of cetuximab as first-line single-drug therapy in patients with unresectable squamous

- cell carcinoma of the skin. *J Clin Oncol*. 2011;29:3419-26. URL: <https://www.ncbi.nlm.nih.gov/pubmed/21810686>
514. Foote MC, McGrath M, Guminski A, Hughes BG, Meakin J, Thomson D, et al. Phase II study of single-agent panitumumab in patients with incurable cutaneous squamous cell carcinoma. *Ann Oncol*. 2014;25:2047-52. URL: <https://www.ncbi.nlm.nih.gov/pubmed/25091317>
515. Lewis CM, Glisson BS, Feng L, Wan F, Tang X, Wistuba I, et al. A phase II study of gefitinib for aggressive cutaneous squamous cell carcinoma of the head and neck. *Clin Cancer Res*. 2012;18:1435-46. URL: <http://clincancerres.aacrjournals.org/content/clincanres/18/5/1435.full.pdf>
516. Heath CH, Deep NL, Nabell L, Carroll WR, Desmond R, Clemons L, et al. Phase I Study of Erlotinib Plus Radiation Therapy in Patients with Advanced Cutaneous Squamous Cell Carcinoma. *Int J Radiat Oncol Biol Phys*. 2013;85:1275-81. URL: <https://www.ncbi.nlm.nih.gov/pmc/articles/PMC3607201/pdf/nihms428673.pdf>
517. Jenni D, Karpova M, Mühleisen B, Mangana J, Dreier J, Hafner J, et al. A prospective clinical trial to assess lapatinib effects on cutaneous squamous cell carcinoma and actinic keratosis. *ESMO Open*. 2016;1: URL: <https://pubmed.ncbi.nlm.nih.gov/27843579/>
518. Cavalieri S, Perrone F, Miceli R, Ascierto P, Locati L, Bergamini C, et al. Efficacy and safety of single-agent pan-human epidermal growth factor receptor (HER) inhibitor dacomitinib in locally advanced unresectable or metastatic skin squamous cell cancer. *Eur J Cancer*. 2018;97:7-15. URL: <https://pubmed.ncbi.nlm.nih.gov/29734047/>
519. Gold K, Kies M, William W, Johnson F, Lee J, Glisson B. Erlotinib in the treatment of recurrent or metastatic cutaneous squamous cell carcinoma: A single-arm phase 2 clinical trial. *Cancer*. 2018;124(10):2169-2173. URL: <https://pubmed.ncbi.nlm.nih.gov/29579331/>
520. Leiter U, Loquai C, Reinhardt L, Rafei-Shamsabadi D, Gutzmer R, Kaehler K, et al. Immune checkpoint inhibition therapy for advanced skin cancer in patients with concomitant hematological malignancy: a retrospective multicenter DeCOG study of 84 patients. *J Immunother Cancer*. 2020;8(2): URL: <https://pubmed.ncbi.nlm.nih.gov/33093156/>
521. Salgo R, Gossman J, Schofer H, Kachel HG, Kuck J, Geiger H, et al. Switch to a sirolimus-based immunosuppression in long-term renal transplant recipients: reduced rate of (pre-)malignancies and nonmelanoma skin cancer in a prospective, randomized, assessor-blinded, controlled clinical trial. *Am J Transplant*. 2010;10:1385-93. URL: <https://www.ncbi.nlm.nih.gov/pubmed/20121752>
522. Campbell SB, Walker R, Tai SS, Jiang Q, Russ GR. Randomized controlled trial of sirolimus for renal transplant recipients at high risk for nonmelanoma skin cancer. *Am J Transplant*. 2012;12:1146-56. URL: <https://www.ncbi.nlm.nih.gov/pubmed/22420843>
523. Euvrard S, Morelon E, Rostaing L, Goffin E, Brocard A, Tromme I, et al. Sirolimus and Secondary Skin-Cancer Prevention in Kidney Transplantation. *New England Journal of Medicine*. 2012;367:329-339. URL: <http://www.nejm.org/doi/full/10.1056/NEJMoa1204166>, <http://www.nejm.org/doi/pdf/10.1056/NEJMoa1204166>
524. Hoogendijk-van den Akker JM, Harden PN, Hoitsma AJ, Proby CM, Wolterbeek R, Bouwes Bavinck JN, et al. Two-year randomized controlled prospective trial converting treatment of stable renal transplant recipients with cutaneous invasive squamous cell carcinomas to sirolimus. *J Clin Oncol*. 2013;31:1317-23. URL: <https://www.ncbi.nlm.nih.gov/pubmed/23358973>

525. Tio M, Rai R, Ezeoke O, McQuade J, Zimmer L, Khoo C, et al. Anti-PD-1/PD-L1 immunotherapy in patients with solid organ transplant, HIV or hepatitis B/C infection. *Eur J Cancer*. 2018;104:137-144. URL: <https://pubmed.ncbi.nlm.nih.gov/30347289/>
526. Lehmann K, Eshmunov D, Bauerfeind P, Gubler C, Veit-Haibach P, Weber A, et al. *Eur J Surg Oncol*. 2017;43(1):196-202. URL: <https://pubmed.ncbi.nlm.nih.gov/27692533/>
527. Hitt R, Irigoyen A, Cortes-Funes H, Grau JJ, Garcia-Saenz JA, Cruz-Hernandez JJ. Phase II study of the combination of cetuximab and weekly paclitaxel in the first-line treatment of patients with recurrent and/or metastatic squamous cell carcinoma of head and neck. *Ann Oncol*. 2012;23:1016-22. URL: <https://www.ncbi.nlm.nih.gov/pubmed/21865152>
528. Vermorken JB, Mesia R, Rivera F, Remenar E, Kawecki A, Rottey S, et al. Platinum-Based Chemotherapy plus Cetuximab in Head and Neck Cancer. *New England Journal of Medicine*. 2008;359:1116-1127. URL: <http://www.nejm.org/doi/full/10.1056/NEJMoa0802656>
529. Vardhan M, Flaminio Z, Sapru S, Tilley C, Fu M, Comfort C, et al. The Microbiome, Malignant Fungating Wounds, and Palliative Care. *Front Cell Infect Microbiol*. 2019;9:373. URL: <https://pubmed.ncbi.nlm.nih.gov/31737576/>
530. Kähler K, Egberts F, Gutzmer R. Palliative treatment of skin metastases in dermatology. *J Dtsch Dermatol Ges*. 2013;11(11):1041-5; quiz 1046. URL: <https://pubmed.ncbi.nlm.nih.gov/24015966/>
531. Probst U, Fuhrmann I, Beyer L, Wiggermann P. Electrochemotherapy as a New Modality in Interventional Oncology: A Review. *Technol Cancer Res Treat*. 2018;17:1533033818785329. URL: <https://pubmed.ncbi.nlm.nih.gov/29986632/>
532. Leitlinienprogramm Onkologie (Deutsche Krebsgesellschaft, Deutsche Krebshilfe, AWMF): Palliativmedizin für Patienten mit einer nicht-heilbaren Krebserkrankung. Langversion 2.2. 2020; URL: <https://www.leitlinienprogramm-onkologie.de/leitlinien/palliativmedizin/>
533. Teunissen S, Wesker W, Kruitwagen C, de Haes H, Voest E, de Graeff A. Symptom prevalence in patients with incurable cancer: a systematic review. *J Pain Symptom Manage*. 2007;34(1):94-104. URL: <https://pubmed.ncbi.nlm.nih.gov/17509812/>
534. McCarthy WH, Shaw HM, Thompson JF, Milton GW. Time and frequency of recurrence of cutaneous stage I malignant melanoma with guidelines for follow-up study. *Surgery, gynecology & obstetrics*. 1988;166:497-502. URL: <http://europepmc.org/abstract/MED/3375961>
535. Wassberg C, Thorn M, Yuen J, Ringborg U, Hakulinen T. Second primary cancers in patients with squamous cell carcinoma of the skin: a population-based study in Sweden. *Int J Cancer*. 1999;80:511-5. URL: <https://www.ncbi.nlm.nih.gov/pubmed/9935149>
536. Balch CM, Gershenwald JE, Soong SJ, Thompson JF, Atkins MB, Byrd DR, et al. Final version of 2009 AJCC melanoma staging and classification. *J Clin Oncol*. 2009;27:6199-206. URL: <https://www.ncbi.nlm.nih.gov/pubmed/19917835>
537. Dancey A, Rayatt S, Courthold J, Roberts J. Views of UK melanoma patients on routine follow-up care. *Br J Plast Surg*. 2005;58:245-50. URL: <https://www.ncbi.nlm.nih.gov/pubmed/15710122>
538. Wehner M, Linos E, Parvataneni R, Stuart S, Boscardin W, Chren M. Timing of subsequent new tumors in patients who present with basal cell carcinoma or cutaneous squamous cell carcinoma. *JAMA Dermatol*. 2015;151(4):382-8. URL: <https://pubmed.ncbi.nlm.nih.gov/25588079/>

539. Madeleine M, Patel N, Plasmeijer E, Engels E, Bouwes Bavinck J, Toland A, et al. Epidemiology of keratinocyte carcinomas after organ transplantation. *Br J Dermatol*. 2017;177(5):1208-1216. URL: <https://pubmed.ncbi.nlm.nih.gov/28994104/>
540. Xing Y, Bronstein Y, Ross MI, Askew RL, Lee JE, Gershenwald JE, et al. Contemporary diagnostic imaging modalities for the staging and surveillance of melanoma patients: a meta-analysis. *J Natl Cancer Inst*. 2011;103:129-42. URL: <https://www.ncbi.nlm.nih.gov/pmc/articles/PMC3022618/pdf/djq455.pdf>
541. Bafounta ML, Beauchet A, Chagnon S, Saiag P. Ultrasonography or palpation for detection of melanoma nodal invasion: a meta-analysis. *Lancet Oncol*. 2004;5:673-80. URL: <https://www.ncbi.nlm.nih.gov/pubmed/15522655>
542. Sumi M, Ohki M, Nakamura T. Comparison of Sonography and CT for Differentiating Benign from Malignant Cervical Lymph Nodes in Patients with Squamous Cell Carcinoma of the Head and Neck. *American Journal of Roentgenology*. 2001;176:1019-1024. URL: <https://doi.org/10.2214/ajr.176.4.1761019>
543. Richards PS, Peacock TE. The role of ultrasound in the detection of cervical lymph node metastases in clinically N0 squamous cell carcinoma of the head and neck. *Cancer Imaging*. 2007;7:167-178. URL: <http://www.ncbi.nlm.nih.gov/pmc/articles/PMC2151323/>
544. Davis SD. CT evaluation for pulmonary metastases in patients with extrathoracic malignancy. *Radiology*. 1991;180:1-12. URL: <https://www.ncbi.nlm.nih.gov/pubmed/2052672>
545. Hausmann D, Jochum S, Utikal J, Hoffmann RC, Zechmann C, Neff KW, et al. Comparison of the diagnostic accuracy of whole-body MRI and whole-body CT in stage III/IV malignant melanoma. *JDDG: Journal der Deutschen Dermatologischen Gesellschaft*. 2011;9:212-221. URL: <http://dx.doi.org/10.1111/j.1610-0387.2011.07614.x>
546. Galloway TJ, Morris CG, Mancuso AA, Amdur RJ, Mendenhall WM. Impact of radiographic findings on prognosis for skin carcinoma with clinical perineural invasion. *Cancer*. 2005;103:1254-1257. URL: <http://dx.doi.org/10.1002/cncr.20913>
547. Mendenhall W, Ferlito A, Takes R, Bradford C, Corry J, Fagan J, et al. Cutaneous head and neck basal and squamous cell carcinomas with perineural invasion. *Oral Oncol*. 2012;48(10):918-922. URL: <https://pubmed.ncbi.nlm.nih.gov/22425152/>
548. Hao DS, Ng DS. Magnetic Resonance Imaging versus Clinical Palpation in Evaluating Cervical Metastasis from Head and Neck Cancer. *Otolaryngology-Head and Neck Surgery*. 2000;123:324-327. URL: <http://journals.sagepub.com/doi/abs/10.1067/mhn.2000.105252>
549. Williams LS, Mancuso AA, Mendenhall WM. Perineural spread of cutaneous squamous and basal cell carcinoma: CT and MR detection and its impact on patient management and prognosis. *International Journal of Radiation Oncology · Biology · Physics*. 49:1061-1069. URL: [http://dx.doi.org/10.1016/S0360-3016\(00\)01407-3](http://dx.doi.org/10.1016/S0360-3016(00)01407-3)
550. Duncan JR, Carr D, Kaffenberger BH. The utility of positron emission tomography with and without computed tomography in patients with nonmelanoma skin cancer. *Journal of the American Academy of Dermatology*. 2016;75:186-196. URL: <http://dx.doi.org/10.1016/j.jaad.2016.01.045>
551. van der Leest R, Hollestein L, Liu L, Nijsten T, de Vries E. Risks of different skin tumour combinations after a first melanoma, squamous cell carcinoma and basal cell carcinoma in Dutch population-based cohorts: 1989-2009. *J Eur Acad Dermatol Venereol*. 2018;32(3):382-389. URL: <https://pubmed.ncbi.nlm.nih.gov/28898461/>

552. Lau A, Li M, Xie R, He Q, Chiu J. Opposed arsenite-induced signaling pathways promote cell proliferation or apoptosis in cultured lung cells. *Carcinogenesis*. 2004;25(1):21-8. URL: <https://pubmed.ncbi.nlm.nih.gov/14514659/>
553. Arsenical cancer; a review. *Br J Cancer*. 1947;1:192
554. Lichter M, Karagas M, Mott L, Spencer S, Stukel T, Greenberg E. Therapeutic ionizing radiation and the incidence of basal cell carcinoma and squamous cell carcinoma The New Hampshire Skin Cancer Study Group. *Arch Dermatol*. 2000;136(8):1007-11. URL: <https://pubmed.ncbi.nlm.nih.gov/10926736/>
555. Shore R. Radiation-induced skin cancer in humans. *Med Pediatr Oncol*. 2001;36(5):549-54. URL: <https://pubmed.ncbi.nlm.nih.gov/11340610/>
556. Sugita K, Yamamoto O, Suenaga Y. [Seven cases of radiation-induced cutaneous squamous cell carcinoma]. *J UOEH*. 2000;22(3):259-67. URL: <https://pubmed.ncbi.nlm.nih.gov/11019392/>
557. Voelter-Mahlknecht S, Scheriau R, Zwahr G, Koch B, Escobar Pinzon L, Drexler H, et al. Skin tumors among employees of a tar refinery: the current data and their implications. *Int Arch Occup Environ Health*. 2007;80(6):485-95. URL: <https://pubmed.ncbi.nlm.nih.gov/17093963/>
558. Bamberger Empfehlung. Empfehlung zur Begutachtung von arbeitsbedingten Hauterkrankungen und Hautkrebserkrankungen. 2017; URL: <https://publikationen.dguv.de/widgets/pdf/download/article/2058>
559. Ärztliches Zentrum für Qualität in der Medizin (ÄZQ), Gramsch E, Hoppe J, Jonitz G, Köhler A, Ollenschläger G, et al. Kompendium Q-M-A Qualitätsmanagement in der ambulanten Versorgung. 2008
560. Aertzliches Zentrum für Qualitaet in der Medizin (AeZQ). Manual Qualitaetsindikatoren Manual für Autoren. 2009;aezq Schriftenreihe: 36: URL: <http://www.aezq.de/mdb/edocs/pdf/schriftenreihe/schriftenreihe36.pdf>

Versions-Nummer: 2.0
version number:

Erstveröffentlichung: 07/2019
Initial release:

Überarbeitung von: 12/2022
Revision of:

Nächste Überprüfung geplant: 12/2027
Review planned:

The AMWF records and publishes the guidelines of the professional associations with the greatest possible care - yet the AWMF can not assume any responsibility for the accuracy of the content. **Espacially dosage information of the manufacturer must always be considered!**

Die AWMF erfasst und publiziert die Leitlinien der Fachgesellschaften mit größtmöglicher Sorgfalt - dennoch kann die AWMF für die Richtigkeit des Inhalts keine Verantwortung übernehmen. **Insbesondere bei Dosierungsangaben sind stets die Angaben der Hersteller zu beachten!**

autorisiert für die elektronische Publikation / authorized for electronic publication: AWMF